



DR. B. JOY JEFFRIES.

~~28. A. 402~~
~~28. A. 402~~

28. A. 402

LECTURES

ON

DISEASES OF THE EYE.

Dr. B. Joy Jeffries.

£5.75

LECTURES

ON

DISEASES OF THE EYE.

PART I.

REFERRING PRINCIPALLY TO THOSE AFFECTIONS
REQUIRING THE AID OF THE OPHTHALMOSCOPE FOR
THEIR DIAGNOSIS.

BY

N. C. MACNAMARA,

SURGEON TO THE CALCUTTA OPHTHALMIC HOSPITAL, PROFESSOR OF OPHTHALMIC
MEDICINE AND SURGERY, MEDICAL COLLEGE, CALCUTTA.

Read March 11/57



LONDON :

JOHN CHURCHILL AND SONS, NEW BURLINGTON STREET.

MDCCLXVI.

LONDON :
SAVILL AND EDWARDS, PRINTERS, CHANDOS STREET,
COVENT GARDEN.

P R E F A C E :

My object, in the first part of this work, has been to simplify as far as possible the science of Ophthalmoscopy, avoiding debatable points, and restricting my remarks to typical forms of disease; for if these are thoroughly comprehended, and the abnormal appearances they give rise to appreciated, the diagnosis of more complicated cases becomes comparatively easy. In my anxiety to avoid prolixity, I may have fallen into the opposite error of drawing too marked a line between the various abnormal appearances which may be noticed in the fundus of the eye. For instance, inflammation of the choroid frequently involves the retina, but to attempt to delineate all the complications thus produced would be an endless, and, I think, unprofitable task.

No doubt the pathology and treatment of those diseases which the ophthalmoscope reveals to us, have been greatly advanced during the last few years by the combined labours of many ophthalmic surgeons;

but it is not safe to overlook the fact, that men devoted to a special branch of surgery are apt to ride their hobby too hard, and frequently appear forgetful of the advantage and necessity of studying diseases of the eye as a branch of the Art of Medicine, and not as an independent, distinct science.

While the circumstances of many medical men in this country prevent them from becoming specialists, they impel them to render themselves familiar with at least the essentials of each branch of professional knowledge. For the medical officer placed in charge of a district, it may be as large as Wales or Scotland, is isolated from his fellows, and must depend upon his own resources in every case that comes before him; and I shall hardly be accused of partiality, if I say, that it is necessary for men so placed to become conversant with the ophthalmoscopic appearances of the healthy and diseased eye. It is perfectly true, that by far the majority of cases of disease of the eye which the practitioner is called on to treat, do not necessitate the use of the ophthalmoscope; but this is no more a valid objection to the study of ophthalmoscopy, than a similar one, which might be propounded against the value of the stethoscope, would be to the practice of auscultation.

The chromo-lithographs contained in this volume

require a few words of explanation and apology. Some few are reductions from the well-known plates of Jaeger and Liebreich, and of these I need say no more. The rest have no pretensions to be faithful portraits of disease, but diagrammatic illustrations, intended to assist the descriptions in the text; and which, though somewhat rude, and executed under great disadvantages, I hope may prove useful to those not already acquainted with the appearances they represent.

I am sorry I cannot always give references to the authors from whose writings I have gained much of the material contained in the following lectures. I have been in the habit of making notes from the various works I have read, without any idea of their being subsequently published; consequently I should have great difficulty in retracing my steps and discovering the sources from whence many of my ideas have been derived. I cannot, however, omit to mention how much I owe to my former teachers, the surgeons of the Moorfields Ophthalmic Hospital; to Mr. Carter for his translation of *Zander*, and to Mr. Soelberg Wells for his *Lectures on Glaucoma and Impaired Vision*. To Professors Von Graefe and Helmholtz, as also to other leading continental oculists, the science of ophthalmoscopy is vastly indebted, and to their works I would beg to refer all those interested in

the subject. Donders' invaluable researches on the *Accommodation and Refraction of the Eye* (lately translated for the New Sydenham Society by Dr. Moore) have furnished the material for my twelfth lecture. Lastly, I would strongly recommend those who take an interest in this subject to study *The Ophthalmic Review*, edited by Mr. J. Z. Laurence and Mr. Windsor; if this work is carried on as it has been begun, it will form a most valuable addition to every medical man's library.

28, CHOWRINGHEE.

June, 1866.

CONTENTS.

LECTURE I.

Introductory Remarks. Optical Principles of Ophthalmoscopy. Method of Illuminating and Observing the Deep Structures of the Eye. Choice of Instruments. Manner of Conducting an Examination pp. 1—21

LECTURE II.

Remarks on the Anatomy of the Eye. Mechanism of Accommodation. Ophthalmoscopic Appearance of the Fundus of the Eye in Health. Abnormal Conditions of the Optic Disc.
pp. 22—55

LECTURE III.

Cases Illustrating the Effects of Inherited Syphilis on the Structures of the Eye. Syphilitic Keratitis. Characteristic Conformation of the Teeth. Iritis. Opacity of the Vitreous and Lens.
pp. 56—75

LECTURE IV.

Syphilitic Opacity of the Vitreous. Fluid Condition of Vitreous. Opaque Floating Bodies. Muscæ Volitantes. Degenerations of the Vitreous from Poverty of the Blood. Hæmorrhage. Entozoa, and Foreign Bodies in the Vitreous Chamber.
pp. 76—92

LECTURE V.

Hyperæmia of the Retina. Transient and Chronic Forms. Cases depending on Mixed Causes. Malarial Cases. Treatment. Fatty Degeneration of the Retina. Acute Inflammation of the Retina pp. 93—117

LECTURE VI.

Retinitis, continued. Treatment of the Acute Form. Chronic Inflammation of the Retina. Accidents of Retinitis: Extravasations of Blood: Effusion of Lymph: Suppuration and Atrophy. Syphilitic Retinitis. Detachment of the Retina . pp. 118—139

LECTURE VII.

Congestion of the Vessels of the Retina from Mechanical Causes: Extra-orbital Pressure: Embolia: Melanæmia of the Retina. Removal of Hexagonal Cells of Elastic Lamina. Colloid Disease of Elastic Lamina pp. 140—161

LECTURE VIII.

Diseases of the Choroid. Hyperæmia. Choroiditis. Cases. Treatment by Iridectomy. Results of the Inflammatory Process; Exudations; Suppuration. Tubercular Deposits. Atrophy of the Choroid pp. 162—192

LECTURE IX.

Diseases of the Choroid resumed. Tiger-striped Retina. Sclerochoroiditis Posterior. Stationary and Progressive Forms. Results. Staphyloma of the Optic Disc . . . pp. 193—211

LECTURE X.

Mode of Registering the Tension of the Eye. Investigation of the Nature and Cause of Glaucoma. General History and Symptoms. Ophthalmoscopic Appearances. Treatment by Iridectomy. Details of the Operation. Iridectomy in other Affections pp. 212—233

LECTURE XI.

Cataract from Constitutional Syphilis. Use of the Ophthalmoscope in Cases of Cataract. Extraction of the Lens. Results of the Author's Experience in India. Advantages of Linear Extraction. Instruments. Management of Complications. pp. 234—248

LECTURE XII.

Disorders of Accommodation, Refraction, and Binocular Vision. Diplopia. Myopia. Hypermetropia. Presbyopia. Asthenopia—Motor, and Accommodatory. Astigmatism . pp. 249—282

LECTURES

ON

THE USE OF THE OPHTHALMOSCOPE.

LECTURE I.

Introductory Remarks. Optical Principles of Ophthalmoscopy. Method of Illuminating and Observing the Deep Structures of the Eye. Choice of Instruments. Manner of Conducting an Examination.

I PURPOSE in the following lectures to consider, first, the principle and method of using the ophthalmoscope, and next to notice those diseases of the eye which have within the last few years been elucidated by its means.

I need hardly remark, that it is impossible for me to give a description of ophthalmoscopy which can supply the place of clinical observation and experience; you may have the most perfect instrument in the world placed at your disposal, and possess a thorough knowledge of the laws of optics which govern its use, but unless you have worked at the subject in the ophthalmic wards, and made yourselves familiar with the appearances presented by the healthy eye, it is vain your expecting to be able to appre-

ciate the changes which go on under the influence of disease. It would be just as reasonable to suppose that a student, after reading through Watson's *Practice of Physic*, could diagnose a case of incipient phthisis, as it would be to imagine that he could recognise the changes induced by tubercular deposit in the choroid, without having previously made himself acquainted, by clinical study, with the appearance of the fundus of the eye in its normal condition, and of the alterations which may be effected in it by hyperæmia, exudation, and the like.

There are some persons, however, who appear to be incapable of appreciating the most palpable pathological changes in the interior of the eye, which are instantly perceived and correctly interpreted by others. This inability generally arises from an ignorance of the anatomy of the parts; but if it be owing to mental obtuseness, such persons may console themselves with the consideration, that careful and persevering study will usually surmount any natural deficiencies, and that students possessing mediocre talents often become in the long run the most distinguished men. I am led to make these remarks, because I have observed a disposition among a few of those attending my practice, to affect a degree of mistrust regarding the practical advantages to be derived from the ophthalmoscope, which, though indicating a lamentable amount of presumption and ignorance on their part, must be combated as far as possible by reasoning and demonstration. If any of you entertain false notions of this kind, I would ask you to persevere with the

study of ophthalmoscopy until you overcome the difficulties attending it, and I am certain you will be amply rewarded for the trouble.

There is no more beautiful and engrossing study than that which the ophthalmoscope affords; and for the student especially it has the charm of novelty to recommend it. It will be necessary, however, to work closely and methodically at the subject, in order that even its rudiments may be acquired during the three months you attend my wards, particularly as it is generally impracticable for more than one of you to examine a case after me: a prolonged use of the ophthalmoscope cannot be advantageous to a patient under any circumstances, and it is frequently most detrimental. At first sight, therefore, your opportunities of gaining a practical knowledge of this instrument may appear to be somewhat limited, but this disadvantage will be more than compensated by an ordinary amount of trouble bestowed upon such cases as you have the chance of investigating. The pathology, symptoms, and treatment of the disease should be minutely gone into, and all the information it is possible to gain concerning it carefully noted down at the time, and then the clinical history may be completed upon subsequent occasions. It is surprising how large an amount of knowledge may in this way be speedily acquired; in fact, the subject may thus be more advantageously studied than by hastily examining a much larger number of cases, and perhaps staring at half-a-dozen eyes every morning, without taking the trouble to inquire

into the nature of the disease from which the patients are suffering.

It has long been known, that in some classes of animals a red glare is reflected from the back of the eye; and as this phenomenon has generally been noticed when the animal is enraged, it was formerly supposed, that under these circumstances the creature had the power of causing his retina to become self-luminous. This idea, however, was refuted by an English surgeon of the name of Cumming, about twenty years ago.

In 1851, Helmholtz published a work on the ophthalmoscope, and laid the foundation of that study, which, by the combined labours of English and foreign oculists, is making such rapid strides, that it will require considerable attention on your part to keep pace with the work of the day.

One of the first questions likely to suggest itself to the mind of an inquiring person regarding the ophthalmoscope, is, the reason why we cannot see the retina of another individual without the use of an instrument of this kind.

In order to explain this, it will be convenient to refer to the annexed diagram (Fig. 1), in which A represents the eye of a patient accommodated to the distant point F, where the flame of a lamp is supposed to be situated. It is evident that some of the divergent rays, proceeding from the luminous body at F, will fall upon A's cornea, and being refracted by its dioptric media, they will meet at C on A's retina.

Some of these rays are absorbed, others are reflected by the structures of the fundus, and these, before emerging from the eye, must pass through precisely the same media as they did on entering it; and in consequence of their pursuing this path, they will be brought to a focus at the point from which they started, namely, at *F*. Unless an observer's eye, therefore, can be made to take the place of the luminous body at *F*, it is evident that none of the reflected light from *A*'s retina can possibly reach the observer's. *A*'s pupil, therefore, appears black to a person in the position *P*, or, in fact, at any other point than at *F*. If, however, a mirror with a hole in its centre, through which light can pass, be substituted for the lamp, and the rays reflected from its surface be directed into the eye *A*, the light returning from *A*'s retina can now enter the observer's eye, which, under these circumstances, may be made to occupy the position of the lamp, as represented in Fig. 1.

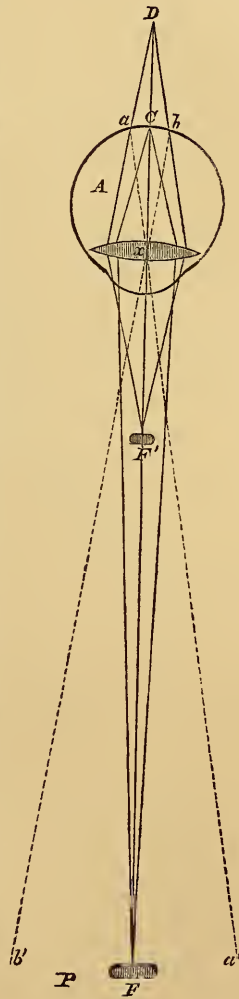


FIG. 1.

Again, suppose the luminous body is removed from the point *F* to *F'* (the patient's eye being still accom-

modated for the distance A F), the divergent rays proceeding from it, and being refracted by the dioptric media of A, would intersect at D, were they not intercepted by the fundus of the eye; as it is, they form a circle of light extending from a to b . But since the eye A is adjusted for the far point F, and not for F', it follows, that the rays reflected from any point in the circle $a b$, after emerging again from A, will be brought to a focus at the distance A F; and those from the extreme points a and b , will converge respectively to a' and b' , in lines prolonged from a and b through x the optical centre of A. Under these circumstances, an observer's eye at any point P will receive a few of the rays from A's retina, which will thus appear illuminated, even without the aid of a mirror.

If these considerations be applied to the ophthalmoscope, the principles upon which this instrument depends *as a means of illumination*, may be readily comprehended, it being essentially a mirror constructed so as to allow the observer's eye to take the place of the flame of the lamp, as represented in Fig. 2.

There are two distinct modes of examining an eye with the ophthalmoscope, known as the *direct* and the *indirect* methods. By the former, an erect geometrical image is perceived by the observer, and by the latter an inverted aerial image is produced.

By referring to Fig. 2, the direct method of examination may be readily understood.* A represents

* Throughout the following lecture, *Coccius's* ophthalmoscope is supposed to be the instrument employed in making observations, unless, as in some few cases, special reference is made to another form of ophthalmoscope. A description of this instrument will be found at p. 14.

the eye of the observer, and B that of the patient (both eyes being supposed emmetro-
pic),* F the source of light, from which a cone of rays $a b$ falls upon L, a double-convex lens interposed between F and the plain polished surface $c d$ of the ophthalmoscope S. By means of the lens L, the divergent rays of light from F are made to converge upon the mirror,† and after reflection from its surface, they proceed as if they came from $a' b'$ situated behind it, and converge towards some point p . A portion however of the rays, included between $g i$

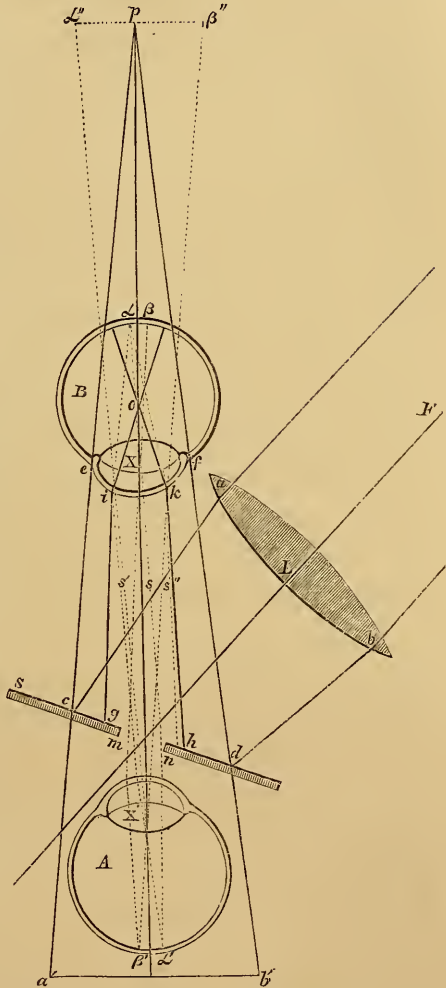


FIG. 2. (From Carter's translation of Zander.)

* An eye is said to be emmetro-
pic when a clear and distinct image
of an object is seen at ordinary visual distances.

† Which thus acts as a concave mirror in a position posterior to the
eye of the observer.

and $h k$, is intercepted by the dioptric media of B, and these, after refraction, intersect at O within the eye, from whence they again diverge to form a circle of light upon B's retina. If in this circle any two points a, β , be taken, the reflected rays from which pass through the sight-hole $m n$ of the ophthalmoscope, they will be brought to a focus at a' and β' on A's retina, and a virtual, erect, and magnified* image $a'' \beta''$ of $a \beta$ will be seen by the observer, apparently projected beyond the patient's eye.†

To obtain a clear view of the retina under these circumstances, it is necessary that the observer should advance the ophthalmoscope close to the eye under examination; the rays from the centre of the emergent cone of light will then form a well-defined image upon his retina; but if the ophthalmoscope be removed to about twelve or fourteen inches from the patient's eye, the outer rays of the cone will pass through the sight-hole of the instrument together with the central ones, and the vessels or any other spot on the retina will appear indistinct.

It is for this reason that the direct method of examination cannot, as a general rule, be employed for ordinary ophthalmoscopic purposes. The inconvenience, to say the least of it, of the surgeon being

* This magnifying of the image is so far a defect that it loses in brightness and definition as it gains in size, and therefore contrasts unfavourably with the bright, sharp, beautiful image which the indirect method displays.

† The mathematical demonstration of this fact may be studied by referring to Carter's translation of *Zander*, page 85.

obliged to keep his face within a few inches of that of his patient during a prolonged examination, is so considerable, as to render some modification of the plan very desirable. The difficulty may in a measure be overcome by the interposition of a concave lens between the eye of the patient and the ophthalmoscope, the effect of which is to render the light, after emerging from the eye, divergent, and the outer rays of the cone will then fall on the surface of the mirror, in place of passing through the sight-hole of the instrument.

The direct method of examination may be used with advantage as a test, to ascertain the existence of *myopia* or *hypermetropia*; and circumstances may frequently render it necessary for you to determine positively if either of these forms of disease exists in the case of malingerers.* Criminals sometimes feign to be suffering from impaired vision, and without the ophthalmoscope you may be unable to detect the fraud.

In the *myopic* eye, in consequence of the augmented refracting power which exists in the dioptric media, and which is in fact the cause of the disorder, the rays of light converge so rapidly after

* An eye is said to be *myopic* when the converging power of the dioptric media is greater than in the normal state, and in consequence the focal point of parallel rays is situated in front of the retina, divergent rays only being brought to a focus on the retina. *Hypermetropia* is the reverse of myopia, the parallel rays of light being brought to a focus behind the retina, convergent rays only being focused on the retina.

emerging from the cornea, that they cannot be brought to a focus on the observer's retina, so as to present a clear erect image, however near his eye be approximated to that of the patient; it is only when diverging, after intersection, that they are fitted to produce distinct vision, and then the image will be necessarily inverted. In a myopic eye, then, an erect image cannot be seen by the direct method of examination, unless a concave lens be interposed between the eye and the ophthalmoscope; but at a distance of some fourteen inches an inverted image will be distinctly visible without a lens. That the image is an inverted one, may be proved by the observer turning his head either to the right hand or the left, when the object under examination will appear to move in a precisely opposite direction.

If, therefore, on examining a person's eye by the direct method, a clear, enlarged, and inverted figure of the retina be seen at a distance of fourteen or fifteen inches from the eye, it may with safety be affirmed that the individual is myopic; and this diagnosis will be confirmed, if it be found impossible to see an erect image, however close the ophthalmoscope be brought to the patient's eye.

In a case of *hypermetropia*, in consequence of the low refractive power of the dioptric media, parallel or divergent rays entering the eye, would, if prolonged, converge to a point behind the retina; and conversely, rays reflected from any point in the retina, will, on emerging from the eye, proceed as if they came from a virtual image of the point situated behind it; and

being divergent they may be brought to a focus on the observer's retina, and form a distinct image, even at a distance of fourteen or fifteen inches. That this image is an erect one, may be ascertained from its moving in the same direction as the observer's eye; for instance, if the optic disc be the object under examination, and the observer turn his head to the right, the disc will follow to the right also. We may sum up these results as follows:—

If the direct method of examination be employed in the case of an *emmetropic* eye, an erect image of the retina may be clearly defined at a distance of three or four inches, but only a very imperfect one can be seen at fourteen or fifteen.

In the *myopic* eye, an erect image cannot be seen at all, but at about fourteen inches, a well-defined inverted figure may be observed.

In the *hypermetropic* eye, an erect image of the retina may be seen at a distance of fourteen or fifteen inches.*

We may now proceed to make a few observations in explanation of the *indirect* method of ophthalmoscopic examination.

The position of the patient, the lamp, and the ophthalmoscope should be the same as in the direct process, but in addition, it will be necessary to place a

* In this, and in all subsequent instances, it is supposed that the observer's eye is emmetropic, or that by means of suitable glasses both divergent and parallel rays of light are brought to a focus on his retina.

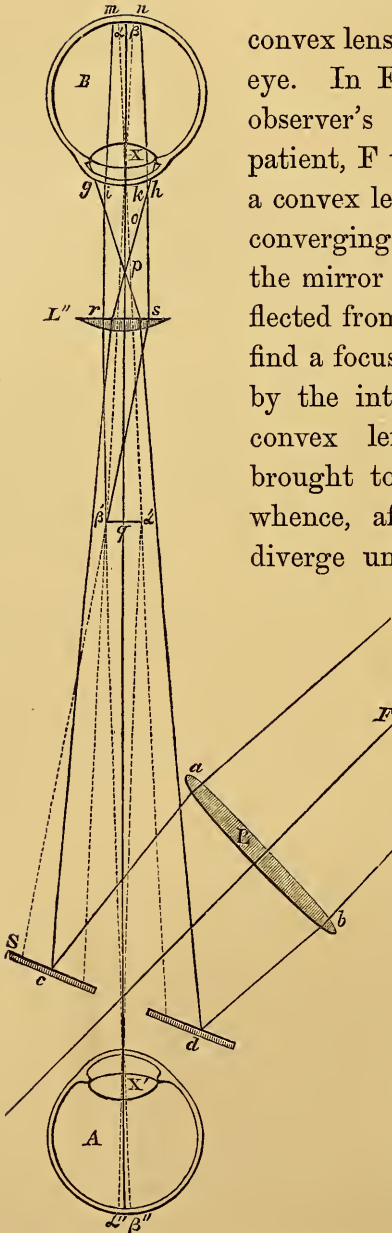


Fig. 3. (From Carter's translation of Zander.)

convex lens in front of the patient's eye. In Fig. 3, A represents the observer's eye, B that of the patient, F the source of light, L' a convex lens, by which a cone of converging rays is made to fall on the mirror S, and which, being reflected from its surface $c d$, would find a focus at some point o ; but by the interposition of a second convex lens L'', the rays are brought to an earlier focus at p , whence, after intersection, they diverge until intercepted by $g h$,

the cornea of B. A portion of this light, corresponding to the aperture of the pupil $i k$, enters the eye, and rendered slightly convergent by its dioptric media, proceeds to form a circle of light $m n$ on the retina. The rays returning from any two points a and β in this circle, will emerge parallel, or slightly convergent from B (according to its accommodation), and after refraction

by the lens L'' , will be united at a' and β' respectively, at the distance, approximately, from L'' of q its principal focus. A real, inverted, and magnified image $a' \beta'$, of $a \beta$, will thus be formed; and this will be distinctly visible by A at a distance of twelve or fourteen inches, the rays diverging from a' being brought to a focus on the retina at a'' , and those from β' at β'' .

The indirect method of examination is more generally applicable for ophthalmoscopic purposes than the direct, for the following reasons:—

1st.—A clear and distinct image of a vessel, or any other small object on the retina, may be seen at a distance of twelve or fourteen inches.

2nd.—Although the magnification is less, the field of view is larger, and a considerable portion of the fundus of the eye being visible at once, its several parts may be studied and compared in their relative positions at a glance.

3rd.—In brightness and clearness, the image seen by the indirect, greatly exceeds that observed by the direct process of examination.

With regard to the *best form of ophthalmoscope*, for ordinary purposes I prefer the one invented by Coccius, and as most of you have been in the habit of using this instrument in the ophthalmic wards, you had better continue to do so. It consists of a small metallic surface coated with silver; in its centre is a funnel-shaped hole about the one-sixteenth of an inch in diameter, and a plate of blackened metal is made to

slide upon the grooved edge of the mirror, by means of which the illuminating power of the instrument may be lessened if necessary. Attached to the slide is a clamp, into which a lens may be fitted, in order to concentrate the rays of light upon the mirror; or it may be turned behind the sight-hole of the ophthalmoscope. Various forms of lenses are supplied in the case, which may be used as object-glasses. This instrument is equally useful either for the direct or indirect methods of examination.

If you have been accustomed to use a Liebreich's small ophthalmoscope, it is not desirable to change it even for a "Coccius." The correctness of your diagnosis will much depend upon the accuracy of the comparison you are enabled to form between the diseased eye and a healthy one; and, if your standard of reference has been acquired by the use of a Liebreich's ophthalmoscope, it is not advisable to alter it. This instrument consists of a circular, concave, metallic mirror, of four-inch focal length, having in its centre a funnel-shaped sight-hole. Attached to the mirror is a clamp, by which one of the object-glasses, to be found in the instrument-case, may be fixed in front of the sight-hole. Convex lenses are also supplied, which are intended to be held before the patient's eye.

Within the last few years the binocular principle has been applied most successfully to ophthalmoscopy, and without entering upon a detailed description of the mechanism of this rather complicated instrument, I recommend those of you who can do so to procure one of Heath and Murray's binocular ophthalmo-

scopes. It is used in precisely the same way as the unioocular instrument, except, of course, that both the observer's eyes are employed at once, and during the examination the lamp is placed behind and above the head of the patient, instead of to one side of it.

The advantages of the binocular ophthalmoscope are, that it enables us at once to recognise the depth at which a deposit or effusion is situated, either in the retina or choroid; and also to distinguish elevations or depressions in these structures, arising from effusion or any other cause. Chronic changes of this kind are often difficult to define with the unioocular instrument, yet they may involve questions which it is a matter of the greatest importance to decide; and without doubt the binocular ophthalmoscope gives a more solid appearance to the parts, and an accuracy of definition which can hardly be otherwise gained.

Having made choice of an ophthalmoscope, our next inquiry must be as to the *source of light* most readily available, and best suited for ophthalmoscopic purposes.

I certainly prefer sunlight to that of a lamp. On account, however, of its excessive brilliancy, it is usually necessary to complete an examination as speedily as possible; but by practice this will soon cease to be a difficulty. The eye, by education, is enabled to make a very rapid survey of the parts, and if not satisfied with the impression thus gained, it is easy to complete the examination with artificial light. The intensity of the sun's rays may be lessened by inter-

posing a plate of smoked glass in front of the ophthalmoscope, or a blue lens held before the patient's eye will moderate the glare.

The advantages of sunlight are so great, that it should always be used if practicable; the colour of the fundus of the eye is more accurately seen, and the character of abnormal changes determined with greater precision, than if artificial light be employed. If, however, you prefer the latter, a kerosine lamp gives a remarkably good light; the flame is steady, white, and clear, and the wick seldom requires to be trimmed; in fact, all the care necessary in the management of a lamp of this kind is to keep the reservoir full of kerosine.

It is not always advisable to *dilate the pupil* with atropine before making an ophthalmoscopic examination; a general idea of the fundus of the eye may be gained without the use of any mydriatic. The patient should be desired to look attentively at a mark on the opposite wall of the room, so that his eye may be accommodated for a distant point; if now he close one eye, the pupil of the other will dilate sufficiently to allow of an ophthalmoscopic examination. Should it be found necessary to make a more perfect observation, a solution of atropine must be applied to the eye, of a strength not exceeding one grain to an ounce of water. A patient is often put to considerable inconvenience if a more powerful mydriatic be used, the pupil taking several days to contract; and to a man engaged in business, this is a matter of consideration, for so long as the effects of the atropine remain, he

will experience considerable difficulty in reading and writing. In practice it will be found that the ophthalmoscope is more often required in slight cases of impaired vision than in confirmed instances of total blindness.

I may observe in passing, that except in cases where one eye only is diseased, and the abnormal conditions are clearly and unmistakeably apparent, a prognosis should not be ventured on until both eyes have been examined, the state of the one being carefully compared with that of the other. Nothing is so likely to damage your reputation, or to shake the confidence of your patients in your judgment and skill, as giving a hasty or ill-considered opinion, which on a subsequent examination it may be found necessary to alter. It will be generally advisable to write down the appearances presented by the eye in a note-book, with which to refresh your memory, and enable you to form an idea of the progress of the disease, if at any subsequent period the patient present himself for inspection.

With regard to the *arrangement of the room* in which an examination is to be made, if artificial light be employed, the apartment cannot be too dark ; but, on the other hand, it is not absolutely necessary to shut out the light entirely, in order to make a satisfactory observation ; simply closing the gilmils and glass doors will be sufficient for all practical purposes. Should sunlight be preferred, the most convenient plan to adopt, is to send a servant out into the sun with a mirror, from which the rays of light can be

reflected through an open door or window into the room. The patient should be seated with his back to the window, and the observer opposite to it, so that the reflected light from the mirror may be thrown upon his face. He then closes one eye, and applying the ophthalmoscope to the other, the rays of light are received upon its polished surface, and directed into the patient's eye.

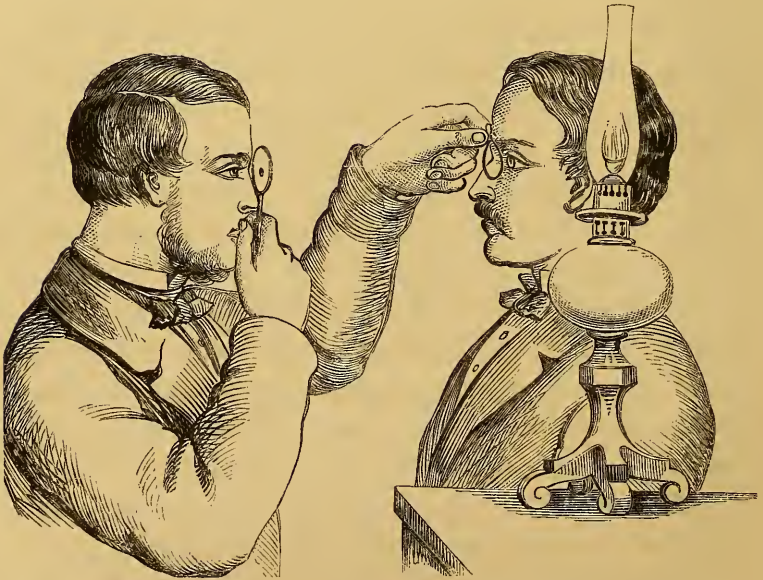


FIG. 4.

The arrangement of the lamp, the patient, and the observer, when artificial light is employed, is shown in Fig. 4. It will be noticed that the eye of the surgeon, that of the patient, and the source of light are upon the same level, the lamp being placed close to the ear of the latter. An as-

sistant should stand behind the observer holding a large white card, or some such conspicuous object, in his hand, upon which the patient is directed to fix the eye under examination. For the right eye, the card must be held over the observer's right shoulder, and for the left one, over the left. By this means the patient's eye is inclined slightly inwards, and the rays of light from the ophthalmoscope will fall directly upon the optic disc. In the case of a blind man, no arrangement of this kind can be made, and it frequently involves a great trial of patience and ingenuity, to get such a person to hold his eye steady, even for a few seconds, in the direction required. It is absolutely necessary however, under any circumstances, that the patient should keep his head erect, and directly opposite the observer's; unless this be insisted on, it is impossible to make a satisfactory examination. In using the ophthalmoscope, the sight-hole of the instrument should be applied to whichever of the observer's eyes is most convenient to himself, its rim being made to rest against his eyebrow, and as he turns his head, the instrument will move with it. The lens in front of the patient's eye should be held between the thumb and fore-finger of the other hand, the index and middle finger resting against his forehead, which thus acts as a fixed point, enabling the observer to approximate or withdraw the lens, so as to bring the retina into focus with the greatest precision, and also to follow the movements of the eye under examination.

The beginner may be troubled by the reflection of

the ophthalmoscope from the cornea of the patient. It appears as a brilliant image of the mirror on the surface of the cornea, hiding that part of the retina which is behind it. It is easy to get rid of this reflection by slightly rotating the object lens to one side or the other, when it will disappear, and the retina be clearly seen.

The student, before undertaking the examination of the human eye with the ophthalmoscope, should test the instrument, and his power of using it. For this purpose let him make a few scratches on the wall, and seating himself opposite them, hold the convex lens in front of the marks; then, applying the ophthalmoscope to his eye, with the object glass fixed before the sight-hole, he should endeavour to determine which lens best defines the particles of lime. There are always a set of glasses supplied with the instrument, and they may be tried in this way one after the other; probably a No. 10, convex lens, will suit the eye of most emmetropic observers.

Before concluding this lecture I must make a few remarks on the *lateral method of illumination*. For this purpose the observer and patient are seated opposite one another, and the lamp is placed in advance, and to one side of the latter, in order that its rays may be concentrated upon the eye under examination by a convex lens, as shown in Fig. 5. The eye being illuminated in this way, the observer can magnify any part of the lens, iris, or cornea with a convex glass held in front of the eye.

By this means valuable aid is afforded the surgeon, especially in detecting foreign bodies in the anterior chamber, or in cases of synechia and occlusion of the pupil from false membrane. Nebulæ also, which it is difficult to appreciate with the unaided eye, may thus be distinctly defined. In fact, abnormal changes

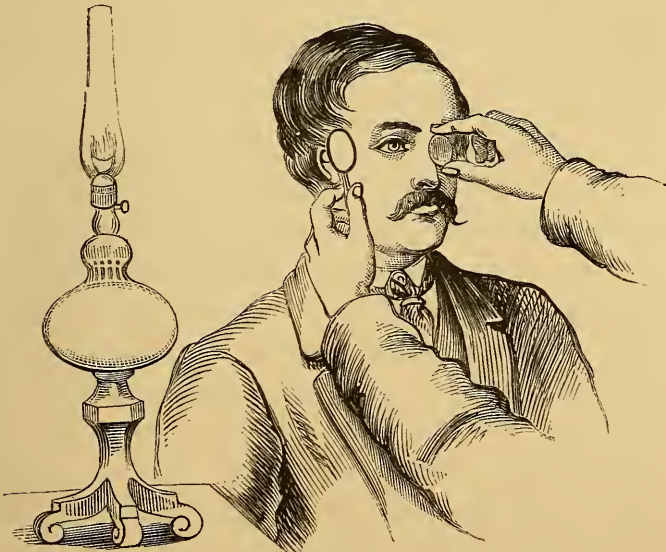

FIG. 5.

going on in the lens and the structures anterior to it, are most advantageously studied by the lateral method of illumination. Sunlight can be employed in this way, but as a general rule, a brilliant light is not necessary or advantageous when the cornea, iris, or lens are under observation.

LECTURE II.

*Remarks on the Anatomy of the Eye. Mechanism of Accommodation.
Ophthalmoscopic Appearance of the Fundus of the Eye in Health.
Abnormal Conditions of the Optic Disc.*

BEFORE continuing the subject of these lectures, it will be advisable for me to call your attention to some of the more important points connected with the *anatomy of the organ of vision*; for unless you thoroughly understand the relation of the various parts of the eye to one another, it will be impossible for you to follow me in my subsequent remarks on the diseases of the choroid, retina, or dioptric media. I will therefore proceed at once to give as concise a sketch as I can, of the structure and relative position of the different parts of the eye.

And first, as regards the *conjunctiva*; this belongs to the group of mucous membranes, and is composed of an external epithelial layer resting on a basement membrane, beneath which the capillary vessels are situated. The palpebral conjunctiva is extremely vascular, and is elevated into numerous papillæ, each of which encloses one or more capillary loops with their accompanying nervous apparatus, the whole being incased in connective tissue, which also includes a number of small glandular bodies much resembling

the solitary glands of the intestine. Besides these, there are a row of some eighteen glands situated in the fold of tarsal and orbital conjunctiva; they open by as many ducts on the free surface of the mucous membrane, and pour out an abundant secretion, which lubricates the surface of the eye.

The conjunctiva is continuous with the mucous membrane lining the lachrymal apparatus, and is reflected from the tarsi over the front of the eye-ball, in which situation it is void of papillæ, and is bound down to the sclerotic by loose fibro-cellular tissue. It is supplied with a superficial and deep set of vessels, the former being derived from branches of the palpebral and lachrymal arteries, and the latter from the muscular and ciliary; these anastomose with one another, forming a zone of vessels round the circumference of the cornea, and some of the branches of the deeper layer penetrate the sclerotic and anastomose with the vessels supplying the iris and choroid. The veins empty themselves into the cavernous sinus through the muscular and angular veins, and also by the nasal arch; so that if from any cause the passage of blood through the vasa vorticosa of the choroid into the ophthalmic vein is obstructed, a collateral circulation is established through the superficial veins of the conjunctiva; hence the enlarged and tortuous vessels noticed in glaucoma and such like diseases, attended with increased intra-ocular pressure. The conjunctiva, minus its blood-vessels, is continued over the cornea, constituting its anterior layer.

If the *eye-ball* be carefully separated from the

surrounding tissues, it will be found to be nearly spherical; its anterior part or cornea, however, being the segment of a smaller sphere, is more convex than any other part of the eye-ball. In size it varies very much in different individuals, its mean diameter being about seven-eighths of an inch. These measurements, however, are matters of far less practical importance than its degree of *tension*; I cannot too strongly impress upon you the advantage to be derived from a correct appreciation of the normal tension of the eye, enabling you to detect any alterations in this respect in diseased conditions of the organ.

The *sclerotic* is a dense, fibrous case, modified in front to admit of the passage of light to the retina; the optic nerve, and the ciliary vessels and nerves pierce it from behind; it is thickest at the back of the eye, where it corresponds to the situation of the retina, and it becomes gradually thinner anteriorly, until within a short distance of the cornea, when it again increases in thickness; it is weakest close behind the insertion of the recti and oblique muscles, and it is here that anterior staphyloma is most apt to occur.

The *optic nerve* passes through the sclerotic, together with the retinal vessels, at about the one-tenth of an inch internal to the axis of the eye. This opening is funnel-shaped, being smaller towards the inner than the outer surface, and like a sieve, it is crossed in all directions by numerous bands of fibrous tissue which constitute the *lamina cribrosa*; in fact, it would be more correct to say, that the sclerotic is pierced by a number of small openings, to allow the passage of the

nerve into the eye, than to describe it as though a piece were punched out at this spot.

The optic nerve before entering the eye is incased in a dense *fibrous sheath*, which on reaching the sclerotic becomes fused into its structure, thus strengthening it posteriorly; and, in addition to this, the fibres of the lamina cribrosa are augmented in bulk by the addition of the neurilemma of the nerve, which is not prolonged into the eye, but quitting the axis fibre of the nerve, passes into the fibrous bundles of the lamina cribrosa. It is evident, therefore, that although the sclerotic is perforated for the admission of the nerve into the eye, still the apparent weakness in the part which is thus caused, is amply compensated by the additional support it receives from the fusion of the sheath of the nerve and the neurilemma into its fibrous structure.

Donders describes the nerve-sheath as dividing into two portions close to the eye, the larger part of it passing outward and becoming fused into the sclerotic, the other portion incasing the nerve right up to the lamina cribrosa, which it strengthens, as well as the sclerotic, at this point. The triangular space between these layers is filled with connective tissue, and it contains also a ring of vessels passing round the optic nerve. Donders considers that it is the inner of these layers bulging backwards, that gives rise to the depression seen round the margin of the papilla in staphyloma posticum.

The *cornea* is a modification of the sclerotic, so constructed that it may receive its nourishment through a series of intercellular spaces, preventing the neces-

sity for a vascular system pervading its structure, the presence of which would, of course, interfere with its transparency. The circumference of the cornea is bevelled off in such a manner that the sclerotic overlaps it; but with this exception, it is of the same thickness throughout, and may be conveniently described as consisting of three layers. The foremost, or *conjunctival lamina*, is a fibrous membrane, its anterior surface being covered by several layers of epithelial cells; posteriorly it sends processes inwards, interlacing with the fibrous elements of the lamina beneath it. The *middle layer* constitutes the principal bulk of the cornea, and consists of fibro-cellular tissue, the cells sending out processes in all directions, which anastomose with one another, forming a free cellular intercommunication. The cells contain each a nucleus and nucleolus, and are imbedded in a fibrous matrix, which appears to run in strata, superimposed one over the other. Branches of the long ciliary nerves may be traced into the cornea, where they appear to form a very abundant and intricate network.

The *internal lamina* of the cornea is composed of an homogeneous membrane, and is lined internally, that is towards the aqueous humour, by a layer of epithelial cells; it is about the $\frac{1}{2500}$ of an inch thick. Bowman describes it as being "a transparent homogeneous membrane, considerably thinner than the anterior elastic lamina (from $\frac{1}{2000}$ to $\frac{1}{3000}$ of an inch thick), but like it, not affected by maceration, by boiling, or by the action of acids. Though very hard and capable of resisting much pressure, giving a crisp sound when

divided by the scissors, yet it is very brittle and easily torn ; its fragments showing a remarkable tendency to curl up on all sides into rolls.”

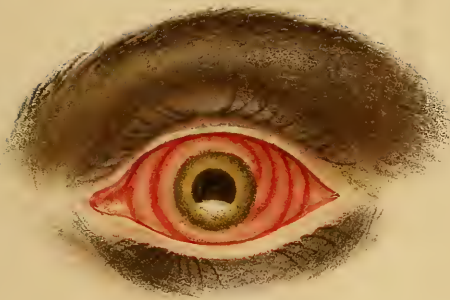The fibrous structures of the middle and internal laminæ unite at the circumference of the cornea, and give rise to two sets of fibres ; the internal, passing backwards to the ciliary processes, form a point of attachment for the ciliary muscle, and the external, bending forwards in an arched manner, and uniting with those of the sclerotic, leave a small space or canal between them and the sclerotic, called the *circular sinus*.

The bulk of the posterior homogeneous layer of the cornea, however, is continued backwards to the iris, a part of it passing into its structure, and the remainder forming a delicate membrane over the ciliary processes and choroid, which is inserted into the margin of the lamina cribrosa, and which I propose to describe as the *elastic lamina of the ciliary processes and choroid*. Internally, it is lined throughout by epithelial cells, which, in the native of India, are filled with black pigment from the iris backwards. Over the choroid they are known as the hexagonal cells of the choroid, and until they are removed, that structure cannot be seen from the vitreous chamber.

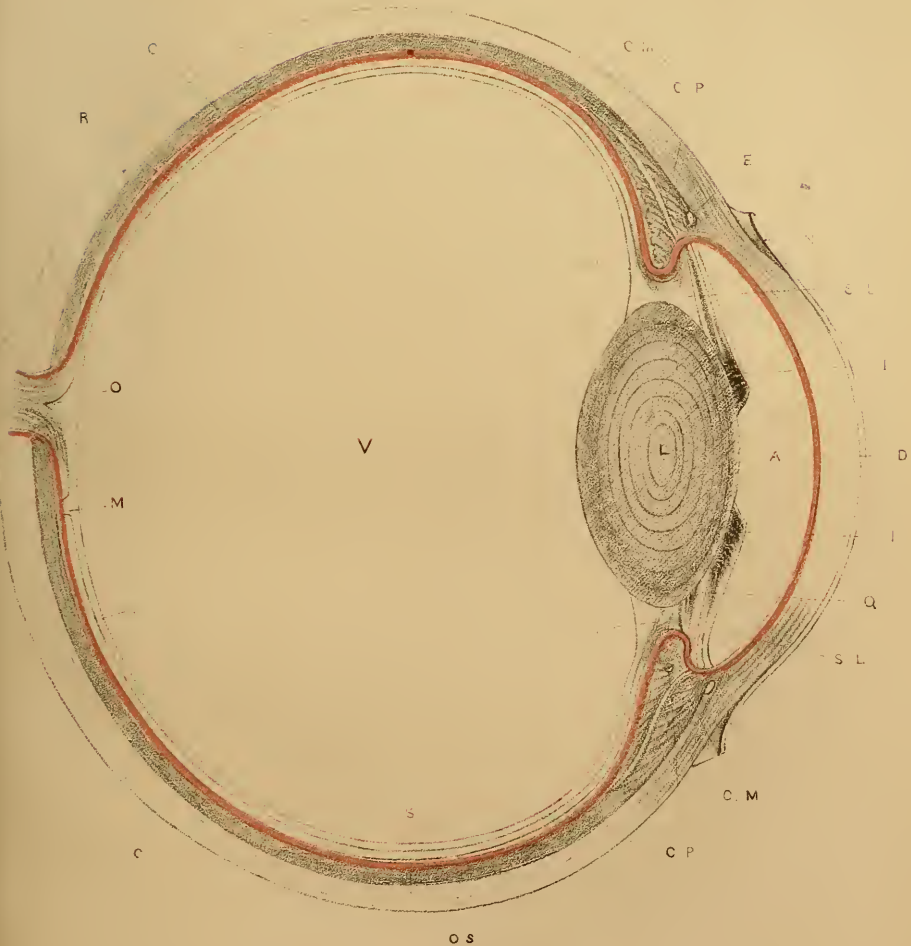
In Plate I. Fig. 2, which represents a magnified section of an eye, and is intended to render the connexions of these various parts more intelligible, I have drawn a red line to indicate the course and relations of the elastic lamina. You will notice that between it and the sclerotic, the choroid, ciliary processes, and muscle, are situated ; internally it is lined throughout

by epithelial cells, which are in proximity posteriorly with the retina, and in front of the ora serrata, with the suspensory ligament of the lens and the aqueous humour. The other structures exhibited in the section are.—S. The sclerotic, prolonged in front into, D. The cornea. N. The epithelial layer of cornea. C. The choroid, continued anteriorly into, C. P. The ciliary processes. I. The iris. C. M. Ciliary muscle. E. Circular canal. R. Retina. M. Yellow spot. O. Optic disc. S. L. Suspensory ligament of lens. H. Hyaloid. P. Canal of Petit. V. Vitreous. Q. Posterior chamber. A. Anterior chamber. L. Lens. O. S. Situation of the ora serrata.

The *choroid* is essentially a vascular structure, intended, no doubt, through its numerous vessels, to act as a reservoir of blood for the nourishment of the vitreous and lens; it is prolonged anteriorly into the ciliary processes. Externally, the membrane is in contact with the sclerotic and ciliary muscle, and internally with the elastic lamina; the two being united by bands of connective tissue, in the meshes of which are situated the vessels, nerves, muscular tissue, and pigment cells of the choroid. These latter consist of numerous large branching cells, and in the native of India are full of deep brown or black pigment; the processes given off in all directions from these cells anastomose with one another. The innermost layer, however, of the cells of the choroid, that is, those nearest the elastic lamina, are devoid of colouring matter, and are very much smaller than the pigment cells. The choroid contains a considerable quantity



2



Horizontal section of the eye. Red lines intended to shew the course of the elastic lamina lined with black pigment.

of muscular fibre, prolonged, I believe, from the ciliary muscle ; its nerves are derived from the short ciliary branches of the ophthalmic ganglion.

The *vessels of the choroid*, including the ciliary processes, have been divided into several layers ; I will not, however, detain you with a minute account of their anatomy, but simply remark, that the arteries are derived from the posterior ciliary divisions of the ophthalmic artery, which, piercing the sclerotic near the lamina cribrosa, divide into numerous branches. These are all directed forwards towards the ora serrata, following a somewhat meandering course among the pigment cells of the choroid. They give rise to a dense capillary network internal to themselves, and situated immediately behind the elastic lamina ; consequently the larger vessels are nearer the sclerotic than their capillaries, and are surrounded by the pigment cells of the choroid, whereas the latter for the most part are internal to the pigment cells.

In consequence of this arrangement, in capillary congestion, the larger branches, and the pigment cells of the choroid, will be almost concealed from view, when examined with the ophthalmoscope, by a red film or haze caused by the congested capillaries ; but if the hyperæmia is confined to the larger vessels, these will be clearly seen surrounded by the black groundwork of the choroidal pigment cells. The capillaries, from their minute size, cannot be distinguished as separate vessels by any ordinary power used in examinations of this kind. So long, however, as the hexagonal cells of the elastic lamina remain *in situ*,

it is impossible to see any of the choroidal vessels at all.

Some of the branches of the short ciliary arteries pass forward through the ciliary muscle, and enter the iris. The veins of the choroid (*vasa vorticosa*) converge from all directions into four large branches, which perforate the sclerotic midway between the optic nerve and the cornea, and ultimately empty themselves into the cavernous sinus.

Beyond the ora serrata the inner surface of the choroid appears striated, and anteriorly the striæ become deeper, forming the *ciliary processes*, which pass forward, so as to overlap, but not actually touch the edge of the lens; these processes, amounting to about sixty in number, are received into as many folds of the vitreous body; they are lined internally by the elastic lamina. The structure of the ciliary processes is similar to that of the choroid, but anteriorly the vessels bend round upon themselves, each process forming, as it were, a club-shaped mass of vessels imbedded in fibro-cellular tissue and pigment cells; externally they are in contact with the ciliary muscle. The free ends of the ciliary processes lie immediately behind the iris; if, therefore, the iris be torn away from its attachment, it is apt to break off a portion of the elastic lamina, which you will remember I stated was continued into the iris, and also formed a part of its external attachment; in this way a communication is established between the space behind the elastic lamina and the anterior chamber of the eye.

The *iris*, as has been already stated, arises from the

fibres proceeding from the margin of the inner lamina of the cornea, some of which may be traced into it. A second set, arising from the margin of the cornea, were mentioned as passing posteriorly to the ciliary processes; some of these, too, may be traced into the iris; they also separate the circumference of the iris from the ciliary muscle. In addition to this fibrous structure, the iris contains a longitudinal and circular set of muscular fibres, connective tissue, pigment cells, vessels and nerves. Its anterior surface is free and bathed by the aqueous humour; its posterior surface rest against the lens, and its inner margin forms the circumference of the pupil. It contains a vast number of pigment cells; those on its posterior surface being directly continuous with the epithelium covering the elastic lamina of the ciliary processes.

The muscular fibres of the iris are of the unstriped variety, and may be divided into two sets; the outer, or radiating, which are described as running in fasciculi from without inwards, forming the dilatator pupillæ, and the internal circular fibres, which constitute the constrictor pupillæ.

The vessels of the iris pursue a similar course; they are of small size, and are derived from the long ciliary arteries, which perforate the sclerotic posteriorly; they pass along in the ciliary muscle till they reach the outer margin of the iris, when they divide and form a zone round its outer border, sending off branches to it and also to the ciliary muscle.

The nerves are supplied by the long ciliary branches of the nasal nerve, and also by the sympathetic;

these uniting form a plexus round the outer margin of the iris, and from thence send off branches to supply the dilator and constrictor muscles. The contraction of the pupil in obedience to the stimulus of light, is evidently a reflex action depending upon excitation of the retina; but the iris also acts in obedience to the will, as for instance in accommodation, which is doubtless a voluntary process. It is through the action of the motor nerve, that the circular muscle of the iris contracts, for when this nerve is destroyed the pupil remains dilated. Division of the sympathetic in the neck is followed by contraction of the pupil, whereas its irritation causes the pupil to dilate. Donders remarks, that its action causes "a persistent exaltation of the tone of the radiating fibres. Thus the dilatator pupillæ is with constant force the antagonist of the sphincter muscle."*

The fifth is the sentient nerve of the iris; its motor action can only be explained by supposing that, when irritated, reflex action takes place from the Gasserian ganglion, for its influence in causing contraction of the pupil continues after division of the oculo-motor and the sympathetic nerves.†

The *retina*, as you are aware, is essentially a nervous structure, spread out over the inner surface of the back of the eye. I do not propose entering upon a description of its minute anatomy, but shall simply state

* *Vide* Donders on Accommodation and Refraction, published by the New Sydenham Society, page 579.

† *Id.* p. 581.

its relations to the parts around it. It extends from the optic disc forwards as far as the ora serrata, its posterior surface being in contact with the hexagonal cells of the elastic lamina covering the choroid; internally it is separated from the hyaloid by the membrana limitans.

The vessels of the retina are derived from the *arteria centralis retinae*, which enters the eye through the centre of the lamina cribrosa, and passing through the optic disc, sends out branches in all directions; these vessels are at first situated immediately beneath the membrana limitans, but ultimately they dip down into the nervous elements of the retina, terminating in a system of delicate, and by no means numerous capillaries. The veins commence in a circle round the ora serrata, and converging from thence, end in the *vena centralis retinae*, which passes out of the eye through the centre of the optic disc.

A deeply tinted yellow spot, called the *macula lutea*, will be observed in the retina, situated exactly in the axis of vision; it is therefore about the one-tenth of an inch to the outer side of the entrance of the optic nerve (optic disc); in its centre will be seen a small depression, the fovea centralis. The retinal vessels will be noticed curving above and under this spot in an arched manner, but they do not cross it.

The elastic lamina bends over the edge of the choroid at the *optic disc*, and is inserted into the margin of the latter; so that when the retina is removed the disc appears, under a one-inch power, like a shallow cup, its rim being formed by the elastic

lamina dipping down and being attached to its circumference, while the fibrous bands of the lamina cribrosa form the bottom of the cup, the intervals between them being filled with the nervous elements of the optic nerve. In the centre of the papilla, the remains of the retinal vessels will be noticed.

If the part be examined with the retina *in situ*, it is evident that the hollow above described will be filled up by the nervous structures, which, passing through the lamina cribrosa and advancing forwards, bend over the choroidal rim to form the retina proper. The vessels will then be seen entering the eye through the centre of the disc, and branching out in all directions over the retina.

The difference, therefore, in the colour of the optic disc and the remainder of the fundus of the eye, when examined with the ophthalmoscope, will be very evident: the white, glistening, fibrous structure of the sclerotic reflects the rays of light back to the observer from the optic disc, but beyond that spot, they fall, in the eye of the native, upon the black, hexagonal, pigment-cells covering the elastic lamina, and are mostly absorbed. The retina itself being almost transparent, the amount of light reflected from its surface is comparatively small, yet sufficient to produce the greyish-brown reflection which is seen in the healthy eye of the native. The nervous structure of the optic disc is abundantly supplied with capillary vessels; the reflected light from its surface therefore is of a pink colour, and not quite white, except in certain

forms of disease in which the capillary circulation is destroyed or impeded.

The *suspensory ligament of the lens* (zonula of Zinn) is a fibro-cellular structure internal to the epithelium of the elastic lamina, and passing forwards from the ora serrata and along the ciliary processes, it dips down over the margin of the lens, and is incorporated with the anterior surface of its capsule. In leaving the ciliary body to pass to the lens, it forms the anterior wall of the canal of Petit, to be presently noticed.

The *hyaloid* constitutes the membranous bag in which the vitreous is contained ; it is a most delicate and fragile structure, and is in immediate contact with the membrana limitans as far as the ora serrata. Anteriorly to this it is in apposition with the suspensory ligament of the lens, until, advancing close up to the margin of the lens, it dips down behind it, so that the edge of the lens is contained in a canal, first described by Petit, which is formed by the suspensory ligament in front and by the hyaloid behind.

Crossing the interior of this closed sac (the hyaloid), are a number of very fine fibro-cellular bands, the spaces between which are filled with a transparent viscid fluid, containing cells like those of mucus ; this is known as the vitreous humour. I am aware that the hyaloid is generally described as containing no fibrous structure within its cavity ; but I have seen these bands in very recent specimens, and feel no doubt in my own mind that they do exist, though they may become broken down and folded up against

the internal surface of the hyaloid, unless the greatest care be taken in the manipulation when looking for them.

The *lens* is a transparent double-convex body, about the sixth of an inch thick, and more convex in front than behind; it is composed of a numerous series of fibres of peculiar form and albuminous composition, united so as to form plates or laminæ, having a very complex and beautiful arrangement;* it is contained in an elastic homogeneous capsule, lined internally by a layer of cells. The lens with its capsule may be said to rest posteriorly in the anterior part of the vitreous, and in front it is attached by the suspensory ligament to the ciliary processes, and is in contact with the posterior surface of the iris and aqueous humour.

The last structure I have to notice is the *ciliary muscle*, and if you have followed me carefully throughout the foregoing description of the relative position of these parts, you will readily understand its connexions, and the important functions it must perform in the process of accommodation.

The ciliary muscle arises from the point of junction of the cornea and sclerotic, and passes backwards beneath the sclerotic as far as the ora serrata; it is attached to the layer of fibres before alluded to, as being composed of the posterior portion of the middle layer of the cornea. Externally, throughout its course, it is in immediate contact with the sclerotic, and internally

* *Vide* Bowman, Lectures on the Eye, p. 65.

with the above-noticed corneal fibres ; and these, together with the fibres from the posterior layer of the cornea, separate it from the aqueous chamber and iris. Posteriorly, it is in contact with the ciliary processes and choroid ; its fibres may be traced into these structures, and are arranged in a longitudinal and circular manner ; the former run from before backwards, many of them forming loops and bending round over the circular fibres. The exact purpose of this disposition of the fibres of the ciliary muscle is not at present understood. The source of its vessels is the same as of those of the iris. Its nerves are derived from the ciliary, naso-ciliary (a nerve of sensation), and also from the sympathetic ; these unite and form an abundant plexus in the muscle ; it is also supplied with ganglionic cells.

The *mechanism of accommodation*, that is, the means by which the eye adapts itself to the perception of objects both near and far off without an effort, or of bringing the rays of light from objects at different distances to a focus on the retina, has been a matter of dispute for years past, and the point at issue can hardly be said to be even now settled. Of one thing, however, we may be sure, and that is, that the lens does not alter its position in the eye, as was formerly supposed ; it doubtless changes its shape, but certainly does not move backwards and forwards in the posterior chamber. The most satisfactory description I have yet read, of the changes which take place in the eye during the process of accommodation, is to be found

in an abstract by Mr. Windsor of Dr. Becker's paper on that subject (Ophth. Hosp. Reports, vol. iv. part 3, p. 310); he says:—

“The eye is at rest when adapted for its most distant point of distinct vision, *i.e.*, no internal muscle of the eye is contracted. The ciliary muscle is at perfect rest, and the muscles of the iris are in a state of equilibrium, which depends on the (varying) tonic excitement of both muscles.

“In accommodating the eye for a nearer point, the whole ciliary muscle and the sphincter pupillæ contract at the same time (possibly also the dilatator pupillæ); inversely, in accommodating the eye for a more distant point, the ciliary muscle relaxes or becomes entirely flaccid, the dilatator pupillæ contracts, and the sphincter relaxes (or the latter alone becomes flaccid, and yields to the already contracted dilatator).

“Contraction of the ciliary muscle draws its anterior and outer end, and the periphery of the iris with which it is connected, backwards and inwards, its posterior and outer end and the adjacent parts of the choroid and retina forwards; the inner angle of the muscle (for its section is triangular) passes inwards, *i.e.*, it comes nearer to the optic axis. At the same time that the periphery of the iris is drawn inwards and backwards, its pupillary portion passes forwards, and the ciliary processes, diminishing in length and thickness, recede towards the ciliary body. In company with these changes in the ciliary body and iris, others occur in the lens; its anterior surface becomes more curved and approaches the cornea, whilst

its posterior surface scarcely changes in position or form, thus rendering its axis (the diameter in the direction of the visual line) longer, its diameter in the equatorial plane shorter.

“There are reasons for believing that this change of the lens is effected through relaxation of the zonula Zinnii,* by means of the contracting ciliary muscle, for its posterior angle passes forwards and its inner angle inwards. The lens, which had been previously flattened by the traction outwards which is exerted by the tense zonula on its periphery, now tends to a state of rest, in proportion to the relaxation of the zonula.

“When the contraction of the ciliary muscle ceases, its inner angle passes outwards, its posterior backwards, the zonula again becomes tense, its traction on the lens increases, the lens becomes flatter, the periphery of the iris passes forwards, its pupillary portion and the anterior surface of the lens move backwards, the ciliary processes enlarge and press forwards and inwards between the lens and iris into the posterior chamber.

“The motions of the ciliary muscle and iris are associated and occur in co-operation, yet the iris has no direct influence over the alterations in the form of the lens: they occur when the iris is absent. On the contrary, the movements of the ciliary processes depend on the action of the iris and the contractions of the ciliary muscle; the processes do

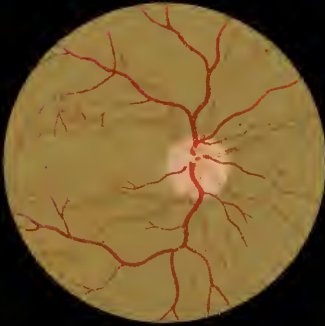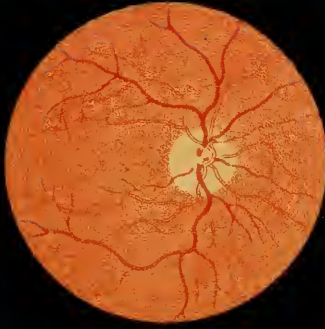* Suspensory ligament of the lens.

not change their form or position when the iris is absent.”

I will now proceed to describe the *Ophthalmoscopic appearances* which are presented by *the healthy eye*.

And in the first place I must draw your attention to the fact, that the *colour* of its interior in the natives of India is quite different from that of Europeans; Fig. 1, Plate II., and Fig. 2, Plate III., being drawings of the latter, and Fig. 2, Plate II., and Fig. 1, Plate III., of the former. This arises from the deep brown or black pigment which fills the hexagonal cells of the elastic lamina in the native, and entirely obscures the choroid, so that the fundus of the eye appears of a *brownish-grey* colour; whereas in the European, the incident light being reflected principally from the vascular network of the choroid, it is of a *crimson orange* hue.

The precise tint must of course vary in each individual, depending upon the depth of colour of the pigment contained in the hexagonal and choroidal cells; for instance, the inhabitant of Bengal being comparatively fair, the fundus of the eye, when examined with the ophthalmoscope, appears of a grey colour, whereas in the darker-skinned native of the South of India it will be almost black. And so also with the European; in the light-haired Saxon, the fundus is of a bright-scarlet colour, and in consequence of the almost entire absence of pigment in the part, the larger vessels of the choroid will be clearly seen; but in the black-eyed people of Spain and Italy the colour of the fundus will be proportionately darker,





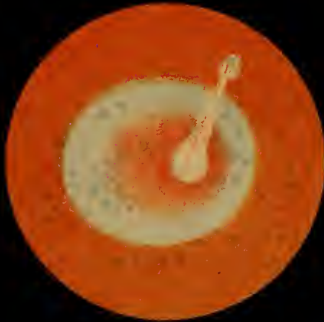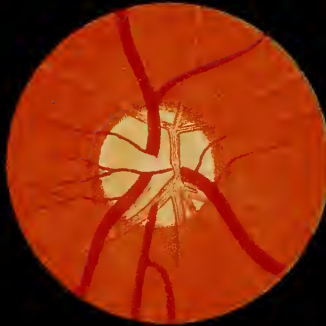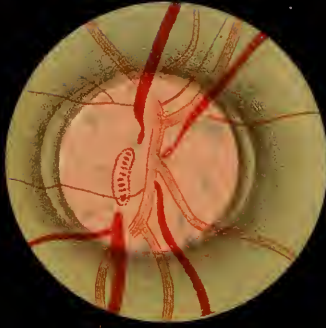
approaching, in fact, to that of the natives of India. But even among people of mixed blood in this country, whose skins are very dark, there is always a nearer approximation to the appearance of the European eye than that of the native; in the latter only have I met with a complete and absolute wall of separation between the choroid and retina, depending upon the black pigment contained in the hexagonal cells of the elastic lamina.

It is not by any means an uncommon abnormal condition to find the fundus of the native's eye of a deep red colour, somewhat like that of the European; this depends upon congestion of the vessels of the retina and destruction of the hexagonal cells, so that a certain amount of light is reflected from the choroid, and, combined with that from the congested retina, causes the fundus to appear red. Under these circumstances, other alterations will be at once perceptible, enabling us to determine the nature of the disease, but these I will not now stop to describe. It is sufficient for me to repeat, that in the healthy eye of the native of India, the fundus is of a uniform greyish-brown hue, the exact shade depending upon the colour of the pigment cells of the elastic lamina and choroid; the only exception to this being in those parts of the retina occupied by the retinal vessels and the optic disc. The macula lutea is not perceptible unless especially searched for, and therefore offers no exception to the general rule above laid down, that in the native, the fundus of the eye is of a greyish-brown colour.

The *optic disc* or *papilla* will be found, as I have before stated, about one-tenth of an inch internal to the axis of the eye ; it is the first point which would naturally attract the observer's attention in making an examination with the ophthalmoscope. The general shape of the healthy papilla is round, but it varies somewhat in different individuals : sometimes it is elongated from above downwards, but never from side to side, unless as the result of disease. Its size, too, is by no means the same in all cases, and will, of course, appear to be augmented or lessened according to the power used to magnify it. The colour also of the papilla is subject to variation : it is of a more decided pink hue in the native than in the European eye, where, in fact, it is of a whitish yellow colour ; but it may be of a lighter or darker pink, or yellow, without there being any reason to suppose the part is diseased. The centre of the normal optic disc is somewhat depressed, and of a lighter colour than its outer part.

We sometimes meet with cases in which a collection of black pigment surrounds a portion of the circumference of the papilla ; this is due to a number of choroidal cells becoming jammed together under the elastic lamina ; it is not an indication of disease. Such a black rim, or crescent surrounding a part of the disc, is often seen in eyes which are otherwise perfectly normal.

Another condition of the border of the papilla, not unfrequently seen, and one which is perfectly consistent with its healthy state and functions, is shown



in Fig. 1, Plate III. The margin of the disc appears as if consisting of two rings, one inside the other, the internal one being due to light reflected from the inner opening of the lamina cribrosa, and the outer to the rounded border of the choroid. I am not convinced that this is the true explanation of the appearance above described, but it is a point of far greater importance that you should be aware of the occasional existence of this condition of the parts in health, than that you should be able to give an accurate interpretation of it.

The point at which the *central artery and vein* of the retina enter the eye through the optic disc, is subject to considerable variation. Generally, the vessels pass through the centre of the papilla, but they may perforate it in any other position; and often one or two larger branches are noticed in its centre, while others pass through its circumference, frequently close up to the marginal rim of the disc.

The apparent calibre of the vessels will, of course, vary with the magnifying power employed in observing them (compare Figs. 1 and 2 of Plate II. with those of Plate III.); and as I have before stated, it is very desirable that you should not, under ordinary circumstances, change the power you use in examining the eye, so that you may be able to tell at a glance if the vessels are of their normal size or not. A very little practice will thus enable you to appreciate in a moment any important changes in the calibre of the retinal vessels. The veins, as you will see represented in Figs. 1 and 2, Plate III., are of a darker and more

uniform colour than the arteries, and the latter appear to be transparent in their centres; this arises from the difference in the degree of illumination of the prominent centres of the vessels, as contrasted with their sides: from their conformation, it is evident that the sides of a vessel would receive and reflect relatively less light.

If in the normal eye, the central vein be carefully examined, a distinct *pulsation* may be noticed in it, which will be rendered more evident on gentle pressure being made on the eyeball. If the compressing force be increased beyond a certain point, the pulsation at once stops, and the veins become almost invisible from the cessation of the flow of blood through them. In the healthy eye no arterial pulse can be seen, but if pressure be made on the eyeball it will at once become apparent. We notice this in a very marked manner in cases accompanied with considerable intra-ocular pressure, as for instance, in glaucoma.

After the vessels have crossed the disc they branch out in all directions, as shown in the Figs. of Plate II. There is one spot, however, the *macula lutea*, already described in an earlier part of this lecture, which is left free from vessels; they branch over and under, but do not cross it. With regard to this spot, it may be always readily seen in the healthy eye of the European; there is a little more difficulty in detecting it in the native; but if a mirror with a flat surface be employed as an ophthalmoscope, after the manner of Coccius, with a concave glass behind it, not only the fovea centralis, but also the border of yellow color-

tion around it may be distinguished. I prefer solar to artificial light for illuminating the fundus of the eye, when these parts are the subject of observation.

After what I have stated, it is almost superfluous to add, that in the healthy eye of the native, it is quite impossible for us to see the sclerotic with the ophthalmoscope; for if the hexagonal cells of the elastic lamina hide the choroid, much more must they, together with the pigment cells of the choroid, entirely conceal the sclerotic. This remark does not, however, hold good with regard to the optic disc; over this spot there are no pigment cells, the only structures that cover the lamina cribrosa being the nerve fibres of the optic disc and its capillary vessels, and hence the pink colour of the disc. In some cases this spot appears to be faintly streaked or spotted with light-blue dots (*vide* Fig. 1, Plate III.), which represent the points of entrance of the optic nerve, through the fibrous bundles of the lamina cribrosa; the light, penetrating the nervous tissue to a slight extent, causes a contrast in colour between the openings and the dense fibrous network of the lamina cribrosa.

Before closing this lecture, I must make a few remarks on the *abnormal appearances of the optic disc*. The condition of the papilla is so frequently noticed in ophthalmoscopic examinations, that it will be impossible for you to follow me in my subsequent lectures, unless you have some previous idea of the significance of the various changes I may have casually to mention,

and which it would be inconvenient to stop and explain on each occasion they are referred to.

Uncomplicated *hyperæmia*, or *neuritis* of the optic disc, is a rare affection, for abnormal changes in the papilla must generally spread to the retina. In cases of fever, however, brought on from over-exposure to the sun, the disc becomes of a bright scarlet colour; whereas the vessels of the retina are comparatively slightly congested, the most active changes evidently going on in the papilla. Under these circumstances the nervous elements of the disc become hazy and swollen, and its margin ill defined, on account of the choroidal rim being concealed by the opaque fibres of the nerve passing over it to the retina; and it is not uncommon to meet with extravasations of blood on the surface of the papilla. What we have most to fear, however, in these cases, is the occurrence of that most formidable affection—progressive atrophy of the disc, terminating in complete loss of vision. Fortunately, pathological changes of this description are seldom induced, unless after repeated or long-continued attacks of congestion of the papilla; the advance of the disease from one stage to another is usually slow, and it may remain stationary, or subside altogether in time.

A patient suffering from optic neuritis complains of pain in the back of the eye, usually extending to the head and temple, and the sight is always more or less defective; but it is by means of the ophthalmoscope alone that we can arrive at any positive conclusion as to the nature of

the disease. If the neuritis has not advanced beyond its first stage, or that of thickening and opacity of the nervous elements of the papilla, hopes may always be entertained of recovery, or, at any rate, that the course of the affection may be stayed by judicious treatment; arsenic, iodide of potassium, counter-irritation and leeches, being frequently of the greatest service.

It is not an uncommon thing to meet with people in this country suffering from headaches induced by over-exposure to the sun. The papilla will often be found intensely congested under these circumstances, the capillaries of the retina being somewhat hyperæmic also. The glare of the tropical sun appears to over-stimulate the retina, and it becomes congested and swollen; if the exciting cause continues in operation, the irritation is propagated to the brain, and headache and irritative fever ensue.* There can be little doubt as to the necessity of protecting one's head from the rays of the sun, but it is almost as important to shade the eyes from its glare. Nature appears to have made a provision of the kind for the natives; the colouring matter contained in the pigment cells of the iris, choroid, and cells of the

* It has been suggested by a writer in the *Ophthalmic Review*, that these observations of the author on the occurrence of vascular changes in the optic disc independently of the retina, and of their propagation to or from the brain, may possibly receive explanation from the recent researches of Dr. Galezowski. The latter tend to show that the capillary vessels of the optic disc form part of the vascular system of the brain, and that they are not derived from the central artery of the retina.— See the *Review* for April, 1866.

elastic lamina, absorbing the excess of light which would otherwise impinge on the retina, and acting in much the same way as blue or neutral-tinted glasses do in the case of Europeans. But even among the natives, the glare of the sun, in the long run, causes irritation, and often, I believe, chronic congestion of the choroid, which, in its turn, induces opacity of the lens.

You may have to give an opinion regarding the state of vision of either officers or men in Government employ, who have been exposed on service to the glare of the sun, and whom you may discover to be suffering from *cataract*. The question will arise, has the nature of their duties given rise to the opacity of the lens, or has it come on from causes totally independent of their work? My own impression is, that exposure to the sun, by inducing congestion of the choroid, tends directly to cause cataract, aided, no doubt, by the hardships incident to a campaign in this country. Opacity of the lens rarely occurs as a primary affection; it matters not if its nutrition is disturbed from mechanical causes, or from disease of the choroid (senile or otherwise), the result is the same, and without some such disturbing influences, opacity of the lens is seldom met with.

I have before stated that *atrophy of the papilla* may arise from repeated attacks of optic neuritis, but this is by no means the only or even the most common cause of atrophy. Retinitis, by involving the optic disc, may occasion it; and abnormal formations pressing on the nervous or vascular supply of the papilla

are likely to give rise to fatty degeneration, and consequent wasting of its fibres; or syphilitic inflammations of the sheaths of the vessels in the cavernous sinus, or of the fibrous sheath of the optic nerve, may induce the same result. Lastly, pathological changes in the nervous elements throughout any portion of the optic tract or its connexions may give rise to atrophy. It would be quite beyond my present purpose to enter upon the consideration of these various affections; many of them will be incidentally mentioned in my subsequent lectures, but any further consideration of this part of my subject would lead me into the mazes of diseases of the brain, which, no doubt, the professor of medicine has already made clear to you. All the knowledge you possess upon these points, will frequently be taxed to the uttermost, to enable you to discover the nature of the various cases of atrophy of the disc which you will meet with, more particularly if one disc only is diseased.

If you refer to Carter's Translation of *Zander*, p. 131, you will find a *résumé* by the author, of the opinions of different observers as to the effects of *tobacco smoking* upon the optic nerve. At present, we can only say that the deleterious influence of this narcotic on the elements of the nerve is not proven; but it is well you should be aware of the fact, that surgeons of eminence believe that excessive smoking tends to produce atrophy of the disc. I have not remarked that this is a common form of disease among the natives, although both men and women smoke to a very con-

siderable extent from the time of childhood. But I have had several instances of atrophy of the disc at various times under my care, in which I have been unable to trace the wasting of the nerve to any definite cause, unless it be that smoking Indian hemp or opium has the same effect on it as tobacco is said to have.

An atrophied papilla, when examined with the ophthalmoscope, appears to be flat, and of a perfectly white colour, like a piece of glazed paper, its nervous structure having degenerated into fibrous tissue; this material, together with the lamina cribrosa, which shines through the atrophied elements of the disc, produce this glistening appearance. The circulation through its vessels, upon which its pink colour depends, has also ceased, in consequence of their becoming atrophied. It is seldom that changes of this kind advance far without the retina being involved in the disease; its vessels commonly dwindle away, and are frequently lined with a narrow white streak of atrophied tissue; but the flat and glistening white appearance of the optic disc is alone pathognomonic of atrophy of its nervous structure.

The symptoms preceding these changes will of course depend upon the primary cause of the disease, and will vary as the latter varies. I need hardly remark that, atrophy having once taken place, we can do nothing to restore the degenerated tissues; the case is then a hopeless one. In many instances, however, in which the disc appears completely atrophied, the patient retains some amount of vision,

and if we can trace the changes going on in the papilla to syphilitic disease, we may hope to stop its further progress by a course of bichloride of mercury and iodide of potassium.

Extravasation of blood into the substance of the optic nerve is an affection which we are unable to detect with the ophthalmoscope, but this instrument, nevertheless, affords us very decided help in our diagnosis, though of a negative kind. The loss of vision consequent on apoplexy of the nerve or optic tracts, usually comes on suddenly and without pain; the patient, probably after overstraining the eyes, or subsequent to a violent fit of vomiting or coughing, discovers that the sight of one of his eyes has become impaired to a certain limited extent, corresponding to that part of the retina which is supplied by the injured fibres; consequently, he can see objects very well in certain directions, with the healthy part of the retina, and it is only when rays of light fall on its non-sensitive portion that the imperfection of vision is discovered. If, in a case of this kind, the ophthalmoscope reveals to us no disease of the fundus or dioptric media, we may suppose that the nature of the affection is such as I have indicated. Hæmorrhage into the choroid, it is true, may not be discovered in the case of the native, on account of the pigment in the hexagonal cells of the choroid; but unless it be very extensive it does not induce loss of vision; so that, as I have before said, your diagnosis will probably be correct, if, with the above history, you put down the affection to extravasation of blood into

the substance of the nerve. Fatty degeneration with rupture of the fibres of the optic tract, is, I think, the only other pathological condition which might give rise to similar symptoms.

Your prognosis in a case of this kind must be very guarded ; it is seldom that the patient regains the sight he has once lost ; but, in recent cases, you may act upon the supposition that it is possible for absorption to occur if blood has been extravasated, and by keeping the eye at rest, by care and general treatment, endeavour to bring the system into as favourable a state of nutrition as possible, and thus promote the absorption of the effused blood, or quicken the reparative process required to effect a cure.

Excavation of the optic disc is an abnormal condition of the part which has been made the subject of frequent discussion, and much has been said as to the means of recognising it, and the appearances presented by the papilla. For my own part, I cannot say that I have experienced any trouble in this respect ; and with the binocular ophthalmoscope, it appears to me just as easy to see the depression of an excavated optic disc as it is that of a soup plate. As, however, an instrument of the kind is not always available, it will be well to accustom yourself to the appearances of the excavated papilla as seen with the ordinary ophthalmoscope. If the vessels at the margin of the excavated disc be brought into focus, it is evident their continuation over the papilla cannot be distinctly seen till the accommodation of the eye is altered, as the vessels on the disc are on a plane posterior to that of

its margin. Conversely, if the focus be altered, so that the papilla is accurately defined, the vessels passing over the fundus of the eye will be indistinct. Again, if the retinal vessels be traced up to the margin of the disc, they will appear to terminate there in "beak-shaped points," and their continuation over the papilla will seem to be interrupted and displaced, as shown in Fig. 2, Pl. X. The explanation of this is, that the vessels having arrived at the edge of the excavated disc, dip down over its margin, and in their course along the sides of the excavation, they cannot, of course, be seen by rays of light falling perpendicularly upon the disc; but as they pass over the bottom of the excavation they are again visible, although evidently on a plane posterior to the fundus of the eye. If, however, the patient is made to turn his eye upwards or downwards, and the light from the ophthalmoscope be thrown obliquely upon the disc, so as to illuminate the sides of the depression, the vessels may be traced throughout their course; unless, as sometimes happens, the choroidal margin bulges very much inwards, like a rock overhanging a precipice, when the vessel, winding round the projection, must be entirely hidden from view till it reaches the bottom of the excavated papilla. If the direct method of examination be employed, the parts will be more highly magnified, and therefore more distinct; and the difference between the situation of the vessels of the retina and their continuation over the papilla, will be more marked, than if a convex lens be interposed between the ophthalmoscope and the patient's eye. But,

as I have before stated, with a binocular ophthalmoscope, there cannot be the slightest difficulty in ascertaining at a glance if the papilla be excavated or not.

Excavation of the disc may arise from various causes, and *first*, from diseases attended with choroidal effusion, as glaucoma; *secondly*, from congenital malformation; *thirdly*, from atrophy with retraction of the optic nerve.

In glaucomatous excavation, the whole disc is involved, so that its sides are precipitous; the vessels may be seen at its margin, terminating as it were in hook-shaped extremities, represented in Fig. 2, Plate X. In addition to these changes, others will be noticed hereafter in the fundus of the eye, which are pathognomonic of the disease.

In cases of excavation of the papilla arising from congenital malformation, the entire disc is seldom involved in the disease, occasionally only a very small portion of it. I have seen several congenital cases in which the whole of the disc was excavated, with the exception of a very narrow edge round its margin; so that its choroidal rim was normal, and within this was a narrow edge of the papilla, the remainder of it being deeply excavated. Malformations of this description do not appear necessarily to give rise to any subsequent changes, though, of course, an eye in this condition is by no means exempt from an attack of glaucoma, or any other form of disease to which it is subject under ordinary circumstances.

Lastly, excavation of the disc, arising from atrophy and retraction of the optic nerve, is marked by a

comparatively slight amount of depression, its sides sloping down gradually from the circumference towards its centre. The vessels may therefore usually be traced throughout their extent; but when the branches coursing over the fundus of the eye are in focus, those passing over the disc will appear very hazy, until the accommodation of the eye is altered so as to bring them distinctly into view. In cases of this kind, the retina will probably have undergone marked changes, its vessels being contracted in calibre, and, as I have before remarked, lined by a streak of white atrophied tissue.

LECTURE III.

Cases Illustrating the Effects of Inherited Syphilis on the Structures of the Eye. Syphilitic Keratitis. Characteristic Conformation of the Teeth. Iritis. Opacity of the Vitreous and Lens.

WE have lately had several patients in Hospital, suffering from the effects of *inherited syphilis*, and I shall therefore take, as the subject of my lecture to-day, some of those affections of the eye which are among the many ill consequences of that condition.

The first case I wish to notice is that of a boy, sixteen years of age, named Jogender Nath Dey, who was brought here by his father, on the 2nd of September, suffering from *syphilitic keratitis*. The man informed me he had had five children, and that seventeen years ago, after the birth of his eldest son, he contracted syphilis. There seemed no reason to doubt that he then had a chancre, which was followed by enlargement of the glands of the groin, and secondary symptoms. Jogender was born a year afterwards, and inherited the disease from which his father was suffering. I had an opportunity of examining his elder brother; he was perfectly free from any trace of the syphilitic taint; but my patient, who is the second son, and his two younger brothers, bore evidence of

the existence of the disease in the state of their incisor teeth.

Jogender was a well-grown and remarkably intelligent lad ; he stated that, as far as he could remember, he had enjoyed uninterrupted good health up to the present time, and that the affection of the eye from which he was suffering, commenced about six weeks prior to his coming to the Hospital. In the first instance, he noticed that objects held before his left eye presented a hazy appearance ; ultimately, the sight of the right eye grew dim also, so that he is now nearly blind. During this time he suffered no pain or inconvenience beyond the gradual loss of vision.

I found both eyes in much the same condition ; the sclerotic and conjunctiva being perfectly normal, but the cornea presenting the ground-glass appearance of keratitis, with the characteristic zone of vessels round its margin ; and, in addition to this, flocculent-looking spots, of a whiter hue than the rest of the hazy cornea, were scattered throughout its substance. This condition of the cornea is often seen in syphilitic keratitis, and has been correctly described as resembling finely-ground glass, behind which spots of a thin white paint have been daubed ; it is due to changes taking place in the cell-substance of the laminated tissue, by which it is converted into a fatty material.

On examining this boy's teeth, the superior incisors were found to be widely separated from each other and club-shaped, their thin cutting edges being notched in the manner described by Mr. Hutchinson as pathog-

nomonic of inherited syphilis, and plainly indicating the primary cause of the disease from which he was suffering. The following mixture was prescribed:—

Bichloride of mercury	1 gr.
Iodide of potassium	1 drachm.
Water	8 oz.

Half an ounce to be taken twice a day after meals. He was also ordered to rub a drachm of mercurial ointment over the forehead and eyebrows, for twenty minutes every night; and lastly, I directed him to take regular exercise and a full and varied diet.

The medicines were used perseveringly; and on the 20th September, the report states that the left cornea was decidedly less opaque than at the commencement of the month. The mercurial ointment was now discontinued, but the mixture was repeated. On the 15th of October his eyes were very much better, and the iodide of iron was substituted for the bichloride of mercury. A month later both corneæ were perfectly transparent, no vestige of the keratitis remaining.

I have brought this case to your notice as a well-marked example of the effects of inherited syphilis upon the cornea, and as we can readily watch the changes which take place in this fibro-cellular tissue, its study will elucidate the history of other syphilitic affections of the eyes, depending upon a similar cause, but less open to observation.

It is hardly necessary for me to mention, that when either parent has been affected with primary or secondary syphilis, their offspring are very likely to

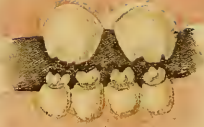

PLATE IV.

1



2



5



3



4




6



8

7



inherit the disease. In a series of cases of keratitis and iritis occurring under these circumstances, Mr. Hutchinson noticed a *peculiar formation of the teeth*, which ultimately led him to the conclusion, that their condition might be relied upon as a test of the existence of inherited syphilis in the system. Plate IV. is a copy from his work on syphilitic disease of the eye and ear, and it accurately represents the appearance of the incisor teeth usually met with in these cases. In Fig. 1, a few delicate prominences are noticed on the edge of the central incisors; these gradually wear away after the child has used them for a time, and the free border of the tooth then becomes curved, as shown in Figs. 3 and 5. A very common appearance of the syphilitic incisors is depicted in Fig. 8. These, you will notice, are the permanent teeth; in the case of the temporary set, it is often more difficult to make out abnormal changes of this kind; but still they grow in an irregular manner, and are more or less club-shaped.

Jogender Nath Dey's teeth were notched and irregular, and so were his younger brother's; but it was the condition of my patient's eyes which led me at once to suspect that he was suffering from syphilitic keratitis. In non-specific inflammation of the cornea, it is by no means an uncommon thing to see a portion of its laminated structure remaining transparent, while other parts present a ground-glass appearance. This is also the case in syphilitic keratitis; but in this form of disease, the hazy cornea is always dotted over with patches of a denser opacity than that of the rest of the

inflamed tissue, unless the case be near recovery, when the white spots gradually disappear, and the cornea ultimately resumes its usual transparency. These changes do not depend upon the effusion of lymph, or upon any of the so-called inflammatory deposits in the substance of the cornea; they are entirely due to alterations in its cell-substance, which becomes opaque from mal-assimilation, fatty deposits taking the place of the normal ex-nuclear material, and hence the granular appearance of the tissue.

So long as the structural changes have not passed this stage, and the nuclei remain uninjured, the opaque products may be absorbed, and the cornea return to its normal condition. But in place of healthy action being set up, the cell-substance may be further developed into an heterogeneous structure of a fibrous character, and then the transparency of the cornea must be permanently destroyed. Or, the nuclei at the principal point of disease may break up, each particle attracting fresh material to itself in such abundance, that the part becomes swollen from the increased bulk of the new formation; then those cells furthest from the original source of these changes, being of low vitality, degenerate, and are pushed off by the rapid growth of fresh material going on beneath them; the tissue is thus broken down, and an ulcer is the result.

Except, however, in neglected instances, among the poor and ill-fed classes, ulceration is by no means a common sequence of syphilitic keratitis; the majority of cases certainly recover, although if the process of cure be left entirely to nature, it may take a very long

time before the diseased action is overcome; on the other hand, if assisted by appropriate treatment, a comparatively speedy recovery may take place. The average duration of syphilitic keratitis, if brought early under treatment, does not exceed three or four months, and sometimes it may disappear in even a shorter period. It is advisable, however, to continue a specific course of treatment for some time longer, in the hopes of not only relieving the eye, but of destroying the dyscrasia which is the primary cause of the disease.

In the case under our notice, there was only slight congestion of the sclerotic, but this is by no means a general rule, the conjunctiva, sclerotic, and cornea frequently becoming very vascular. Photophobia, likewise, occasionally exists, indicating considerable irritation of the retina.

No doubt the syphilitic diathesis renders children generally sickly, on account of the mal-assimilation which it engenders. Among the natives, however, the great majority of these weakly infants die off before they reach the age of two years, and those who survive are the descendants of a naturally robust and strong stock. As a consequence of this, you will not meet with the emaciated, miserable, sniffling, half-crazy creatures, whom you might otherwise expect to find among your syphilitic eye and ear patients; on the contrary, most of those suffering from keratitis and affections of the vitreous will be apparently healthy. An additional reason for this is, that frequently the syphilitic poison does not give rise to any

perceptible changes in the system, until the child is four or five years old: it is rare to meet with an instance of syphilitic keratitis occurring under four years of age, and opacities of the vitreous and lens seldom make their appearance before the adult period of life. Inherited syphilitic iritis, on the other hand, generally commences when the infant is a few months old.

The *treatment* of syphilitic keratitis should consist, principally, in attending to the patient's general health, and keeping his system in good working order, by a simple, but at the same time generous dietary, with plenty of fresh air and exercise. The affected eye should be kept at rest by a small pad of cotton wool placed over it, and retained in position with a light bandage.

With regard to drugs, I believe that mercury, judiciously used, is the sheet-anchor upon which we must rely for the alleviation of syphilis. The best mode of employing it in these cases is by inunction, the mercurial ointment being rubbed into the thighs and armpits twice a week, for twenty minutes at a time. I never prescribe mercury internally for children, nor do I find it necessary to push the treatment so far as to affect the gums. In robust and healthy patients, therefore, suffering from syphilitic keratitis, begin at once with a course of mercury, and carry it on for four or five months, whether the disease of the eye be cured or not. Sickly children, however, cannot undergo this treatment, and cod-liver oil and iodide of iron, with occasional doses of hydrarg. c.

creta, quinine, and soda, must be substituted for mercury.

If there be no congestion of the vessels of the sclerotic or conjunctiva, a solution, consisting of two grains of iodine to an ounce of glycerine, may with advantage be dropped into the eye twice a day. In almost all cases, an issue opened in the skin of the temple will prove most serviceable. A bit of the integument being nipped up between the finger and thumb, a needle with a few threads of silk is passed through the fold; the thread is then tied in a knot, and left in this way for three weeks or a month. I have tried the plan of passing a thread through a fold of the conjunctiva, close to the cornea, but the ligature quickly ulcerates through this delicate structure, and a succession of such issues possesses no advantages over one formed in the temple. If your patients object to this mode of treatment, you must apply a series of small blisters over the temple; they are not nearly so efficacious, however, as an issue.

The *iris*, as you know, is very apt to suffer from the effects of syphilis. I have already mentioned, that *iritis*, arising from the inherited form of the disease, generally manifests itself when the infant is only a few weeks or months old.

We have a well-marked example of this form of disease under treatment, in the daughter of one, Kally Doss. The infant is now six months old; she was brought to the hospital on the 19th of October, suffering from iritis in both eyes; her head was covered with

psoriasis, and she was a weak, puny child, with sores about the lips and nose. Her father confessed at once to having contracted the venereal disease some eighteen months ago : at present he has spots of roseola scattered over the surface of his body, and a large node on the left tibia. He stated that, a month after the child's birth, he noticed a slight discharge from her eyes, since which time she has hardly ever opened them. On examination, it was found that the pupils were irregular and did not respond to the stimulus of light ; the irides looked dull, and small nodules of exuded lymph could be seen on their surface ; there was a distinct zone of sclerotic vessels round the circumference of the cornea. I ordered atropine drops to be applied to the eyes three times a day (four grains of atropine to an ounce of water), the mercurial ointment to be rubbed into her thighs every other night, and thirty drops of cod-liver oil, with half a grain of iodide of iron, to be administered twice a day. A wet nurse was also procured, as the mother's milk was evidently insufficient ; and though I did not see her, I think, from what her husband states, there can be little doubt that she also was suffering from syphilis. In cases of this description, it is always advisable to procure a wet nurse, or, if that is impossible, to bring the infant up by hand.

I found it unnecessary to continue the atropine for more than three or four days, as the pupils dilated freely under its influence. After six weeks' treatment, the infant had so far improved, that the left pupil, though slightly irregular, contracted and dilated

readily on exposure to light; the right pupil was perfectly regular, and responded freely to its natural stimulus, and the congestion of the sclerotic had entirely disappeared.

In this instance there was no difficulty whatever in ascertaining the primary cause of the disease; you may, however, have to deal with people who will obstinately refuse to give you a clue to their previous history, or even worse, they will positively mislead you by false statements. It is necessary, therefore, to examine an infant's eyes most carefully under such circumstances, as it is from the appearance of the parts alone that the nature of the malady can be satisfactorily ascertained; and this is particularly the case with respect to the iris, as there may be few, if any external symptoms, indicating the serious nature of the disease going on in the eye, but which, nevertheless, by extending to the choroid or retina, may cause permanent blindness.

It is frequently a matter of considerable difficulty to recognise iritis among native children; the iris being almost black, it can hardly be distinguished from the pupil, and slight alterations in the form of the latter are not nearly so palpable as in the eye of the European, whose iris being of a lighter colour, irregularities of its free margin are at once seen in contrast with the black pupil. If you have distinct evidence of the existence of iritis in an infant only a few months old, you may depend upon its being syphilitic, and treat it accordingly, although the parents deny ever having had the venereal disease.

The effects of inherited syphilis upon the *deeper seated structures* of the eye, more particularly the *vitreous* and *lens*, have only lately been made known to us by means of the ophthalmoscope; yet they are of common occurrence, quite as much so as similar affections of the iris or cornea. The eye, under these circumstances, presents all the external appearance of health, and yet the patient complains of gradual loss of sight, coming on without pain, and usually commencing about the adult period of life, though it may begin earlier; in other cases, these symptoms may not be developed till the patient is thirty years of age.

We have lately had a well-marked instance of *opacity of the vitreous* from this cause in Hospital, in the person of D. Goodman, aged twenty, a native of Australia, who was admitted under my care on the 26th of June. Until he was ten years of age, his eyesight was perfectly good, and he learnt to read and write with ease; but about this period he became gradually short-sighted, so much so that he could no longer make out small print unless within a few inches of his face, and he was consequently punished for supposed carelessness and inattention. His parents were unable to see that he had anything the matter with his eyes, and they were confirmed in their opinion that he was shamming by two surgeons in Sydney. The boy, finding he was disbelieved and maltreated for no fault of his own, at length ran away in disgust, and worked his way up to Melbourne. He remained there for several years,


employed as a messenger, his sight continuing in much the same state as when he left home; and he now discovered that he could only see objects in a certain position with the right eye.

Two years ago, Goodman met with a friend from England, who told him that he had been cured of an affection of the eyes similar to his, and in consequence our patient determined to go to London for advice. He got a berth as assistant to a ship's cook; but in place of going to the metropolis, he found himself at the end of his voyage in Liverpool, and evidently never thought about his eyes after he got there. Subsequently, he was seized with what appears to have been an attack of pneumonia; this left him very weak, and his sight growing worse, his original intention recurred to him, and he started off to London. Although he arrived there in a weak state, he managed to contract venereal disease, and being utterly worn out by dissipation and bad health, he became anxious to return home, and to that end, got himself smuggled on board a ship going to Australia by way of Calcutta, for he was now too blind to work his way as a sailor.

Goodman came under my care very soon after arriving here. He appeared to be in robust health, and was a strong, well-made lad. The right eye was affected with internal strabismus, but beyond this no symptoms of disease were visible; the eyeballs were of normal tension. With the left, he could read No. 8 type at a distance of eight inches, but with the right, he could not decipher the largest sized print; he could just distinguish a white from a black object,

but beyond that he was unable to discern anything with this eye. On inspecting his teeth, I found that the incisors were irregular and notched (*vide* Plate IV.), and plainly told their own tale as to the syphilitic taint under which he laboured. I applied atropine to both eyes; and on examining the right with the ophthalmoscope, discovered that there was *dense opacity of the vitreous*, so much so that it was impossible for me to see the optic disc or retina, (Fig. 1, Plate V.) The left vitreous, though very hazy, was sufficiently transparent to allow of the optic disc being seen through it (Fig. 2). I ordered him full diet, and a mercurial vapour bath every other night.

On the 11th of July, after having had seven of these baths, his gums became slightly tender, and he was directed to take one twice a week only, in future. He continued this treatment up to the 30th of July, when, on account of his general bad behaviour, it was found absolutely necessary to turn him out of the Hospital. Before leaving, his sight had decidedly improved, he could see to read No. 4 type, at ordinary distance, with the left eye, and could decipher large type with the right; in fact, as he stated himself, he could see better than he had done for the last six years. On examining his eyes with the ophthalmoscope, the favourable changes that had taken place were very evident: the left optic disc and vessels of the retina could be distinctly seen, though there was some slight haziness of the vitreous; the right eye was in much the same condition as the left had been when first I examined it, but on the outer side of the papilla there was a



dark spot of extravasated blood in the retina, which, by destroying its functions in this situation, had induced internal strabismus.

This is an interesting case for many reasons, illustrating, as it does, a common form of disease of the eye produced by inherited syphilis. We meet with a similar condition of the vitreous arising from the effects of primary syphilis, the tendency of which, like that of the inherited form of the disease, is either to recede or advance. Of this I shall speak in my next lecture.

These changes in the vitreous usually take place very slowly, and the structure may at any time gradually clear and become transparent; or, on the other hand, if the degenerative process continues, it may lose its consistency, and pass into a *fluid state*. Flocculent masses will then be seen floating about in it; while from the loss of the support which, under ordinary circumstances, the vitreous affords the retinal vessels, they may give way, and blood become effused into the retina, giving rise to the appearance noticed in Goodman's eye. I believe the healthy vitreous always contains a network of cellular tissue; and it is through the influence of the syphilitic poison upon this structure, that these pathological changes are brought about, which, you will observe, are very similar to those which take place in keratitis. The analogy is not confined to the changes that occur in the cellular elements: vessels, after a time, may be formed in the vitreous, as in the cornea.

In Goodman's case, the abnormal condition of the

vitreous appeared to become stationary for some time, and the opacity commenced sooner also than it usually does as a consequence of inherited syphilitic disease: eighteen or nineteen is about the period of life when the symptoms generally make their appearance. The disease is accompanied with no pain in the eye, and the patient complains of no inconvenience beyond the gradually increasing loss of sight. At first, therefore, the symptoms are apt to be neglected, and very probably considered as indicating merely the existence of myopia; but after a short time, no glasses can be found which will improve the sight, and on making an ophthalmoscopic examination, the real nature of the disease will be discovered.

A degeneration, similar to that which occurs in the vitreous, may also take place in the *lens*, so that, as I have pointed out to those attending my practice, *cataract* may be induced by inherited, and also by primary syphilis. You may be in doubt as to the exact seat of the morbid action going on in the eye, in these different forms of internal opacity; the hazy appearance of the retina might be caused by a thin layer of lymph effused over its surface, or by opacity of either the vitreous or lens. We will, for the present, dismiss the first of these from our consideration, and simply state the means by which we may arrive at an accurate diagnosis between incipient cataract and a hazy vitreous.

Syphilitic opacity of the lens, like that of the vitreous, commences in a diffused haziness of the

part, so that you can only judge of the precise seat of the disease by its relative depth from the cornea or iris, and not from any specific difference in the abnormal appearances. To distinguish between them, the fibrous structure of the iris must be brought into focus with the ophthalmoscope; if the opacity is in the lens, it will be clearly defined without any appreciable effort on the part of the observer to accommodate his eye to a more distant point, which would not be the case if the vitreous were the structure implicated. By practice, the eye gradually learns to appreciate even minute differences in the relative distance of opacities in these structures, either from the cornea and iris anteriorly, or from the optic disc posteriorly.

The situation of opaque spots or lines in the vitreous may be determined, by bringing the optic disc into focus by the *indirect* process of examination; if the lens held in front of the cornea be moved to the right hand or left, the disc will move in the opposite direction, and if the opaque spots be much anterior to it, they will move in the same direction as the lens.

In making ophthalmoscopic examinations of opacities of the vitreous or lens, it is advisable to use a dim light for illuminating the eye: the flame of the kerosine lamp, for instance, should be turned down, so as to give a very moderate degree of light, otherwise so much will penetrate the eye, and be reflected from the fundus, as to destroy the minor reflections from the hazy lens or vitreous, which will thus be rendered dim and obscure.

Changes in these structures are most readily detected by the *direct* process of examination; in fact, you should always make a point of examining an eye by this means before using the indirect method; a fluid or hazy vitreous may be overlooked for want of this precaution. If, however, there is any doubt in your mind as to the condition of the lens, you should invariably employ *lateral* illumination; by this means, it is almost always possible accurately to define structural changes in that situation, and should there be any opaque lines or dots in it, they may be distinctly seen, and the nature of the disease determined without any further trouble. In the majority of cases of incipient cataract, you will discover one or two landmarks of this description; but, unfortunately, where they are most required as aids to diagnosis, namely, in cases of syphilitic cataract, nothing more than a diffused haziness of the lens is to be seen.

Supposing that, in a particular instance of this kind, you fail to satisfy your mind as to the exact seat of the disorder, but have discovered that either the lens or the vitreous is hazy, or perhaps both, the history of the case will still direct you sufficiently in the treatment. If the patient has teeth indicating the existence of inherited syphilis, or has secondary symptoms, and is a comparatively young man, not likely to suffer from idiopathic cataract; under such circumstances, you may be tolerably sure that, whether the opacity be in the lens or vitreous, a steady course of mercury will cure the disease, provided the patient be otherwise in good health, and that there are no circumstances

contra-indicating the employment of this drug. We have a good illustration of this in a case which is still under treatment:—

A. Gomes consulted me on the 20th of August on account of dimness of vision, which commenced some seven months since, and has gradually increased up to the present time; he is now unable to continue his work as a carpenter. About a year ago he had an attack of syphilis, which was followed by an eruption over the surface of the body, and other secondary symptoms. On examining the eyes, I found that *both lenses were decidedly opaque*, in other respects they appeared to be perfectly healthy. I ordered him the iodide of potassium mixture three times a day, and a mercurial vapour bath twice a week. Under a steady course of treatment of this kind, his sight gradually improved, and he can now see to thread a needle; the haziness of the lenses has almost entirely disappeared. I have referred to this case simply to show that, if the abnormal changes induced by syphilis are situated in the lens, the same plan of treatment should be adopted as has been recommended in syphilitic opacity of the vitreous. Should the patient be weak and anæmic, you must first give tonics, and having improved his general health, you may proceed to put him under a course of specific treatment; this should be continued for some months after all trace of the disease has disappeared, your object being to eradicate the syphilitic taint from the system, which can only be effected by a prolonged and steady use of mercury.

In examining cases of syphilitic opacity of the vitreous, you may frequently notice that the fundus of the eye appears to be deeply *opaque in patches*, situated apparently behind the vitreous; this condition of the parts is generally caused by *effusions of blood or lymph* into the retina or choroid. It is very rare to find the vitreous itself so densely opaque, as entirely to obscure the reflection of light from the fundus of the eye: a dull, foggy glimmer from the retina may almost always be noticed through the diseased humour. But when, in addition to this, the reflections from definite portions of the fundus are particularly dull, you must be very guarded in your prognosis; it is more than probable, that in such cases, after the vitreous has cleared, you will discover further mischief to have taken place behind it, in the retina or choroid,—the dark patch which you had observed, corresponding to effused lymph or blood in these structures, which will permanently damage the eye.

After the vitreous had so far cleared as to enable us to see the retina in Goodman's eye, we observed a large spot of extravasated blood on the outer side of the optic disc. This was sufficient, no doubt, to account for the strabismus: the effusion being in the direct axis of vision, the retina had probably been ruptured at this particular spot, and rendered incapable of performing its functions, and the eye had involuntarily turned inwards, so that a more healthy part of the nervous apparatus might be brought into the axis of vision.

Lastly, it is desirable in these cases to ascertain, if possible, the *condition of the retinal vessels*. If, together with syphilitic opacity of the vitreous, the patient complains of constant headaches, and on examining the eye with the ophthalmoscope, you discover that the calibre of the retinal vessels is diminished, but the colour of the fundus of the eye remains normal, you will have just reason to suspect the existence of syphilitic thickening of the septa between the vessels in the cavernous sinus, and unless this be absorbed, atrophy of the retina must ensue. Contraction of the retinal vessels may be due, either, to atrophy of the retina already established, or to pressure exercised upon them by some force external to the eyeball. We may presume the former cause not to exist, if the colour of the retina is unaltered, and if the walls of the larger branches of the vessels are not surrounded by a line of white and atrophied tissue.

LECTURE IV.

Syphilitic Opacity of Vitreous. Fluid Condition of Vitreous. Opaque Floating Bodies. Muscæ Volitantes. Degenerations of the Vitreous from Poverty of the Blood. Hæmorrhage. Entozoa, and Foreign Bodies in the Vitreous Chamber.

WE were occupied in the last lecture with the consideration of those peculiar affections of the eye, which have lately been shown by Mr. Hutchinson to be due to inherited syphilitic disease. I endeavoured to explain to you, that the morbid appearances may be traced to alterations in the cell-substance of the cornea and vitreous, due to perverted action of the nuclei. The nature of this action we cannot at present comprehend, because we know so little of the laws that govern vital force; but we can watch its effects upon the ex-nuclear material, which becomes developed into a lowly organized fatty substance, in place of being converted into a healthy transparent tissue.

Alterations in the nutrition and physical characters of the vitreous, similar to those already described as the result of the inherited form of syphilis, not unfrequently arise from the *primary constitutional affection*. We have a good illustration of this in a case now under treatment:—

Sreenath Sing, aged thirty-three, contracted venereal

disease some four years ago, followed by secondary symptoms, from which he has suffered more or less up to the present time ; he was salivated three months since without deriving the slightest benefit from the treatment. A year after the chancre had healed, he noticed that his eyesight began to fail, and the dimness of vision has steadily but slowly increased, without his having suffered the slightest pain in the eyes, nor do they appear to have been congested or irritable.

When he first came to the Hospital, his general health was evidently very much impaired : he had a small weak pulse, and was very emaciated ; he complained also of severe rheumatic pains in his limbs ; he was almost completely blind with the left eye, and could barely discern fingers held up before the right one. The tension of both eye-balls was normal, and though the irides acted sluggishly, still no abnormal appearance could be detected in either cornea, lens, or iris. With the ophthalmoscope, I found the vitreous humour of the left eye so densely opaque, that it was impossible to see the optic disc : in the right eye the vitreous was of a hazy, whitish-grey colour, but I could just distinguish the retinal vessels through it. The treatment upon which he was put, consisted of a liberal diet, cod-liver oil, and the iodide of iron. Under this his general health certainly improved, but at the end of a month, there being no perceptible change in the condition of his eyes, I ordered him to commence a course of mercurial baths, and an issue was opened in the skin of either temple.

It would be useless my following out the details of this case from day to day: our patient continued the use of the vapour baths for two months, and at the end of that time, he could see to read No. 4 type, and to transact his business without inconvenience. On examining his eyes with the ophthalmoscope, I found that the left vitreous, though still hazy, had so far cleared as to allow of my seeing the optic disc. The right eye was perfectly healthy, as far as I could discover.

I have already stated, that you will frequently meet with instances of this form of disease among the natives of India, syphilis being very prevalent among them; and unfortunately they commonly fall into the hands of ignorant quacks who starve, and at the same time salivate them most profusely for the cure of venereal disease. But it may probably strike you, if mercury is so useful in syphilis, why is it that the natives are thus often affected with secondary symptoms? At first sight, this fact would appear opposed to the statement I have made, that mercury is the only remedy upon which we can rely with safety for the amelioration of constitutional syphilis. It must indeed be confessed, that we cannot depend on its beneficial effects, unless care be taken to keep the patient's general health in good order while using the remedy; if, on the contrary, he be rapidly salivated and at the same time starved, he naturally falls into a weak and emaciated condition, and the action of the drug upon the syphilitic poison is completely neutralized. This, however, is no valid argument against the judicious use of mer-

cury ; for, by the same reasoning, any ordinary articles of diet might be said to be injurious, because some people are foolish enough to eat and drink too much, and thereby induce diarrhoea and other forms of disease. Although, therefore, the indiscriminate administration of mercury cannot be too strongly deprecated, yet we have frequent opportunities of watching the gradual disappearance of opacities of the vitreous, like smoke before the wind, under a well-directed and judicious plan of specific treatment.

We may gain one piece of useful information from the abuse of this drug among the natives, which is, that although it undoubtedly induces anæmia when combined with a want of proper food, it does not cause caries, and complete degeneration of the animal frame, —effects which have been ascribed to it by those who are opposed to its use under any circumstances. Caries is a comparatively rare disease among the natives ; were it a common sequence of ptyalism, we should certainly meet with more instances of it than we do among our hospital patients.

In the case of Sreenath Sing, the opaque vitreous gradually returned to its state of normal transparency ; but so favourable a result as this by no means always occurs : it often happens that the degenerative process advances, and the *vitreous passes into a fluid condition*. We have two instances of this kind under treatment at the present time ; one of them followed constitutional syphilis, in the other, no such inciting cause of disease existed.

Bunkoo Behary Day, aged forty-one, a jeweller by

trade, came to the hospital on the 10th of April. Eighteen months ago he contracted venereal disease, which was followed by secondary symptoms, and inflammation of the eyes, together with ciliary neurosis and great intolerance of light. His sight, prior to this attack, had been remarkably good; but from that time to the present it has been growing dimmer, and he is now unable to continue his work.

In the left eye, the pupil was found to be closed by a mass of organized lymph. The tension of the right eye-ball was normal, and the pupil, though irregular, dilated and contracted slowly; the vitreous was too opaque to allow of my seeing the optic disc through it; a dull red glare reflected from the fundus of the eye, led me to suppose that the retina, and probably the choroid also, were deeply congested. Our patient would not remain in Hospital, and I lost sight of him for two months, when he again made his appearance. He was now too blind to find his way across the room without assistance, and he complained of dark bodies constantly floating about across the field of vision. On examining the right eye, I found its tension (T—1); the vitreous was in a fluid condition, and a number of black flocculent-looking shreds were observed in it; the instant the eye-ball was turned sharply from one side to the other, these spots were sent whisking and twirling about in all directions.

Behary's general health was in excellent order, and as he now consented to remain in Hospital, I ordered him a mercurial vapour bath twice a week, and two

drachms of cod-liver oil three times a day. The eye was kept carefully closed by a pad of cotton wool with a light bandage over it, to retain it in position.

With the exception of a few days' intermission from time to time, our patient adhered to this plan of treatment, most assiduously, for three months; at the end of which period, he had so far recovered his sight, as to be able to read No. 4 type with ease at ordinary distance. The tension of the eye-ball was normal, and with the exception of a few light, flocculent spots, like *nebulæ*, in the vitreous, and the larger vessels of the choroid being visible through the hexagonal cells of the elastic lamina, I could detect nothing wrong with the eye.

In the preceding case, there was evidence of the vitreous having passed through three stages,—first, the opaque; secondly, the fluid; and lastly, it had resumed its normal consistency. This was a very fortunate termination. When once, however, the vitreous has degenerated into a fluid state, there is always fear of further changes going on, which are likely to end in atrophy of the eye-ball. The support which the healthy vitreous affords the retinal vessels being removed, their delicate walls are apt to give way, and hæmorrhage into the retina occurs. This fragile nervous tissue is often torn through by the effused blood, and irreparable damage thus done to the eye.

The same circumstances favour, though in a less degree, extravasations from the choroidal vessels. When our patient first came to the Hospital, we noticed a dull red reflection from the fundus of his

eye, and I then thought it probable that there was deep-seated congestion of the choroid or retina; and after the vitreous had cleared sufficiently to enable us to see the condition of these parts, the choroidal vessels were found to be in a state of hyperæmia. Under these circumstances, from the coincidence of congestion with a defective support afforded the vessels by the softened vitreous, it seemed highly probable that hæmorrhage might have taken place behind the elastic lamina: this, however, was not the case. Extravasations of blood into the choroid do not, indeed, happen so frequently as we might have expected in cases of this kind, unless complicated with disease of the walls of the vessels.

Simple fluidity of the vitreous does not much affect the sight: I have several patients under my care, who have for some time past been suffering from this condition, and, with the exception of short-sightedness, they have complained of no inconvenience whatever. The impaired vision is caused by the increased refractive power of the dioptric media, and may be corrected to a great extent by concave glasses.* But if, in addition to a fluid vitreous, opaque bodies are also floating about in it, the patient's sight becomes very imperfect, and he is constantly troubled with *muscæ volitantes*.

There is still some uncertainty as to the nature of these flocculent bodies; doubtless their colour is

* These cases must be clearly distinguished from myopia accompanying sclero-choroiditis posterior, in which the vitreous subsequently passes into a fluid state, *Vide* Lecture IX.

heightened by the slight amount of reflection which takes place from them, in comparison with that which proceeds from the congested vessels of the choroid or retina, so that they are seen projected against a bright background; but still, this does not account for their decidedly black tint when examined with the ophthalmoscope. I have had an opportunity, on several occasions, of looking at these bodies under the microscope; they appear to me to consist of degenerated hyaloid, or else of the matrix of the vitreous, with particles of colouring matter attached to them, similar to that contained in the pigment cells of the elastic lamina.

Opacities, and other degenerative changes in the vitreous, are, however, by no means always the result of syphilitic disease. The following case illustrates their occurrence in connexion with a *general impairment of nutrition and poverty of the blood*.

Omesh Chunder Roy, aged thirty-two, by occupation a writer, states that, about five years ago, he discovered his eyesight was gradually becoming defective; dimness of vision, more particularly after sunset, was first noticed, but latterly he has constantly seen opaque spots floating about before his eyes. He is an *anæmic* looking individual, and cannot see to read the largest sized type with his left eye; with difficulty he can decipher No. 4 with the right. I found the cornea, iris, and lens, in both eyes, healthy, the tension of the left being about (T.—1.), that of the right (T. N.). In the former, the vitreous was in a fluid

condition, and a number of flocculent bodies were seen floating about in it; the optic disc and vessels of the retina were indistinctly seen, as through a dense fog. The right vitreous was slightly hazy, but in other respects the eye appeared normal.

The patient was ordered to take five grains of iodide of potassium, three times a day, and he continued this medicine for some time without any apparent improvement; I then gave him cod-liver oil and bichloride of mercury, for two months, with marked advantage. At present, the fundus in either eye appears healthy; in the left, the vitreous has so far improved that the tension is normal, and the optic disc and vessels of the retina can be distinctly seen, although a few flocculent bodies are still noticed in it. The patient can see to read No. 1. type with either eye, the right being perfectly healthy.

In this class of cases it is not advisable to administer mercury. Non-syphilitic opacity of the vitreous commonly arises (excluding cases of sclerochoroiditis) from an impoverished state of the blood induced by malarious influences. I need hardly remark that, among the lower classes of natives, anæmia is a very prevalent disease; and under these circumstances, an attack of fever is likely to cause further deterioration of the blood, and also local congestions of the choroid and other structures; and the vitreous, like the cornea, is prone to degenerate and become opaque. If, then, the opacity of the vitreous is due to an impoverished state of the blood, it is evident that mercury will simply increase this condition. Good

food, quinine, and cod-liver oil are, on the contrary, imperatively called for; medicines of this description will prove as efficacious in these instances, as mercury does in the syphilitic ones. I place great faith in cod-liver oil, arsenic, and strychnia, in such cases. As a general rule, ferruginous preparations do not answer with natives, they are apt to cause irritation of the intestinal mucous membrane, and are not on the whole so successful as arsenic. Cod-liver oil is an invaluable remedy in all these forms of disease.

In giving an opinion with regard to the *myopia* which is met with in conjunction with opacity of the vitreous, it is necessary to exercise considerable caution, in order to prevent mistakes. The patient does not suffer from any pain in the eyes, or from intolerance of light. The external appearance of the eyes is generally healthy. In the early stages of the disease, the impairment of vision is most marked after sunset; but as the opacity of the vitreous becomes denser, the patient's vision grows more dim. These symptoms are, however, common to various other forms of disease, and there is only one way of arriving at an accurate diagnosis, namely, by means of the ophthalmoscope. I have known cases of opacity of the vitreous, in their early stages, mistaken for *hemeralopia*; the symptoms of these two complaints are very similar; but with the ophthalmoscope, the latter is distinguished by negative characters, there being no condition of the fundus of the eye pathognomonic of hemeralopia, that I am aware of. The opaque condition of the vitreous,

on the other hand, may be recognised in its earliest stages.

Occasionally, colourless flocculent bodies are seen stretched across the vitreous chamber, like a thin veil in front of the retina. These consist, probably, of the cellular structure of the vitreous, rendered opaque by degenerative changes, its nuclei becoming surrounded by a fatty material, which is the direct cause of the haziness observed with the ophthalmoscope. Von Graefe has removed *false membranes* of this kind by passing two needles into them, and breaking them down in the same way as Mr. Bowman directs for the removal of an opaque capsule from behind the pupil. Small clots of blood, from which the colouring matter has been absorbed, produce an appearance in the vitreous, somewhat similar to that of the colourless opacities above noticed.

Crystals of cholesterine are sometimes to be seen floating about in the vitreous, producing the condition known as *sparkling synchysis*. With the ophthalmoscope, they appear like a multitude of grains of gold-leaf, whisking about in all directions, when the eye is turned quickly from one side to the other. The cholesterine generally arises from degenerative changes taking place in a dislocated lens; a great part of the lenticular matter becoming absorbed, the insoluble cholesterine is left in the vitreous chamber, causing the above described remarkable appearance.

It is by no means uncommon to meet with cases in which *an effusion of blood into the vitreous* has taken

place, in consequence of a blow, or else from rupture of diseased vessels in the choroid or retina. For instance, a person is struck on the eye, and independently of chemosis, he finds that he cannot see clearly, the field of vision being obscured by a reddish haze. With the ophthalmoscope, the vitreous will appear of a diffused, bright scarlet colour, the optic disc being dimly seen through it; spots of ecchymosis will also be observed in the retina. Under ordinary circumstances, the effused blood is rapidly absorbed, and the vitreous speedily returns to its normal state of transparency; but if the hæmorrhage has been at all profuse, a clot may be formed in the axis of vision, rendering the patient more or less blind. The fibrine of a clot of this kind usually undergoes a process of fatty degeneration, and gradually becomes absorbed. You should be very guarded in giving a favourable prognosis in such a case, for the clot may sometimes remain *in situ*; and should it even disappear, you may subsequently discover that considerable injury has been done to the retina, and that its functions have become permanently impaired.

There can seldom be any difficulty in forming a correct opinion with respect to the nature of a lesion of this kind; for if the hæmorrhage has occurred in consequence of an injury, the impairment of vision will have originated at the time the blow was inflicted; but if from the effects of disease, the history and symptoms, together with the ophthalmoscopic appearances of the part, will sufficiently determine the diagnosis. It is possible that a malignant growth in

its earliest stages, or a separation of the retina from the choroid, might be mistaken for a clot of blood in the vitreous chamber; a little care, however, bestowed on the inspection of the part with a binocular ophthalmoscope, and with sunlight to illuminate the eye, will speedily remove any doubt there may have been on the subject. If the case should be one of malignant tumour, the aspect of the excrescence can hardly be mistaken, and the disease will make rapid progress, the pain and tension of the eye-ball, combined with the ophthalmoscopic appearances, indicating the serious nature of the mischief going on in the eye. By means of the lateral method of examination, the tumour may generally be clearly defined, as soon as it projects slightly beyond the plane of the fundus of the eye.

It is, of course, of the greatest importance to recognise the existence of a malignant growth as soon as possible, for, by promptly removing the diseased globe, the progress of this fearful malady may be stayed; but the eye-ball should be extirpated early, since it is useless interfering after the disease has advanced beyond the sclerotic. In doubtful cases therefore, whether the patient's sight is impaired or not, if you have reason, after careful inspection of the parts, to believe that a malignant tumour is forming within the globe, it is far better to remove the eye. On the other hand, if the appearance noticed is due to a clot of blood, you must leave nature to take her course; you cannot hasten its absorption, and might do much harm by useless interference,

Entozoa are occasionally found in the vitreous chamber, the cyst in which they grow being attached to the retina or choroid. Plate III., Fig. 3, is a copy from one of Liebreich's plates, showing a cyst of this kind. He states that the entozoon is first developed behind the retina, and having perforated it, enters the vitreous chamber. A contracting and elongating movement of the cyst may be clearly observed, though the parasite itself cannot be distinctly seen, on account of the opaque sheath in which it is contained. After a time the cyst bursts, and the head and neck of the creature may then be defined. It is, however, remarkable, that up to this stage of the disease, the parasite appears to cause no inconvenience beyond the wavy motion of the cyst in front of the patient's retina; there is no pain or irritation in the eye. Liebreich relates a case of an entozoon in the vitreous, which he not only diagnosed, but successfully removed; passing a pair of canular forceps into the vitreous, he seized the parasite and withdrew it from the eye. During the operation, Liebreich contrived to illuminate the vitreous with an ophthalmoscope which he fixed to his forehead, enabling him to use both his hands, and thus accomplish the necessary manipulation successfully. Cases of a similar kind have from time to time been recorded; in some, the lens was first extracted, and subsequently the parasite removed; these operations, however, have not been very successful, and Liebreich's plan of treatment appears to be best adapted for the cure.

In many parts of India *filariæ* are frequently found

in the eye of the horse; the entozoon is seen in the anterior chamber, moving about like a thin white thread in the aqueous humour. In the early stages of the disease, it excites no irritation or inconvenience, but ultimately inflammation and ulceration of the cornea occur, and the contents of the eye, together with the parasite, are evacuated. This may, however, generally be averted by puncturing the cornea, and allowing the aqueous to gush out through the aperture, and with it the entozoon.*

You will find the ophthalmoscope of the greatest assistance in enabling you to estimate correctly the position of *foreign bodies in the vitreous*. A remarkable illustration of this is to be found in the sixth number of the Ophthalmic Hospital Reports; the case was one in which a small particle of steel had penetrated the upper eyelid and sclerotic, and entered the vitreous chamber. The patient was under Mr. Dixon's care, and on examining the eye with the ophthalmoscope, he was enabled to detect the foreign body behind the lens. Mr. Dixon removed it by perforating the sclerotic at its lower and outer part, and passing a pair of canular forceps into the vitreous, with which he caught hold of the foreign substance and so withdrew it from the eye. The patient made a rapid recovery.

It is impossible to lay down special rules for your guidance in treating accidents of this kind; almost

* In the twenty-sixth number of the *Indian Annals* you will find recorded two cases of *filaria* found in the human eye, which occurred in my practice.

every instance you meet with will require some peculiar manipulation, and you will have to exercise your ingenuity and mechanical skill in contriving the most appropriate means of accomplishing your purpose. With the ophthalmoscope, any foreign body may be clearly defined, if sought for soon after it has penetrated the vitreous chamber; but after remaining there for some time, it is likely to become hidden by a covering of false membrane. The following case now under my care, is an instance in point:—

Mr.—, last cold season, was struck in the eye by a No. 3 shot, which penetrated the lower part of the sclerotic. He gradually lost his sight, and I was consulted regarding the case, some two months after the accident had occurred. I found that he was quite blind with the right eye, the pupil was dilated, and the vitreous hazy, the sclerotic and conjunctiva were slightly congested, (T. N.), the patient suffered no pain in the eye. On examining it with the ophthalmoscope, I found the retina was detached from the choroid, and at the bottom of the vitreous chamber the shot could be seen incased in a whitish mass. As there was no possibility of restoring the sight, and as the foreign body did not appear to cause any irritation, I directed my patient merely to keep the eye closed with a pad and bandage, and after a short time the conjunctival congestion entirely disappeared.

Unfortunately, in this country, you will constantly meet with instances of a foreign body in the vitreous, in the shape of a dislocated lens. You are aware, that the barbarous practice of reclination or depression, as

it is called, is still much in vogue among the natives in cases of cataract; and without just now commenting further upon the practice, I will suppose a patient brought to you in great agony, with his eye violently inflamed from a recently performed operation for depression, (*Vide* Plate I., Fig. 1). On examination, you will see the opaque lens bobbing about behind the iris, and it will be necessary to decide at once as to what treatment it is best to pursue under the circumstances. If the lens has been depressed within a week or so, and the patient has still some perception of light, you should attempt to save the eye by removing the lens by linear extraction. You may experience some difficulty in accomplishing this, on account of the adhesions which will probably have formed between the iris and lens. If the dislocation has existed for more than fourteen days, and the patient is suffering from considerable pain in the eye, and has lost all perception of light, it is better to cut through the cornea at once, and turn out the contents of the eye-ball; any palliative treatment you may adopt, must expose the patient to the risk of losing the other eye from sympathetic irritation; and there is no chance of the diseased one being, in future, any thing but a source of annoyance and pain, so that the sooner it is destroyed the better.

LECTURE V.

Hyperæmia of the Retina. Transient and Chronic Forms. Cases depending on Mixed Causes. Malarial Cases. Treatment. Fatty Degeneration of the Retina. Acute Inflammation of the Retina.

It is my intention to devote the present and following lectures to the subject of the *diseases of the retina*. In so doing, it will be convenient to consider, first, the phenomena of hyperæmia of the retina, and afterwards the changes induced by inflammation; and lastly, I propose to describe various diseases which cannot be brought under either of these heads.

You will understand from the anatomy of the parts, that, in the healthy eye of the native, it is impossible to see any of the structures posterior to the epithelium of the elastic lamina with the ophthalmoscope; consequently, if the vessels of the choroid are visible, the hexagonal cells of the elastic lamina must either have been altogether removed, or else pushed on one side; in fact, so long as these cells remain *in situ*, any pathological changes we may observe in the fundus of the eye, must be situated anterior to the elastic lamina. There can be no doubt, therefore, that in consequence of these structural peculiarities, the surgeon practising amongst the people of India, possesses singular advantages for

studying the diseases of the retina; the dense brown layer of epithelium, which covers the elastic lamina, forming a well-marked background, against which the structures anterior to it are seen projected, so that alterations in their thickness, density, and so on, may be recognised with comparative ease. Serous effusions, for instance, in connexion with the retina, and other similar conditions, which in the European it is difficult to distinguish, on account of the brilliant reflection from the choroid eclipsing that from the retina, may be readily appreciated in the eye of the native.

Hyperæmia of the capillaries of the retina may be a very transient affection, depending simply on overexertion of the eye, or upon a deranged state of the stomach; under these circumstances it passes away so rapidly, that it is not likely to attract the attention of either the surgeon or patient. But whatever the exciting cause of the hyperæmia may be, should it remain, and thereby induce chronic congestion of the capillaries, the most serious results may follow. You will almost invariably find the retina more or less œdematous in cases of hyperæmia, unless the congestion be of a very transitory nature; and if you discover that these conditions of capillary congestion and œdema co-exist, you may be sure that the bounds of health have been passed, and that disease has commenced. In such cases, although the congestion and its consequences may entirely disappear, leaving the parts in a normal state, still it is always necessary to be on your guard, remembering that the effusion,

though harmless in itself, has taken place in a most fragile and delicate tissue, and one which may readily be destroyed.

I have already explained to you why the healthy retina of the native appears of an uniformly bright slate colour, when examined with artificial light, except where the central artery and vein meander through it. These vessels may be traced up to their finest ramifications, but the capillaries cannot be seen with the ophthalmoscope on account of their minute size; nor does the blood they contain, under ordinary circumstances, redden the fundus of the eye. Consequently, if the retina appear of a crimson hue, however slight the tinge may be, you may be certain that there is something wrong, although the changes which have occurred may not amount to actual disease. For instance, if the pupil has been dilated with atropine, and the patient subsequently exposed to the glare of the sun, the irritation thus induced will cause temporary hyperæmia and redness of the retina. It is advisable, therefore, to delay putting atropine into a patient's eye, until just before making an ophthalmoscopic inspection; and never, after applying it, turn him out into the sun, telling him to come again for examination the next day, for it will then be impossible to judge how far any alteration in the vascular condition of the retina is due to the effects of disease, and how far to the irritation induced by over-exposure to light. Excluding, however, exceptional causes, all due precautions having been taken to prevent their occurrence, the above rule holds good, and any tinge

of red observed in a native's retina, indicates a departure from health.

It is well to examine both eyes, so as to compare the state of one with the other; but, unlike that of the European, the fundus of the native eye is of the same colour in all individuals, unless altered by disease; and although the eye of the people of Southern India may be darker than that of the Bengalee, still, whenever the cells of the skin contain black pigment, the epithelium of the elastic lamina of the choroid will likewise be black, or very nearly so. The difference, therefore, between the hue of this structure in various classes of natives, varies only from a dark to a light slate colour when examined by artificial light; if sunlight be employed, the tint is rather browner.

Hyperæmia of the capillaries often runs a *chronic course*; and this I consider to be one of the most insidious and dangerous forms of disease to which the retina is liable. It may arise under various circumstances, but in all cases there is some peculiar blood *dyscrasia*, which is the latent cause of the mischief. This may be roused into active operation by various exciting causes, as for instance *over-work* in a dark room; and we consequently find that instances of the kind are very common among embroiderers and tailors in this city. You are aware that these people frequently sit up at night working by the light of an oil-lamp, the flame of which is hardly equal in brilliancy to that of a farthing rush-light; and if it be remembered that hundreds of

human beings are thus employed, their general health being at the same time impaired by malaria, want of fresh air, and low living, we cannot wonder at meeting with cases of hyperæmia of the retina amongst them.

The train of morbid phenomena commences with the demand for extra nutrient material, caused by the waste induced from overwork to which the retina is exposed; and though we cannot appreciate the changes that are going on in its nervous elements, we may judge accurately of their activity by the congested appearance of the capillaries. If the exciting cause of the hyperæmia continue, one of two results must follow: either the retina becomes atrophied, and the supply of blood being no longer required, the hyperæmia gradually ceases; or else, the congestion continuing, superabundant cell-proliferation is induced, ending in the formation of organized adventitious tissues, which being intermingled with the delicate nervous elements of the retina, entirely destroy its sensibility.

Another source of retinal hyperæmia, is mechanical obstruction induced by pressure upon the orbital vessels; but I shall treat of this form of disease more fully in a subsequent lecture, and will not therefore dwell on it now. A more frequent and important cause of this condition is to be found in the influence of *malaria*. This may operate immediately through the blood, producing changes in its composition, which render it unfit for the nourishment of the tissues, delaying its progress through the capillaries, and so

giving rise to local congestions; or else the poison, after entering the circulation, acts directly on the sympathetic nerve, and so indirectly on the vascular system. You are aware that division of the sympathetic in the neck induces hyperæmia of the retina and other parts which the injured nerve supplies; it may be by some such paralysing influence, which the malarial poison exercises over the sympathetic, that local congestions, such as we are now considering, are produced. However this may be, there can be no doubt of the fact, that we frequently do meet with cases of hyperæmia of the retina among persons who have imbibed a large dose of this poison.

We constantly have cases under treatment, which illustrate the effects of these *combined influences* in inducing capillary congestion of the retina. The following is an instance:—

Kidernauth Dutt, aged thirty-six, an embroiderer by trade, states that he has tried his eyes excessively for a long time past, working for hours together at night, by the light of an oil lamp. With the exception of attacks of fever, from which he has suffered at various times, he has enjoyed good health; he has never had syphilis. This man's eyesight was remarkably good until within the last eighteen months, when he began to experience some difficulty in seeing clearly to thread his needle, and thinking that he was becoming short-sighted, he took to wearing spectacles. These did not, however, improve his sight; and he began to complain of an aching pain, extending from the right eye over the temple. The sight of that eye became

rapidly dim, and he cannot now distinguish light from darkness with it; and as the left eye grew hazy also, he came to the Hospital for treatment. I found the tension of the right eye-ball slightly increased, that of the left normal; the dioptric media in both were healthy.

On examining the *right* eye with the ophthalmoscope, I observed that the retina was of a uniformly greenish-grey colour, including the optic disc (*vide* Plate V. Fig. 3); the larger branches of the central artery and vein could partly be seen in front of the opaque mass, their calibre being only slightly diminished. The fundus of the *left* eye was of a pale rose colour, the nervous tissue being hazy and swollen from serous exudation in its deeper layers; the artery and vein were normal in calibre and appearance. The hyperæmia here was evidently confined to the capillaries, the congestion extending to the vessels of the optic disc, so that its position could only be dimly seen. After the pupil had been fully dilated with atropine, several opaque spots were observed in the substance of the retina; and I think we may fairly conclude, that the changes noticed in the left eye exhibited an early stage of the disease which had run its course, ending in the entire destruction of the patient's sight, in the right eye.

The more carefully you study these cases, the plainer it becomes that the capillaries alone are affected, the circulation in the larger vessels being perfectly normal. In this instance, the overwork which the retina had been called on to perform, had caused

an increased demand for reparative material, and here probably, was the starting-point of the hyperæmia. This condition, however, continuing, the bounds of health were passed; the line of demarcation being determined by effusion into the retina, and an opaque condition of its nervous elements. This is a most important point to bear in mind; for when these conditions are present, disease has commenced, and will surely progress to an unfavourable termination, unless stayed by appropriate treatment. I am very doubtful, however, if the overstraining to which this patient's eye had been exposed, was in itself sufficient to account for the important changes above noticed; the influence of the malarial poison from which he suffered, and which evinced its presence in his system from time to time by attacks of ague, must also, I think, be taken into account. This had, no doubt, induced a permanent dyscrasia of the blood, and, as I have already said, such a condition appears to be an essential element in the history of these retinal cases. It need not be due to malaria, but may arise from disease of the kidneys, or other causes, the effect is nearly the same; and it is owing, I believe, to this fact of the existence of blood-poisoning, that the congestions are so permanent, and the results so frequently unfavourable.

In the left eye of this patient, I observed that the organized effusion had only been partial, although the congestion and œdema were general. It is necessary to be particularly careful, in such cases, in making an examination of the fundus of the eye, or these

scattered points of effusion may be overlooked ; and the inexperienced surgeon is apt to conclude that the case is simply one of congestion, and to dismiss the subject without further consideration.

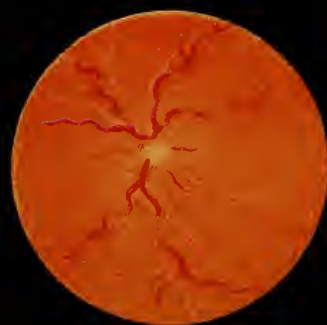
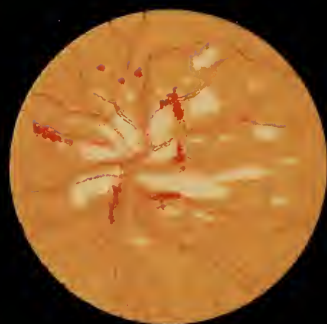
In this instance, the changes that had been going on had progressed so gradually, that the patient had experienced very little *pain* in the eye ; there had probably been but slight, if any pressure upon the choroid or sclerotic, the vitreous yielding to the distending force of the swollen retina. Pain is by no means a characteristic symptom of hyperæmia of the retina ; the disease often runs its course from beginning to end, the patient only complaining from time to time of a slight aching pain in the eye.

With regard to the treatment in this case, two things had to be taken into account,—the general dyscrasia from which the patient was suffering, and the overwork, which had been, no doubt, the exciting cause of the local affection. It was therefore important, in the first place, that the patient should give his eyes perfect rest, and he was directed to keep them closed during the greater part of the day, by means of a pad and bandage tied over them. Secondly, he was ordered a liberal diet, and strychnine with citrate of iron and arsenic ; and lastly, he was recommended change of air to his native village. He followed out this plan of treatment, varying his medicine a little from time to time, and at the end of two months, I found that the disease in the left eye had entirely disappeared ; in the right eye no changes had taken place.

Newly formed cell-formations may become entirely absorbed in cases of this kind, provided organized tissues have not actually been developed from them; but as it is impossible to distinguish with the ophthalmoscope how far these changes have proceeded, it is well to administer iodine and arsenic for a time, in the hopes of their doing good. But if, after employing these drugs for a month or two, you find no perceptible amelioration of the symptoms, it is better to discontinue all medicine; your prognosis, however, must, under these circumstances, be anything but favourable, as it is improbable that any ultimate improvement will take place in the condition of the eyes.

In the preceding case, we had an instance of retinal hyperæmia arising from mixed causes; but it is important you should know that *malarial influences alone* are capable of producing the disease, and I have selected the two following cases, from those which have recently been in the Hospital, as good illustrations of that form of the complaint.

You will remember I stated that malaria may be supposed to affect the capillary circulation in one of two ways: either by primarily poisoning the blood, and so directly deranging the material interchanges between it and the tissues; or indirectly, through the vaso-motor nervous system. I may add further, that the sympathetic is known to exercise an important influence over the glandular functions, and it may be by modifications thus produced, more especially in the secretions of the liver and kidney, that a secondary



poisoning of the blood takes place, and becomes an additional cause of local congestion. But whether any, or all of these influences combined, are the direct causes of hyperæmia of the retina, I believe we may assert most positively, that such local congestions do frequently occur in persons subject to malarial influences, and apparently from no other cause.

Comol, aged thirty-five.—This patient has been suffering from intermittent fever for the last three weeks; the paroxysms come on every day about eleven o'clock; during the last five days she has had, in addition, considerable pain in the right side of the head (hemicrania), and the sight of the right eye, which had previously been good, has become very dim. She is a stout and apparently strong person, and, with the exception of occasional attacks of fever, like the one she is now suffering from, she has always enjoyed excellent health. There were no indications of her liver or spleen having been affected, nor could I discover any evidence of hyperæmia existing in any of the organs of the body, excepting the retina. On examining the right eye, I found its tension normal, and the dioptric media healthy, the pupil contracted, and only dilating after long exclusion from the light. The retina, including the optic disc, was of a rose colour, and the central artery and vein appeared of normal calibre; these parts, in fact, were perfectly healthy, with the exception of the capillary hyperæmia, and the swollen and slightly hazy appearance of the retina induced by œdema. (*Vide* Plate VI. Fig. 1.) The sight of this eye was

considerably impaired; she could just see, however, to count fingers held up before her face. I gave her an emetic, followed by a full dose of opium, and the eye was carefully bandaged, so as to exclude the light from it. On the following day, she was ordered arsenic and opium, and after a week's treatment the pain in the head subsided; there was no return of the fever, and in the course of fourteen days the hyperæmia of the retina had disappeared, and the patient's vision was as good as it had ever been.

Even in mild cases of hyperæmia, you will invariably find that some amount of serous effusion has taken place into the retina, which causes it to appear soft and swollen, exactly as the conjunctiva does under similar circumstances; but unless the retina itself becomes decidedly opaque, the effused serum may be rapidly absorbed, and the parts return to their normal condition. This was what occurred in the case just related; the second was of a more serious kind:—

Mohesh Chunder Ghose, a shopkeeper, aged twenty-seven, came to the Hospital on the 6th of September; he stated that, up to within the last few days, his eyesight had been perfectly good, and that, although he had suffered from frequent attacks of intermittent fever, his general health was not impaired. Fifteen days previously, he had been seized with ague, after which he noticed a hazy appearance in the field of vision; on the following day he had an aching pain over both eyebrows, which was augmented during the paroxysm of fever, the dimness of sight increasing

considerably after the attack. He had no enlargement of the liver or spleen, but was rather anæmic.

When I first saw this man, he could with difficulty count fingers held up before the left eye; with the right he could see to read the largest-sized type. The tension of the left eye was T.+1, that of the right T. N.; the pupils in both eyes were contracted, and they dilated very slowly when excluded from the light; the dioptric media were normal. In the *left* eye, I found the retina was infiltrated with an opaque matter, in colour and appearance resembling pus; it covered not only the retina, but also the optic disc; some of the retinal vessels could be seen coursing over its surface, and then dipping down again to become hidden in its substance. There was no enlargement of the veins, and they presented a totally different appearance from those seen in the cases of acute inflammation which I shall presently bring to your notice. In the *right* eye, there was capillary hyperæmia, the optic disc and fundus of the eye being of a rose colour; the central artery and vein were of normal calibre, and the œdema of the retina was particularly well marked. I could not persuade this man to remain in the Hospital, and as he soon ceased to attend, I lost sight of him.

In these cases, I pointed out to the class the evident contrast in colour which hyperæmia offers when compared with inflammation of the retina. (See Figs. 1 and 3 of Plate VI.) In the former, it is of an uniform rose colour, with œdema; in the latter, the colour is of a vermilion hue, and there are almost invariably a

number of spots of extravasated blood scattered over the fundus of the eye; besides which, the veins in inflammation are always enlarged and tortuous, but in hyperæmia they are scarcely if ever altered in size.

These are only two of very many instances of hyperæmia of the retina we have seen lately, and I have studied cases of a similar nature in various parts of India during the past ten years—they are particularly common in malarious districts, as, for instance, among the inhabitants of the Nepaul Terai. The congestion may subside entirely, without leaving the slightest ill effects; it often, however, ends in partial or total blindness, and it is on this account that I am so anxious to impress upon you the importance of what might otherwise appear to be a slight affection. The only other disease with which you are likely to confound this form of hyperæmia, is syphilitic inflammation of the retina, which frequently runs a slow and insidious course, and is unaccompanied at first by any marked symptoms. The disposition, however, which syphilitic hyperæmia and inflammation appear to have to localize themselves, even in a small space like the retina, so that a portion of that structure may be found disorganized, whilst the rest of it is healthy in appearance and function, is very remarkable. Attention to this feature, and to the history of the case, will generally lead to a correct diagnosis.

Edema of the retina is an almost constant result of hyperæmia. It may be recognised by the swollen

and slightly opaque appearance of the part, the opacity being due in its early stages simply to distension of the nervous tissue, with serous effusion: at a later period, the retina becomes structurally altered, after which it never perfectly regains its normal state, although it may recover its functions to some extent. It is remarkable, that in simple œdema, the rods and bulbs of the retina are seldom destroyed. We know how very soon these delicate structures become injured, if placed in contact with water or any other fluid: if the retina be removed from a fresh eye and placed in the serum of blood, the rods become speedily broken up, and the whole of the nervous elements are altered and destroyed; and yet they seem to be very frequently bathed in serous effusions during life, without any apparent injury. Mr. Bowman accounts for this fact on the general ground, that living structures are not amenable to the same laws of change as after death. These serous effusions usually take place in the posterior layers of the retina, and this, probably, is to be explained by the position and functions of the epithelium of the elastic lamina. Though the rods of the retina are little affected, there can be no doubt as to the fact of the epithelium being greatly influenced by these effusions; for I have seen the cells almost completely destroyed, the absorption of serum apparently causing them to degenerate and break up. Indeed, the epithelium of the elastic lamina may be almost entirely removed, and the vessels and stroma of the choroid exposed, and yet the retina still perform its functions.

You might naturally expect, from the foregoing considerations, to meet with cases, in which the retina has become detached from the elastic lamina by serous effusion, especially when the epithelium of this layer has been destroyed; but, as far as my experience goes, such is seldom the case. I shall enter more fully upon the symptoms and treatment of detachment of the retina in my next lecture; and I only refer to it here in order to remark, that it is not a common result of hyperæmia. I have seen the retina so œdematous as to bulge forward into the vitreous, especially at its lower part, but I do not think there has been any actual separation between it and the choroid under these circumstances: the opacity of the retina has not been sufficiently marked to lead me to suppose that such was the case, and the sequence in several instances has been the complete absorption of the effusion, and the perfect restoration of the functions of the retina.

It only remains for me to say a few words on the general *treatment* of hyperæmia of the retina, and of the benefit which may be expected from it.

You may perhaps fancy that I have already dwelt too long upon this subject of hyperæmia; but my reasons for doing so are, that the disease is one of common occurrence, and is very likely to be overlooked; moreover, elementary and apparently unimportant changes in the retina, and other tissues of the body, are those which it behoves us to study most minutely. A case of retinitis, or of inflammation of the lungs or liver, must unavoidably attract the notice of the

most superficial observer. But it is not from these acute forms of disease that our patients' eyes or lives are commonly lost: the victims of acute inflammation are but few, compared with the number of those who suffer from perverted nervous action or mal-assimilation; and amongst the diseases connected with these conditions, hyperæmia of the capillaries of the retina must be placed.

The disease may generally be prevented from running on to the destruction of the eye, if noticed in its early stages; but in order to succeed in arresting it, you must first endeavour to form an accurate opinion of the constitutional dyscrasia which is usually the primary cause of the disease, and apply your remedies accordingly. The next point you will have to bear in mind is, that as light is a certain and constant stimulant of the retina, it must be excluded from the eye when in a state of irritation; for this purpose, a pad of light cotton wool should be applied over the eyelid, and kept in place by a bandage. If the patient be suffering from the effects of malaria—and there are few of us in India who are not being gradually poisoned in this way—tonics and arsenic should be administered; occasional doses of quinine may be useful, if there is actual ague. I am convinced, however, that an immense deal of harm is done to eyes with over-doses of quinine. When I first came to India, I was under the most heroic of all quinine heroes; two scruples, and even drachm doses, were administered till the poor patient became blind and deaf. Nor are these the worst effects of

over-doses of quinine,—in persons affected with fatty hearts almost instantaneous death may be the result; indeed I have seen cinchonism carried to this fatal extent; it seems, in fact, to have usurped the place of the old system of blood-letting and mercury. Formerly, those remedies were resorted to upon all occasions; directly a man was attacked with fever, a vein was opened, and calomel and antimony given *ad libitum*, and in the present day, quinine is sometimes administered in the same indiscriminate manner. Fortunately for our patients, a very large quantity of it is thrown out of the system by means of the kidneys, bowels, and skin, otherwise the temporary blindness, and other injurious effects of over-doses of quinine, would be far more permanent. If you watch the action which a large dose of quinine exerts on the vessels of the retina, you will notice that they are, at first, diminished in calibre, and this condition lasts until the influence of the drug is about to pass off, when hyperæmia is excited and continues as long as any effects of it remain. It appears, then, that malarial influences give rise to congestion of the capillaries of the retina, and that quinine in large doses augments the hyperæmia, and if continued, leads to permanent impairment of vision.

In conclusion, I may say, generally, that one or two emetics, followed by a full dose of opium at bedtime, and a mixture containing arsenic and aconite, will be all that is required in the majority of these cases; mustard poultices over the abdomen are also useful, probably by acting on the nerves and in-

fluencing, directly or indirectly, the sympathetic system. There is no question as to the great importance of our overcoming the hyperæmia of the retina as soon as possible, and the above remedies, according to my experience, together with change of air, if practicable, will be found the most valuable means we possess for this purpose. They should, however, be continued for some time after the actual disease has disappeared; for the malarial poison sometimes works in so insidious a manner, that it is impossible to detect its existence in the system, and this latent influence is hardly less detrimental than its operation in the more marked cases of hyperæmia.

Fatty degeneration of the retina sometimes follows malarial hyperæmia. I have watched instances of this description for some years past, and always considered them as analogous to the fatty degeneration of the muscular or secreting organs of the body, which we notice in persons exposed to malarial influences. Pathological changes of this kind, are by no means confined to cases of the peculiar dyscrasia induced by malaria; we meet with similar morbid conditions of the retina in Bright's disease of the kidneys, and in alcoholic poisoning, brought about, no doubt, in the same way, by alterations in the blood, which render it unfit to supply healthy nutrient material to the tissues; and hence the degeneration and death of their elementary parts.

The following is the course which these cases commonly take. At their commencement, we notice

the presence of hyperæmia of the retina, together with the œdema which so constantly accompanies it; the latter tending, no doubt, mechanically to separate the elements of the tissues from the vessels, and so interfere still further with the natural interchange of material going on between them and the blood, which has been already impaired by the faulty composition of the latter. We next observe small white spots in the substance of the retina; they are first seen near the optic disc, and gradually increasing in number and size, they at length coalesce, and form large white patches, which look exactly like what they really are, namely, spots of fatty matter, taking the place of the proper elements of the retina. The larger retinal vessels do not appear to be primarily involved in the disease; but ultimately, they become surrounded by a soft and degenerate structure, which probably breaks down (as in the case of white softening of the brain), the walls of the vessels give way, and hæmorrhage occurs; a patch of effused blood is then seen to occupy the space of the diseased tissues. But as these extravasations do not all take place at once, we find at one point a blotch of blood, of a more or less scarlet colour, and at another, the shining white spots of fatty matter remaining unaltered; perhaps a few of the smaller vessels may have given way also, producing little specks of extravasation, which are scattered throughout the degenerated portion of the retina. (*Vide* Plate VI. Fig. 2.)

Liebreich considers this condition to be a complication peculiar to Bright's disease, but I hardly think

this can be the case. I had noticed, and made drawings of this form of fatty degeneration, prior to learning the views which Liebreich entertains on the subject; and if the condition of the eye I have described above, be the same as he has depicted in Plate IX. of his Atlas, it is certainly to be met with under other conditions than those caused by disease of the kidneys.

With regard to the *treatment* and *prognosis* in a case of this kind, the latter must generally be most unfavourable. If depending on malaria, you may entertain some hopes of eradicating the poison from the system, and thus of stopping the further progress of the disease; and with this intention, it would be well to put the patient on a long and steady course of lactate of iron and arsenic. Iron certainly does good in cases of this description, if it can be tolerated, but a prolonged use of it is necessary. Of course, the structural changes which have already taken place, are utterly beyond the remedial power of all therapeutical agencies; the delicate nervous elements of the retina having been destroyed, no subsequent process can possibly restore them to their former condition.

Acute inflammation of the retina occurs amongst people of all ages and classes; it may arise from the effects of an injury, or from idiopathic causes. If the retina be primarily affected, the inflammatory action is almost always confined to this structure, and it seldom happens that both eyes suffer at the same

time from this form of disease. Retinitis generally commences with a throbbing, aching pain in the eye-ball and temple; after a few days the pain increases, and is often very severe indeed; the patient also suffers from intolerance of light and lachrymation, and from the commencement of the attack he complains of more or less dimness of vision. As the disease advances, these symptoms increase, and the patient may become unable to distinguish light from darkness with the affected eye. The tension of the eye-ball is generally slightly increased. The dioptric media remain transparent throughout the early stages of uncomplicated retinitis; in chronic cases, or when the choroid is affected, the lens and vitreous become hazy. The vessels of the sclerotic and conjunctiva may be congested, but this is a very uncertain symptom, and unless in traumatic retinitis, is not often observed.

I need hardly say, that the above symptoms are insufficient for the purpose of diagnosis, and it will require considerable quickness and dexterity on your part to obtain a satisfactory view of the inflamed retina with the ophthalmoscope, on account of the inability of the patient to bear the light; the inspection, therefore, must be made quickly, as you have no right to expose these cases to a prolonged examination. The flame of the kerosine lamp, turned down to its lowest point, will be the best source of illumination we can employ; in fact, as a general rule, it is well always to commence an ophthalmoscopic examination with a low illuminating power, and gradually to

increase its intensity, whether artificial or sunlight be employed.

In acute retinitis, the fundus of the eye, including the optic disc, is of an uniform deep scarlet colour (unless hæmorrhage or some other complication is present); the vessels of the papilla being deeply congested, the disc itself cannot be distinguished, and its position can only be determined by the point of entrance and exit of the large vessels of the retina. The central artery of the retina is usually of normal calibre, but the vein is remarkably tortuous, and very much congested; it appears to coil round upon itself, so that at one turn of the spiral it seems to be larger than at another. A venous pulse may generally be observed in these enlarged vessels. (*Vide* Plate VI. Fig. 3.*) The retina itself is swollen and œdematous; and, if carefully examined, faint whitish streaks may be seen radiating in all directions from the situation of the optic disc towards the ora serrata. These faint whitish markings are formed by the nervous elements of the retina becoming puckered up, in consequence of the effusion and the congested state of its vessels, which tend to drag it from its attachments; in the same way as a cushion, inflated with air, becomes wrinkled from the point at which pressure is made upon it with the finger. These markings upon the retina are, however, very faint, and it is not at all essential to see them for the purpose of diagnosis,

* This figure is a reduction from Ed. Jaeger's *Pathologie des Auges*, Taf. XI.

as the disease may be at once identified by the general appearance of the fundus of the eye. The epithelium of the elastic lamina being entirely concealed by the inflamed retina, the fundus of the native's eye appears of precisely the same colour as the European's, when affected with retinitis.

This disease may terminate in resolution, or the inflammatory action may become chronic; but even then, the retina may again assume a healthy appearance, provided that neither in the acute nor chronic form of the disease, permanent damage has been done to its structure. Among the accidents which may thus interfere with a favourable termination, hæmorrhage is the most common. Extravasation of blood may occur at any stage of the disease; and though the blood may become absorbed, still the delicate nervous tissue is generally more or less damaged. Adventitious cell-formations are common in retinitis, and if they become organized, the functions of the retina are of course destroyed in the situation of the newly-formed tissue. Lastly, suppuration may occur as a consequence of inflammation; the only cases, however, in which I have seen this accident happen, have been those in which the retina has been kept in a chronic state of irritation by a foreign body, such as a dislocated lens, moving about over its surface.

If, after acute retinitis, resolution should fortunately take place, we notice that the appearances before described gradually disappear, the redness of the fundus of the eye subsides, and the vessels return to their normal calibre; but I have never seen a case of in-

flammation, in which, if the epithelium of the elastic lamina has been destroyed, it has again assumed its healthy appearance; and consequently, the vessels of the choroid may frequently be seen when all active changes have subsided. As the inflammation passes off, the pain and intolerance of light grow less, and ultimately the patient regains his vision, which may in time become almost as perfect as it was before the attack.

LECTURE VI.

Retinitis, continued. Treatment of the Acute Form. Chronic Inflammation of the Retina. Accidents of Retinitis. Extravasation of Blood. Effusion of Lymph. Suppuration and Atrophy. Syphilitic Retinitis. Detachment of the Retina.

WE resume to-day the subject of the diseases of the retina. I concluded my last lecture with a description of *acute retinitis*, and I must now proceed to speak of the *treatment* of that affection.

Since, with the exception of traumatic cases, the disease almost always depends upon constitutional dyscrasia induced by malaria, or some such poisonous influence acting on the blood, your efforts must be primarily directed towards eradicating these deleterious agents from the system, and you will then have to decide on the special line of treatment which may be most appropriate in the case before you. Amongst the natives, antiphlogistics are seldom required, the inflammatory action being usually asthenic. If your patient be a weakly subject, who has suffered from frequent attacks of fever, you should order both eyes to be kept carefully closed with pads of cotton wool, the patient being allowed to bathe and take exercise morning and evening. If he is suffering from pain in the eye, it will be most

effectually relieved by the injection of a solution of morphia beneath the skin of the temple. A *blang** poultice often tends to ease the pain, and poppy-head fomentations are frequently most soothing to the patient. Should the eyeball feel at all tense, the cornea must be punctured and the aqueous humour drawn off. You need never hesitate to pursue this plan of treatment; it will invariably give relief if there be any intra-ocular pressure, and I have never seen any harm arise from it, provided care be taken to prevent the aqueous humour from escaping in a gush; if this occur, the congested retinal vessels will be in danger of giving way, and extensive hæmorrhage into the vitreous chamber may result. If the tongue be coated, and the patient complains of want of appetite, it will be well to order him a few doses of hydr. c. creta, with quinine and soda. A warm bath at bedtime will tend to relieve any febrile symptoms, if they should happen to exist. It is often necessary to administer bark and ammonia, together with the above alteratives, from the commencement of the attack, and the patient should be allowed a generous diet, and every practicable means taken to improve his general health. I do not think blisters are of much use in this class of cases.

Supposing your patient be a plethoric individual, and that his pulse indicates general irritation, a saline purgative should be given, and six leeches applied to his temple in the morning, and four more in the

* Indian hemp.

evening, fomenting the parts well after each application. The purgative will probably require to be repeated in forty-eight hours, and bicarbonate of potash and iodide of potassium should be administered in ten grain doses three times a day, low diet being at the same time enforced. If the symptoms do not abate under this treatment, you may give two grains of blue pill and one of opium every six hours, and apply more leeches. The subcutaneous injection must be employed, together with constant poppy-head fomentations: absolute rest of body and mind should be strictly enjoined. In neither the sthenic nor asthenic forms of retinitis is it advisable to perform iridectomy: if there be any intra-ocular pressure, the cornea should be punctured from time to time, so as to allow the aqueous humour slowly to escape, and thus relieve the tension of the eyeball; but excising a portion of the iris, according to my expêrience, leads to unmitigated evil.

Chronic inflammation of the retina frequently follows the acute form of the disease, or the inflammatory action may, from its commencement, run a slow and insidious course. Under these circumstances, the pain in the head, which, you will remember, is a prominent feature in acute retinitis, may be entirely absent; and even when present, it is no criterion whatever as to the amount of mischief going on in the eye. The patient probably complains of an uneasy aching sensation in the eye-ball, extending to the temple, which usually increases towards bedtime, together with sparks and flashes of light before the eye;

besides which, there is gradual loss of vision. The dioptric media, up to a late period of the disease, remain perfectly normal; ultimately the vitreous and lens become slightly hazy, and the pupil dilated and insensible to light.

These symptoms, however, are common to so many affections of the eye, that it is impossible to arrive at an accurate diagnosis without the aid of the ophthalmoscope. If the disease has existed for some time, the appearances noticed will much resemble those seen in acute inflammation: the enlarged and tortuous veins are well marked, as also the uniformly scarlet colour of the fundus of the eye from capillary injection, forming a thick vascular layer over the optic disc, so as to hide or render its outline very indistinct. This state of things may have been going on for months before you are consulted, and you will then probably find that either hæmorrhage, or some such complication exists, in addition to the ophthalmoscopic appearances above noticed.

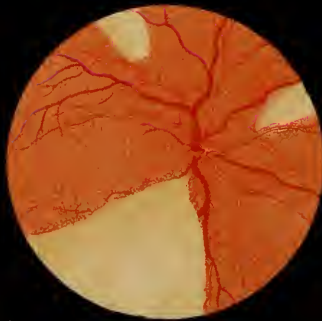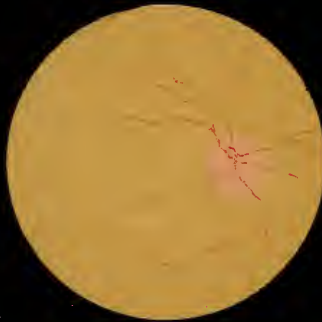
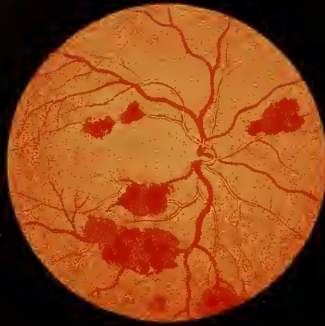The progress of a case of this kind will generally be from bad to worse, although its course depends somewhat upon the degree to which the complications, common to all forms of inflammation of the retina, have extended. From the persistent nature of the affection, irremediable damage often occurs to the nervous elements of the retina, so that, although the inflammation may subside, it never regains its proper functions. In many cases it is most difficult to detect the latent cause of this form of retinitis, the chronic inflammation being simply a local manifesta-

tion of some general affection of the system. Nevertheless, it is to the alleviation of this condition that your remedial efforts must, if possible, be directed; and unless you find that the eye has been hopelessly destroyed, a persistent trial should be made to improve the patient's health, and to attack the primary cause of its deranged condition, whatever that may be. Pain in the eye may be relieved by subcutaneous injections, and the evacuation of the aqueous humour should never be neglected, if there be increased tension of the eyeball.

In the last lecture, I noticed, very briefly, some of the *results of the inflammatory process*, when occurring in connexion with the retina, and these we must now consider a little more fully. From analogy, it is easy to conjecture what these effects are likely to be: *serous effusion* will exist in all such cases, and next in point of frequency, *extravasations of blood* may be noticed. This latter accident generally takes place in the deeper layers of the retina; the hæmorrhage is not usually very extensive, nor does it always appear to injure the nervous tissue; a patient may regain his eyesight perfectly, after the inflammatory process has passed off, and the blood has become absorbed. But, as I have before observed, if the hæmorrhage has been extensive, and has taken place in the substance of the retina, either in or near the macula lutea, your prognosis as to ultimate recovery must be very guarded.

It is hardly possible to mistake extravasated blood





in the retina for any other condition of the parts; if examined soon after the hæmorrhage has occurred, its colour is quite characteristic (*vide* Fig. 1, Plate VII.); subsequently this alters, and the hæmorrhagic effusions become darker, and are broken up into small patches. The larger extravasations gradually soften down, and are converted into a yellowish fatty substance, which may ultimately become absorbed. The depth at which they are situated in the retina, may be determined by the position they hold with regard to its vessels: the extravasation, if anterior, will of course hide the vessels; but if posterior, the central artery, or some of its branches, can be traced in front of the clot. Virchow describes these spots of extravasated blood as being precisely similar to those noticed in the brain. He says:—"The corpuscles within the mass may be either completely unchanged, or partly studded with fine granules. In the interior of these red masses, as well as at their circumference, may be seen fat corpuscles and conglomerate granules, that are either collected into firmly-cohering masses, or sometimes appear united into a network. The retinal elements themselves, in this condition, appeared either wholly unchanged, or the granular layer and the ganglion cells somewhat opaque—the latter, although not enlarged, presenting a more granular and yellowish aspect than natural; over which the bacillary layer was not easily discernible. Also, the capillaries of the retinal vessels, which often form an interwoven net, showed changes both in their walls and in their channels; the former, in

retained permeability of the vessels, being sometimes thickly set with fat granules, the latter occluded by capillary obstructions (embolia).”*

Another result that may attend either acute or chronic inflammation of the retina, is the *formation of lymph* upon its surface or in its substance, which, becoming organized, materially damages its delicate nervous elements. Fortunately for our patients, adventitious tissues of this kind seldom destroy the whole of the retina. They generally occur in patches, and, unless in the axis of vision, may do but little injury to the eye; nor does it follow, because lymph has formed in the retina, that it necessarily gives rise to organized tissue; the retina may be apparently infiltrated with lymph, which nevertheless, in time, becomes completely absorbed. We have lately had an instance of this kind attending the Ophthalmic Hospital.

Sahib Jaut Khan, a native of Lucknow, aged thirty-three, came to the Hospital on the 7th November. He was a remarkably strong and robust man, and had always enjoyed excellent health. He had never had anything the matter with his eyes until within the last seventeen days, when, on his road to Calcutta from Oude, he was seized with violent pain in the right eye, accompanied by intolerance of light and a constant flow of tears. The pain grew worse at night, and in the course of four or five days he completely lost the sight of this eye. On

* Carter's translation of *Zander*, p. 146.

arriving at the Hospital, he was totally blind with the right, but he could see distinctly with the left eye. The tension of the right eye-ball was T.+1, and a few large sclerotic and conjunctival vessels were to be seen coursing over its surface; the pupil was dilated and insensible to light; the patient still complained of severe pain in the eye. On examining it with a low illuminating power, I found the dioptric media healthy, but the optic disc and the whole of the retina were covered with yellowish-looking lymph. It seemed as if suppuration had already taken place, or must inevitably supervene. A few large and tortuous veins were noticed here and there, cropping out of the yellow-looking mass; it was impossible, however, to see even the position of the optic disc. The only favourable symptoms about this case were, as my assistant, Chunder Mohun Ghose, first observed, that in those portions of the veins close to the optic disc which were visible, the venous pulse could be seen; and further, that no hæmorrhage had taken place into the vitreous. Notwithstanding this, my prognosis was most unfavourable; I thought that, if abscess of the globe were prevented, it was all that I could reasonably expect. A subcutaneous injection of morphia was ordered, which was to be repeated as often as necessary; poppy-head fomentations were used, the eyes were closed, and absolute rest enforced. As the patient was plethoric, I prescribed a purgative of calomel, to be followed by compound jalap powder.

After three days, the pain in the eye was con-

siderably less, and he was then directed to take the one-twentieth of a grain of bichloride of mercury three times a day, absolute rest being still maintained, and the bowels kept freely open. The pain gradually subsided, and to my surprise, fifteen days afterwards, the man could distinguish my hand held up between his right eye and the light. In a week or ten days more, the vessels of the retina became gradually visible, and the pupil contracted on exposure to light; and in less than a month the patient regained almost perfect vision, the lymph had entirely disappeared, and the vessels of the retina assumed their normal condition. This was certainly a remarkable case, and I have referred to it in order to show, how favourable are the changes which occasionally take place in instances of the kind.

Should lymph become *organized* in this situation, the nature and position of the product may generally be clearly defined by means of the binocular ophthalmoscope, our landmarks in all such cases being the retinal vessels and the optic disc on the one hand, and the elastic lamina on the other; for although the epithelium of this layer is generally destroyed in retinitis, still the altered and broken-up cells may usually be seen, indicating the exact position of this structure, and, of course, any change posterior to it must necessarily be in the choroid or sclerotic. It is seldom possible to trace the vessels through a patch of organized lymph, as, in contracting, it obliterates their channels, and hence the circulation is stopped beyond the border of the adventitious formation.

These changes are more particularly marked after syphilitic inflammation; the lymph, under these circumstances, being very apt to form a dense fibrous tissue over the surface of the retina.

Another result that may follow inflammation is *atrophy of the retina*; and although similar changes may arise from other causes, I prefer describing them in this place.

If the atrophy has been preceded by inflammation, the scarlet colour of the retina gradually disappears, and the fundus of the eye becomes of a finely-granular buff hue; in some places, small black specks may be observed in it, which are the remains of the epithelium of the elastic lamina. In the early stages of atrophy, the calibre of the retinal vessels diminishes, and as the disease advances, they dwindle away to mere thread-like streaks; this condition is shown in Plate VII. Fig. 2. If the optic nerve be not involved in the disease, it retains its normal appearance; but in the majority of cases it becomes atrophied also, and then presents a white, glistening, and slightly depressed appearance which is very characteristic. I need hardly add that, if atrophy has taken place, we know of no remedial agents which can restore the nervous structure of the retina; it becomes converted, in fact, into a fibro-cellular tissue.

Atrophy, however, as I have before remarked, may occur quite independently of inflammatory action. We have a case now under treatment, which I have purposely kept in the Hospital, in order that you might study the appearances of the retina in this

disease. The figure above referred to, Plate VII. Fig. 2, was drawn from this patient's eye.

Sin Narth, aged twenty-two, states, that until he was seven years old, his eyesight was perfectly good: he then began to suffer from hemeralopia. In the course of a year or so, he found that his sight failed him also during the day-time, and at present he can only just grope his way about alone; he has never suffered from any pain. When he first came under my care, the tension of both eyes was normal, and they looked tolerably healthy, with the exception of the pupils, which were dilated and almost insensible to light. With the ophthalmoscope, we noticed that the optic disc was of its natural size and colour, but unusually depressed towards the centre, the border of the choroidal ring being ill-defined; the retinal vessels were few in number, and had dwindled away to mere threads. The fundus of the eye was of an uniformly yellowish-brown colour, and very minute dark spots could be seen apparently behind the altered retina; a few of the choroidal vessels were observed on a plane posterior to these spots on the elastic lamina. These changes, as I have before stated, may be considered characteristic of atrophy of the retina.

Suppuration is not a common consequence of inflammation of the retina, unless the retinitis has been induced by the presence of a foreign body in the eye, as, for instance, a dislocated lens. You will have ample opportunities of studying the symptoms and appearances of suppuration of the retina arising from this cause, the natives being so often operated on

by their own people for reclamation of the lens in cases of cataract. It is seldom, however, that the retina is alone involved in this form of disease; the inflammatory action, as a general rule, spreads to the other tissues of the eye, and general inflammation of the globe results.

In its early stages, the occurrence of suppuration may be known by the yellowish green and disintegrated appearance of the retina. The purulent formation is first observed in patches, which gradually coalesce, and ultimately the whole fundus of the eye looks like the wall of a recently opened abscess, with spots of extravasated blood scattered over it; the hyaloid and vitreous are speedily involved in the disease, and becoming opaque, it is impossible to trace the subsequent changes which take place in the retina. The patient usually suffers from the most severe pain in the eye during the progress of the disease, the globe becoming exceedingly tense, and ultimately the cornea ulcerates. A case of this description is, I need hardly say, perfectly hopeless; suppuration having commenced, there is no chance of saving the eye; your chief object must then be to preserve the sound one, and this may best be done by excising the inflamed eye, or else by cutting an elliptical piece out of the cornea, and allowing the contents of the globe to escape. As a general rule, the former method is preferable; for if the globe remain *in situ*, suppuration goes on from its surface, and the irritation is conveyed through its nervous connexions to the other eye, causing hyperæmia and congestion of

the retina. Your chief object, therefore, in operating will be thwarted, the sound eye being ultimately lost from sympathetic irritation.

Syphilitic inflammation of the retina differs from ordinary retinitis, in that the inflammatory action is particularly apt to confine itself to circumscribed patches, and there is, moreover, a marked tendency on the part of the lymph to become organized. I often find a spot on the retina looking deeply red and congested, and ultimately assuming a yellowish hue from the formation of lymph; this, again, becoming organized, a white glistening patch appears in the place of the originally inflamed tissue. These changes may run their course in a particular spot, and yet the remainder of the retina present no abnormal appearance whatever. Perhaps the vessels passing to and from the inflamed patch may be slightly congested, but this is by no means a constant appearance; and as I have already remarked, they can seldom be traced beyond it, as the lymph in the act of becoming organized contracts and obliterates them.

Syphilitic inflammation, however, is not always thus localized; it may be that the whole of the retina is inflamed; but even then blotches of lymph occur over its surface, which exhibit the same disposition to textural conversion. So far as my experience goes, hæmorrhage is not of common occurrence in syphilitic retinitis, and I have not met with a case in which I have been able to trace atrophy or suppuration of the retina to primary venereal disease, although this

result no doubt follows in cases of inherited syphilis. Professor Dittrich, of Prague, appears to have shown most conclusively, that in constitutional syphilis, various organs of the body, as for instance the liver, are affected by an inflammatory process, "of which," he says, "the most common termination is healing, either perfect or imperfect, leaving a cicatrix composed of fibrous tissue, with or without some granular matter enclosed within it. The exudative process never affects the liver substance as a whole, but only individual scattered parts The syphilitic blood-disease is either simple or combined with other dyscrasiæ, particularly the tuberculous, and the exudations in the liver are correspondingly modified."* Cicatrices of the kind referred to, the effects of the gummy inflammation, are precisely what we see, forming or actually formed, as the result of syphilitic affections of the retina, whether arising from the inherited or acquired form of the disease. The following case illustrates this point:—

Kallydass Sircar, aged forty, states that he contracted syphilis about a year ago, after which he had secondary symptoms, and four months since he observed that the sight in the left eye was growing dim. He had no pains in the eye, but complained of occasional flashes of light before it. The dimness of sight increased, and when he came to the Hospital his field of vision was much contracted; the tension of the

* See a paper by Dr. T. G. Stewart, *Med.-Chir. Rev.*, Oct. 1864, No. LXVIII. p. 514.

eye-ball was natural, and the iris healthy. With the ophthalmoscope, the dioptric media were discovered to be normal, the fundus of the eye and optic disc congested, and a large grey patch of lymph extended from the axis to the inferior part of the retina; another formation of a similar nature was noticed at the upper part of the retina. (*Vide* Plate VII., Fig. 3.) The patient's right eye was healthy. I ordered this man a mercurial bath three times a week, and five grains of iodide of potassium twice a day; he continued these medicines for a month; the congestion of the fundus of the eye diminished, but as there was no perceptible alteration in the organized formations in the retina, I recommended him to discontinue all treatment for a time.

This case supplied a good illustration of the appearances of an eye attacked by syphilitic retinitis; the opaque patches of white, adventitious tissue are characteristic of this form of disease. The treatment might perhaps have been advantageously continued a little longer, for it is surprising how speedily these formations will at times disappear under a steady and persistent course of mercury; but in this instance, the organized lymph had evidently been formed for so long a period, and it looked so white and glistening, that I despaired of effecting its absorption.

Inherited syphilitic retinitis generally comes on in infancy, but, unfortunately, there are no external symptoms to mark the progress or even the existence of this formidable disease, and it is only as the child grows older that his vision is discovered to be de-

fective. He is then, perhaps, supposed to be shortsighted, or to have some affection of the eyes, depending on dentition, which it is hoped he will outgrow; whereas the disease, if its real nature were recognised and judiciously treated, might very possibly be alleviated, and the sight saved. The importance of making an ophthalmoscopic examination, in the case of imperfect vision among young children, cannot be too strongly enforced. In order to do this satisfactorily, it may be necessary to administer chloroform, and if in any case the diagnosis is doubtful, you must not hesitate to employ it. Should you discover patches of syphilitic inflammation existing in the eye, you must at once resort to the treatment I have recommended in cases of similar affections of the iris, namely, mercurial inunction, together with tonics or alteratives as may seem most necessary. The rules which I have laid down for the cure of syphilitic opacities of the vitreous, are equally applicable to cases of syphilitic retinitis.

Detachment of the retina from the elastic lamina may arise, either from the effects of a blow on the eye, or from disease. I had lately an instance of the former class of cases sent me by my friend Dr. Flemming of Berhampore.

A patient of his had been struck with a racket-ball on the left eye; immediately after receiving the blow, he found he had completely lost the sight of the eye. When I first saw this gentleman, I observed that the pupil was widely dilated; he could distinguish large

objects in certain directions, the injury evidently being in the axis of vision. On examining the eye with the ophthalmoscope, a considerable portion of the retina, extending from the optic disc outwards and downwards, was found to be detached, and below this a clot of blood could be seen, over which the retina seemed to hang. The fundus of the eye was intensely congested, as well as the optic disc, and there were several spots of extravasated blood scattered over the retina. (*Vide* Plate VIII., Fig 1.) I recommended this patient to keep the injured eye closed, and to rest the other one as much as possible. In a month's time I again saw him; the sight had improved, and the congestion and extravasation had almost disappeared; a considerable portion of the large clot noticed in the lower part of the eye had also become absorbed, but the appearance of the detached retina, in the axis of vision, remained unchanged. It happens occasionally, that the whole of the retina is dragged away from the choroid, and it then assumes a funnel-shaped form, the apex being at its point of attachment to the optic disc. The vitreous, however, must have passed into a fluid condition, to allow of the retina falling forward in this way.

Complete or partial detachment of the retina can hardly be mistaken for any other disease; the retinal vessels may be traced up to the margin of the wound, where they will be seen to terminate abruptly, or bend back, as in the above instance, at the point at which the detached retina deviates from the plane of the fundus of the eye. However, it is seldom neces-

sary to resort to minute distinctions of this kind, in order to determine the nature of the case. The jagged wound in the retina either leaves bare the hexagonal cells of the elastic lamina, or else, these having been destroyed, the choroid is exposed, and very frequently the white glistening sclerotic behind may be seen through the rent.

Separation of the retina from the choroid, the result of effusion behind the former structure, is not necessarily accompanied by any pain in the eye, and the patient probably complains only of gradually increasing dimness of vision. On examination, you will find a portion of the retina bulging forward into the vitreous chamber, like a small bladder. The colour of the detached tissue varies: in the early stages of the disease it remains transparent, looking like a grey film upon the dark background of the choroid; by degrees, however, the nervous tissue degenerates and becomes opaque; in fact, the same changes occur as I described to you in cases of œdema. If you have any doubt as to the nature of the disease, you must follow up one of the retinal vessels from the optic disc to the point of apparent separation of the retina, and you will notice that the vessel, in passing over the bladder-like projection, is on a plane anterior to that of the fundus of the eye; and accordingly you will have to alter your focal distance to see it distinctly. As it dips down on the other side of the projection, it will again be indistinctly seen till you re-adjust the focus. The calibre of the vessels, as they pass over the retina, is seldom altered; the

vascular system, in fact, is unaffected in cases of this description, and the separation of the retina from the choroid may take place apparently without any appreciable structural change in any of the other tissues of the eye. On the other hand, it may be complicated with inflammatory or other abnormal appearances.

Separation of the retina, such as I have now described, is generally noticed at its lower portion; this fact is explained by supposing that the fluid behind it gravitates downwards, and accumulating in the inferior part of the retina, produces these appearances. This may be the true explanation of the phenomenon; but I hardly think it can be so, or we should see more cases of separation of the retina from the choroid, in consequence of œdema supervening upon capillary hyperæmia or inflammation, than at present come under our notice. I believe that the diseased action, in these cases, commences in the epithelium of the elastic lamina, and that the retina is pushed forwards by the fluid which collects behind it; its nervous tissue subsequently degenerates, and becomes opaque.

Total loss of sight must be the inevitable result of this state of things, unless the surgeon can afford some relief to his patient; and fortunately this may be done, as has now been proved by Von Graefe and Mr. Bowman. Their mode of proceeding is to pass two needles through the effusion, so as to let it escape into the vitreous, or externally into the choroid. Successful cases of the kind are sufficiently numerous to allow of our admitting this proceeding into the list of approved ophthalmic operations. Before

adopting this measure, however, in any particular case, it is necessary to determine whether the retina is comparatively sound, so as to lead us to hope, in case the effused fluid is got rid of, and the retina restored to its normal position, that our patient will gain some advantage from the operation. You may judge of this pretty accurately by the appearance of the retina: if it looks dull and opaque, it is more than probable that its nervous elements have degenerated, and in that case it will be of no use interfering.

Your intention in operating should be to make a free opening through the effusion, so as to allow it to escape into the vitreous chamber; the retina will then fall back into its normal position, and, unless structurally altered, its functions may be restored, and the patient regain almost perfect vision. The plan Mr. Bowman recommends appears to be the best adapted for this purpose:—The site of the separation of the retina having been carefully studied with the ophthalmoscope, the patient is placed on a couch, and a stop speculum having been introduced to keep the lids apart, the surgeon passes a needle through the sclerotic vertically into the eye, transfixing the retina at its point of separation from the choroid; another needle is then inserted through the same opening, and the handles of the two being separated the one from the other, their points are made to diverge like the blades of a pair of scissors. In this way the retina is torn through, and the fluid behind it escapes into the vitreous chamber; usually a small quantity passes out along the needles, and exudes beneath the conjunctiva,

but this is not always the case. After the operation the retina falls back into opposition with the elastic lamina. In cases of this kind, the chief point to attend to is not to transfix or injure the lens in any way; but an ordinary amount of anatomical knowledge will enable you to keep clear of it with the needles; and if you do not touch the lens, you may be sure that no injury will result from passing the needle into the vitreous, even if you do not succeed in effecting a cure. After the operation, the only necessary treatment is to keep the eye closed for a few days with a pad and bandage.

We have recently had in the Hospital an instructive example of the beneficial results of this method of treatment:—

Bhowani Blick, aged forty-five, came to the Hospital on the 21st of March. He stated that four months ago his sight was perfectly good; he was then attacked with fever, and about two months since, after a paroxysm of ague, he found the sight of both eyes had become hazy. He suffered from no pain in the eyes, but the imperfection of vision grew worse day by day. When first he came under my notice, he could not distinguish the largest sized dots at a distance of two yards; when quite close to his eyes, he could count them with difficulty. The tension of the eye-balls was normal, the pupils dilated and insensible to light. On examining the eyes with the ophthalmoscope, the dioptric media were found healthy, but there was evident separation of the retina from the elastic lamina in both eyes, extending from below

upwards, beyond the upper border of the optic disc; the retina was sufficiently transparent to enable me to see the congested vessels of the choroid behind it.

I at once put the patient under the influence of chloroform, and passed two needles into the vitreous, so as to transfix the inferior part of the retina in the right eye. A small quantity of dark fluid passed out along the needles. After the operation, the eye was closed with a pad and bandage. On the following day, the 22nd of March, my patient was suffering from considerable pain in the eye, but this was relieved by a dose of castor oil and fomentations; on the 23rd he was free from pain, and on the 25th he could see to count No. 4 dots at ordinary distance with this eye. I therefore operated on the left one in the same way, and with an equally favourable result. On the 6th of April, I found that the fundus of each eye was perfectly normal, with the exception of the congested state of the vessels of the choroid. Bhowani could now see to thread a needle; his sight, in fact, was as good as it had ever been, and it continued so, up to the 20th of April, when he left Calcutta for his home in the North-West.

LECTURE VII.

Congestion of the Vessels of the Retina from Mechanical Causes. Extra-orbital Pressure. Embolia. Melanœmia of the Retina. Removal of Hexagonal Cells of Elastic Lamina. Colloid Disease of Elastic Lamina.

IN a former lecture I observed, that hyperœmia of the retina is occasionally induced by congestion of the veins of the eye, consequent on some *mechanical obstruction* to the free return of blood to the internal jugulars. The tendency of most of the pathological conditions which cause an impediment to the circulation of this kind, is to run a slow course, and they are frequently attended with head symptoms, which being a more marked feature in the history of the case than the affection of the eyes, the majority of these patients find their way into the physicians', and not into the surgeons' wards.

I am inclined to think, that the commonest cause of occlusion of the orbital veins is *syphilitic inflammation of the dura mater*, extending to the sheath of the vessels in the cavernous sinus. In such a case, the patient will suffer from violent pain in the head, and other signs of irritation in the membranes of the brain, and there will be, in addition, the ophthalmoscopic appearances which I shall presently describe as

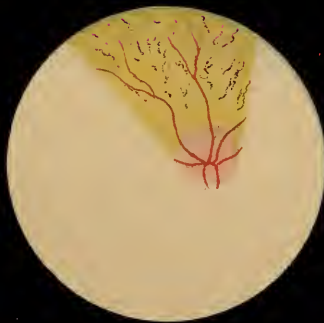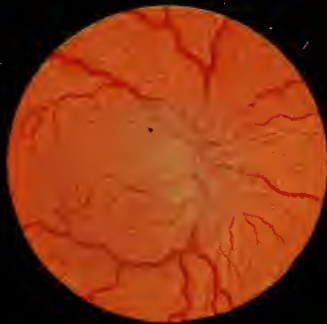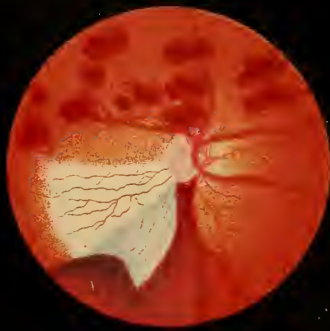pathognomonic of obstructed venous circulation. On the other hand, if a *tumour* growing from the base of the skull, or in the substance of the brain, be the cause of the malady, it will probably give rise to perverted functional action of that part of the sensorium upon which it presses, indicating the origin and seat of the disease before the circulation in the retinal vessels is considerably affected.

To whatever cause, however, the obstruction to the free passage of blood through the veins is due, the vessels of the fundus of the eye will be found very much congested: they present the tortuous appearance noticed in cases of inflammation of the retina, but the venous pulse cannot be seen. The optic disc looks hazy and indistinct, on account of the serous effusion into the nerve substance, which renders it somewhat opaque. This hazy condition does not extend to the outer part of the retina, seldom in fact beyond the macula lutea, and it is never so dense as to hide the vessels of the fundus. Should the exciting cause which has given rise to the impediment in the circulation continue, the retina and choroid undergo degenerative changes, accompanied by effusion of blood into the retina, and ultimately atrophy of its nervous tissue; so that the direct tendency of the disease is to terminate in complete loss of vision.

The following case, lately under my care in the Hospital, will serve to illustrate the history and symptoms of this affection, and the ophthalmoscopic appearances usually met with in obstruction to the circulation in the eye from extra-orbital pressure.

Sorosutty, aged thirty-six, a prostitute, was brought to the Hospital on the 19th September; she was almost blind, and was led from one side of the room to the other. It appeared that her memory was completely gone, she was constantly crying out that she was being beaten on the back of the head. Her friends stated that she had had syphilis, followed by secondary eruptions, but that otherwise she had enjoyed good health up to within the last six months, when she was seized with violent headaches, which increased towards evening, and drove her almost mad with pain. These have continued without intermission up to the present time, and she has lately had what appear to have been epileptic fits.

On examining the eyes, I found the pupils dilated, the conjunctiva and sclerotic of normal appearance, and the cornea and lens healthy; the tension of both eye-balls was rather less than usual; the patient could only just distinguish light from darkness, and was in a very weak condition. On making an ophthalmoscopic examination, I found both eyes in much the same state. (*Vide* Plate VIII., Fig. 2.) The calibre of the retinal veins was enlarged, the arteries were rather contracted, and the capillaries decidedly hyperæmic; in addition to this, the optic disc and the parts around it, as far as the macula lutea, were covered with a hazy film, evidently from œdema and slight opacity of the retina. It will be noticed in the drawing, that the haziness of these parts was not sufficient to hide the vessels of the retina, nor did it extend beyond the macula lutea. These changes in



the eye, however, were in themselves insufficient to account for the complete loss of vision from which our patient was suffering; and this is a point which you should not lose sight of, in forming an opinion in a case of this kind, namely, that the functions of the retina are not completely arrested by mere congestion of its vessels.

As this patient was very weak, I ordered her ammonia and infusion of cinchona three times a day, together with strong soup, and any other nutrient material she could be persuaded to take, and a grain of morphia was administered every night. Under this treatment her general health improved, and in the course of ten days I was able to give her the cinchona with iodide of potassium, and subsequently she had a calomel bath three times a week. The pain in the head gradually subsided, and on the date of her leaving the Hospital she could just see to walk about the ward, and the congestion and hyperæmia of the retina had almost entirely disappeared. The hazy state of the optic disc no longer existed, and it seemed to be of its natural size, but whiter than in health. This was probably due to some degree of atrophy of the nerve, induced by the action of the syphilitic poison upon its fibro-cellular sheath; and to a similar cause we must attribute the symptoms of obstruction to the venous circulation which evidently existed. The sheath of the orbital vessels in the cavernous sinus is, if you remember, composed of offsets from the dura mater, and this becoming inflamed and swollen, had impeded the circulation of blood through the

vessels in the sinus, and hence in the choroid and retina.

The symptoms in this case were such as to suggest that the origin of the disease had been syphilitic inflammation of the dura mater; for in the first place, there was no doubt that the woman had had venereal disease, and the pain in the head, increasing at bedtime, also pointed to syphilis as the probable cause of the malady; the irritation, it was supposed, had gradually extended to the brain, inducing the epileptic fits. The subsequent history of the case confirmed this diagnosis, for under an appropriate treatment the thickening of the sheath of the vessels was removed, and the circulation restored to its normal state; but, unfortunately, structural changes had in the meantime taken place, ending in partial atrophy of the nerve, and almost total loss of vision, such as could not be accounted for solely by the congested state of the vessels and effusion into the retina.

But let us suppose, that in a simple case of extra-orbital obstruction, the retinal circulation were not restored to its normal state; it is evident that the congestion of the veins and capillaries must ultimately lead to retinal atrophy, the tissues not receiving a due amount of nourishment, independently of the mechanical injury induced by the œdema. Gradually, therefore, the retina would waste away, and the vascular channels become occluded, the vessels themselves shrivelling up to mere threads. But during these changes the lens and vitreous would degenerate also, from want of a due supply of nutri-

ment, and becoming opaque, they would render it impossible to watch the further progress of the disease with the ophthalmoscope.

The treatment to be pursued in cases of obstruction to the retinal circulation must depend entirely upon the view which is taken of the nature of the disease in each individual case. I have given you an instance of the most common cause of this condition, namely, syphilitic inflammation of the dura mater—one which is probably more amenable to treatment than any other form of the affection. I need hardly add, that if a tumour of the brain obstructs the return of blood by the jugular vein, the case is almost a hopeless one ; but fortunately instances of venous congestion of the eye arising from this cause, are very rare indeed. It would be quite impossible for me in a course of lectures of this kind, to attempt to describe the various conditions which might arise within the cranium, inducing compression of the walls of the vessels, and consequently impeding the circulation : it is more within the province of the physician to treat of these subjects, and I must content myself with having directed your attention to the ophthalmoscopic appearances of the retina under these circumstances, and to the particulars of an actual case, exhibiting the history of the affection in its most familiar form.

I must now pass on to say a few words upon some other forms of obstruction, occurring in the retinal vessels themselves ; and first, of the somewhat rare condition, known as *embolia* of those vessels.

You will find the details of a remarkable case of this disease, and two plates illustrating it, in Liebreich's *Atlas*. In the majority of the recorded instances, embolia of the retinal vessels has been met with among patients suffering from disease of the aortic valves. The symptoms commonly appear suddenly, in a person who has previously enjoyed good sight: probably the patient has gone to bed perfectly well, and on rising in the morning discovers that he is almost blind in one or both eyes. On examining them with the ophthalmoscope, the optic disc will appear of its normal size, and though rather pale, in other respects unaltered; the same remark applies to the retina. It is in the vascular system that we shall discover the most marked changes to have taken place: the arteries and veins, either in the whole or in a portion of the fundus of the eye, will be found to be very much contracted; the circulation seems almost to have ceased, and the vessels to have collapsed, except in one or two spots where they are distended with blood; this is chiefly noticed in the veins. The blood may be seen to move slowly on towards the optic disc, the walls of the vessels contracting completely behind it, and this condition lasts till another wave passes through the vessel in a similar way; a sort of peristaltic action is thus induced, which may be general, or confined to certain veins. If the obstruction to the circulation continue, it is evident that, from want of a proper supply of blood, the retina will pass into a state of fatty degeneration, and as the macula lutea is least abundantly

supplied with bloodvessels, it will be the first to suffer. Virchow has described and explained the cause of these phenomena in the circulation; he believes they arise from the presence of small coagula (*emboli*) in one or more of the retinal vessels; they are most commonly met with near the lamina cribrosa. In some cases, the walls of the vessels have been found thickened and otherwise diseased.

A remarkable case of the kind is quoted by Zander from Ed. Jaeger. The individual was an old man, seventy-two years of age, the subject of hæmorrhoids. "The ocular media," he states, "were perfectly transparent, the retina appeared of a medium yellowish red, without visible morbid change. The optic nerve, slightly pigmented at the circumference and somewhat yellow-tinted, exhibited slight indications of bluish spots. The vascular system of the retina, generally of small development, exhibited, in the larger trunks more especially, a proportionately small diameter. The corresponding large arteries and veins were equal in diameter, and alike in their dark red colour. No double contour was apparent, so that arteries and veins could only be distinguished by their clearly visible respectively centripetal and centrifugal circulation. This had not the appearance of a pulsation, since the walls, especially of the larger vessels, remained undisturbed; but it was a movement slower or quicker, uniform or interrupted, but not rhythmical, of an unequally coloured stream of blood. In the larger vessels, the blood-stream exhibited, at distances of from one-fourth to the whole diameter of the

vessels, intervals of lighter and darker red colouring ; which, however, in the movements of the column, were continually changing, the lighter spaces becoming smaller and wholly disappearing, to be formed anew elsewhere. The movement of the blood appeared in such places uniform, but extremely sluggish. In the vessels of medium size the movement was quicker, and often for a short time pulsatile ; the light intervals were of a paler red, and, as well as the dark portions, of a greater comparative length, being from twice to four times the diameter of the containing vessel. In the finest twigs visible upon the optic nerve, the movement of the blood was most rapid, and, at the same time, most disturbed. The extremely delicate stream of blood would be suddenly interrupted, the dark red part of the blood would disappear, and the little vessel, scarcely discernible upon its bright background, would seem to have assumed the tint of the optic disc. Then, in interrupted course, a shorter or longer column of blood would pass through the vessel, followed at greater or less intervals by a larger or smaller mass of blood globules, so that the observer almost appeared to see single globules, and then suddenly the vessel would be filled in its whole course with dark red blood, the portions of which seemed rather to roll through than to flow quietly. This circulation, which in arteries and veins of like calibre was of equal rapidity, diminished by degrees, and remained here and there suspended for longer periods, until, at the end of twenty-four hours, it was wholly obstructed. The retina generally had then assumed a somewhat darker red ; and the diameter of all the

vessels was visibly increased. The smallest were distended with blood, unless when a lighter portion, or an interruption of the dark red column, was perceptible, and were proportionately the most enlarged. The vessels of medium size showed here and there a short break in their colouring, to the extent of from half to twice their diameter. The chief trunks were for a considerable extent uniformly filled by red blood. On the other hand, the more faintly-coloured portions of the vessels, of equal intensity of colour to that of the background, were from twice to four times their natural diameter. Their walls, which were clearly visible, exhibited no diminution of calibre. It appeared as if the blood globules had at parts crowded themselves more closely together (the blood dividing itself into a red and into a transparent part), and uniformly filled the vessels. In the medium-sized and smallest vessels not the slightest movement was visible; but in the larger, by careful attention for one or two minutes, the lighter parts might be seen to diminish and disappear, at the same time reappearing in another place.”*

There is another disease of the retina, depending upon a mechanical interruption to the circulation, which may be conveniently noticed in this place. I shall describe it as *melanæmia of the retina*.

In the translation of Frerichs *On Diseases of the Liver*, published by the New Sydenham Society, vol. i. p. 319, you will meet with the following

* Carter's translation of *Zander*, p. 137.

description of blood-pigment, as occasionally met with circulating in the vessels and in the tissues:—" This tinging with pigment is much more easily detected in the brain, in which considerable collections are sometimes recognised, by the dark-colouring of the cortical substance. This assumes a chocolate or blacklead-like hue, whilst the white matter remains

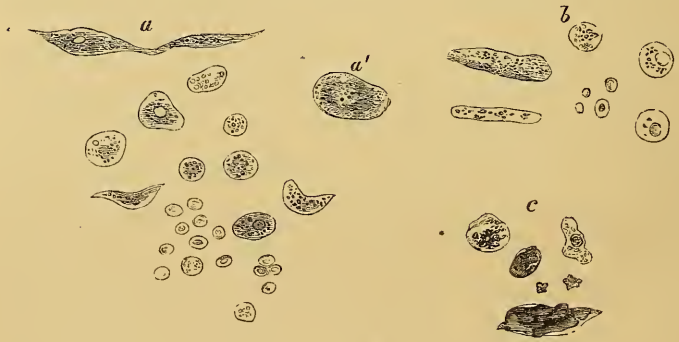


FIG. 6.*

unchanged; it is only when the pigmentary deposit is excessive, that we see the white matter present a grey appearance, and the fine vessels in it resembling brown streaks. Under such circumstances, microscopic examination has shown the capillaries to be filled with black granules and scales (*Schollen*), which at one time are uniformly distributed, but at another

* *Pigment-matter from the portal veins.* (After Frerichs, *Atlas*, Plate IX., Fig. 2.)—*a.* From the trunk of the vessel. The epithelium of the lining membrane containing black pigment, and some of the cells with a distinct rounded or spindle-shaped nucleus; the younger cells were coloured reddish-brown; normal blood corpuscles. *b.* Cylindrical scales (*Schollen*) containing pigment. *c.* Fragments of black pigment, enveloped in a hyaline substance, from the splenic vein. *a'.* From the splenic vein.

are aggregated in groups. Frequently we observe, along with the pigment scales, a pale hyaline coagulum, which when viewed with a light of a strongly refracting power, may be seen to fill up the calibre of individual capillaries." The accompanying figure (Fig. 6), which is copied from the work just quoted, exhibits some such pigmentary structures taken from the portal and splenic veins.

In cases of intermittent and remittent fevers, you will sometimes find free pigmentary matter, and pigment-cells of this kind, in the blood. The cells, at first sight, look like white blood-corpuscles; but if carefully examined, their black granular contents may be clearly defined, and their irregular shape and size preclude the idea of their being simply white blood corpuscles; besides which, the presence of free, granular, pigmentary matter in the blood, points most conclusively to their real nature. The white blood corpuscles, in these cases, are not increased in number, but there is a diminution of red ones, and the majority of these, presenting numerous spine-like projections, look like small stars; a number of dots are observed on their surface, which represent the spines as seen from above; the globules give one the idea of being about to pass into a state of crystallization.

In examining these cells, you must be careful to take perfectly fresh specimens of blood; the best plan is to place it under the microscope immediately after it has been drawn from the arm of the patient. It will then be evident that these irregular bodies are the altered blood globules, which, from some cause or

other, have been rendered unfit for further work, and are about to be metamorphosed into excrementitious material; but the colouring matter they contain, appears, under certain conditions, to be of a more lasting nature than the rest of the globules, and collecting in small masses, it forms the above-noticed lumps of pigment. The destruction of the globules probably takes place in the spleen, the blood being retained in its venous sinuses during congestion of that organ; and it is possible that its acid secretion, acting on the colouring matter of the globules, may change it from a bright red into a black colour. But, however this may be, there can be no doubt that the red colouring matter of the blood may, under certain conditions, be altered into a black substance, which has frequently been detected, not only in the blood, but also in the various organs of the body.

Provided, therefore, fresh specimens of blood are examined, if any free pigmentary matter is discovered in it, I think we are justified in assuming, that the same condition existed in the circulating fluid prior to its being drawn from the arm; and if it be remembered that some of these small masses of pigment are the $\frac{1}{100}$ of a line in breadth, and $\frac{1}{20}$ of a line in length, we cannot be surprised at occasionally meeting with instances in which the capillaries become plugged with them. Frerichs states that, next to the capillaries of the liver, those of the brain are most frequently affected; and I believe we may add, that the small vessels and capillaries of the retina are at times similarly occluded. The latter are about

the 0·002–0·003''' in diameter, and their meshes rather wider apart than in other parts of the body. The following case appears to have been of that nature:—

The patient, Bidadoo, is well known to you all ; he is thirty-five years of age, a labourer by occupation, and first applied for relief on the 19th May, 1864, on account of loss of sight. He is a well-built, strong looking man, rather anæmic, but states that, with the exception of attacks of fever, he has always enjoyed good health. About six months ago, being in a very malarious part of the country, he was seized with remittent fever ; prior to this his eyesight was perfectly good. He underwent great privations, and six days after the fever came on, he found his sight growing dim ; he had no pain in the eyes, nor was there any photophobia, but from that time to the present the field of vision has gradually contracted, and now he can only just see to grope his way about the room. I found the tension of both eye-balls natural, the pupils dilated, but there was no external indication of disease. On examining the patient's eyes with the ophthalmoscope, I discovered the optic discs of both to be of normal size and colour. The vessels of the retina were contracted to a very small diameter, and at the outer part of the retina, a number of elongated black spots were noticed, which I have endeavoured to represent in Plate VIII., Fig. 3 ; a part only of the pigmentation is drawn, as the remainder of the retina presented an exactly similar appearance. Some of the black lines appeared to be the smaller branches of the

arteries, which had been plugged with pigmentary matter. In many places, however, it was impossible to trace the atrophied vessels up to the point at which they had become occluded, whereas, in other branches, small deposits of pigment could be detected actually filling up the vessels. Besides these pigmentary deposits, there were a number of faint dark markings observed in the substance of the retina itself, which seemed to me to arise from a stained condition of its nervous tissue, consequent on the previous free circulation of pigmentary matter in the capillaries, the larger masses having been subsequently stopped in the smallest branches of the arteries. The fundus of the eye was of a pale yellow colour in this case, and there were no hæmorrhagic spots to be seen on its surface.

The patient had not been in Hospital long, before three other cases of a precisely similar nature presented themselves for treatment; not that these are a common class of cases, but, as so often happens in hospital practice, a certain form of disease appears at times to have a run, and then to disappear for weeks or months together. However, these four cases coming one after another, and each of them having a similar story to tell of blindness supervening on repeated attacks of remittent fever, led me to think that the changes noticed in the eye must have arisen from the same cause, and one closely connected, in some way or other, with malarial influences.

Shortly after Biddoo came under my care, he was attacked with fever, and during a remission on the

9th of June, I opened a vein in his arm, and drew off a small quantity of blood; a portion of it was at once placed under the microscope, and I quote the appearances it presented in the words of the Professor of chemistry. He says, "Four or five or even more pigment cells or masses could always be seen at one time in the field of the microscope. The cells generally resembled the white corpuscles of the blood, but contained many black granules. Some of these cells were considerably larger, and of an oval shape. Together with the cells, irregularly shaped masses of pigmentary matter were to be seen in the field of the microscope." If you compare this description with that given by Frerichs, and with his representation of pigmentary matter from the portal vein (Fig. 6), you will find them to be very much alike.

Those of you who have watched these cases must have been struck with the correspondence between the appearances actually noticed in the retina, and those we should have expected to meet with, if pigmentary matter, such as I have described, had been circulating in the blood—if small particles of it had been jammed into the branches of one of the minute arteries, and others had attached themselves to these, until at length the vessel had become plugged up, the circulation in the retina almost stopped, and atrophy of the nervous tissue resulted. As I shall presently explain to you, in speaking of choroiditis, I by no means assert, that deposits of pigmentary matter are not found in the retina under other circumstances;

but simply, that atrophy of the retina may result from the vessels becoming plugged with free pigmentary matter, derived from alterations in the blood corpuscles consequent upon malarial poisoning.

In some cases you will find, in addition to the appearances above described, numerous small clots of blood scattered over the surface of the retina; an instance of this kind was lately under our care in the patient Ram Coomar Halder. In that case, the ecchymoses had evidently taken place behind the patches of pigmentary matter, and probably, by subsequent alterations, they had caused the primary deposits to assume the appearance of irregular-shaped black masses.

The fundus of the eye is generally of a buff colour in this disease, and presents a peculiar mottled aspect. This appearance is referrible, in great part, to the conversion of the hexagonal cells and elastic lamina into a tough fibrous structure, and to the atrophied condition of the nerve; but, as I have before stated, I believe it also partly arises from the stain which the colouring matter, previously circulating through the capillaries, has induced; for it by no means follows that the tissues may not be stained in this way, without any of the vessels being plugged up with pigmentary matter.

There is one point upon which I must caution you, and that is, against supposing that because your patient is suffering from melanæmia of the retina, it necessarily follows that you will find free pigment in his blood, whenever you may choose to look for it.

If such were the case, it is evident that the circulation throughout the body would be speedily stopped, and death inevitably follow. It is only after a paroxysm of fever that you are likely to find the free colouring matter in the blood, and it is then you should search for it. It is at such times, when the venous sinuses of the spleen have been engorged with blood, that the changes in the corpuscles occur, and black pigment is to be found in the circulating fluid, whence, however, in the course of a short time, it is carried off through the liver and kidneys. I am unable to explain why these pigmentary deposits should occur in the retinal vessels in some cases and not in others; you cannot, however, do better than pay special attention to the subject; it is one which will well repay careful research, and most of you will have ample time, and plenty of opportunities, for making original observations upon the various effects of malarial influences on the system. No doubt, very many instances of Bengal dysentery and diarrhoea have their origin in changes, such as I have described in the retina, taking place in the vessels of the liver and intestinal canal.

Before concluding this lecture, I have a few additional observations to make respecting the elastic lamina, and the pathological alterations to which it is liable, and we may then proceed to consider the diseases of the choroid when we next meet.

The elastic lamina, as you are aware, is an homo-

geneous membrane, continuous with the posterior layer of the cornea, whence it passes backwards over the ciliary processes to the optic disc, round the margin of which it is attached; it is separated from the sclerotic by the vascular network of the choroid and ciliary processes, and internally it is lined by a layer of epithelial cells. Where these form the posterior surface of the cornea, they are transparent, but in the eye of the native, over the ciliary processes and choroid, they are full of black pigment, so that the structures behind these pigment-cells cannot well be seen till they have been removed. Yet we frequently see the vessels of the choroid looking as if injected with vermilion, and placed on a black background; under these circumstances, therefore, the hexagonal cells of the elastic lamina must have been destroyed, or in some way removed. It is possible that, from congestion of the vessels, the epithelial cells may be pushed on one side, so as to expose the capillary network of the choroid behind them; but, although it be admitted that these cells are elastic, and capable of separation from one another, still, I believe, the vessels of the choroid can seldom be seen through them, remaining invisible unless they be entirely destroyed. It is by no means an uncommon thing to meet with instances of the latter kind, the epithelium being completely broken up, and patches only of it left in various places, over the surface of the lamina.

But these pigment-cells may be entirely removed, and still the patient's vision remain almost unim-

paired ; the presence, in fact, of the epithelium, so far as I can ascertain, does not seem essential to sight. No doubt, it is placed there for some important purpose, though I am not aware of what its precise functions may be ; but this much is certain, that the pigmented epithelium must absorb a vast number of the rays of light which enter the eye, and in a tropical climate, where the glare of the sun is excessive, this would be a great protection to the retina. The want of such a protection, and the consequent impairment of vision, are well illustrated in the case of albinos. I have met with several of these unfortunate creatures, the offspring of native parents ; they have been unable to bear the glare, and their sight has been generally defective. In these cases, no doubt, we must take into consideration the fact, that not only the epithelium of the elastic lamina is void of colouring matter, but also that of the stroma of the choroid ; for, as I said before, I have certainly seen instances in which the hexagonal cells alone have been almost completely destroyed, and yet the patient's vision has been remarkably good. Cases of this kind are, however, rare ; for though the removal or destruction of the epithelium of the elastic lamina does not appear directly to affect the functions of the retina, still, in the majority of cases in which these changes occur, some pre-existing disease has caused the disintegration of the cells ; and it is to the primary affection of the eye that we must look for the cause of the impairment of sight, which often accompanies the loss of the hexagonal cells.

A very peculiar disease of this membrane has been described as *colloid degeneration* of the elastic lamina. The tissue becomes thickened in certain spots, small wart-like projections forming on its inner surface, which may be sufficiently numerous to render the elastic lamina rough and uneven, and cause absorption of the hexagonal epithelium. These changes are rarely met with except in very old people, some few instances only having been recorded in which younger persons have suffered from the disease; and as old people are apt to suppose the dimness of vision which they experience to be simply the result of advancing years, they do not think it necessary to consult a surgeon on the subject, more especially as the affection occasions them no pain. Colloid degeneration, therefore, seldom comes under our notice until a late period; but even if this were not the case, it would be out of our power to trace the changes taking place in the elastic lamina in its early stages; so soon, however, as the disease has advanced a little, we may recognise the uneven condition already described.

In the last stage of the disease, the projections on the elastic lamina become calcified, and ultimately earthy matter is deposited in them, so that they effervesce on the application of a strong acid, and, when cut, the edge of the knife grates against them in an unmistakable manner. As these changes advance, the lamina of course becomes opaque, and the vessels of the choroid, which, in the early stages of the disease, were exposed by the destruction of the hexagonal

cells, gradually become indistinct, and are ultimately entirely hidden from view. The walls of the vessels also are diseased, earthy matter is deposited in them, as well as in the elastic lamina, so that atrophy of the choroid ensues, which is usually followed by opacity of the lens and a fluid condition of the vitreous.

LECTURE VIII.

Diseases of the Choroid. Hypercæmia. Choroiditis. Cases. Treatment by Iridectomy. Results of the Inflammatory Process; Exudations; Suppuration. Tubercular Deposits. Atrophy of the Choroid.

WHEN describing the anatomy of the eye, I stated that the choroid and ciliary processes are enclosed externally by the sclerotic and ciliary muscle, and internally by the elastic lamina, which is continuous in front with the posterior layer of the cornea, and behind is attached to the margin of the lamina cribrosa. A portion of the fibrous structure of this layer is prolonged into the iris, and consequently, if the iris be torn away from its attachments, it is very probable that an opening will at the same time be made through the elastic lamina; and supposing there were effusion of serum or blood behind it, this might then escape into the anterior chamber. The bearing of these anatomical considerations on the nature and cure of choroiditis and glaucoma, will be seen when I come to speak of the treatment of those affections by iridectomy.

The sclerotic and elastic lamina are bound together by means of fibro-cellular tissue, among the interstices of which there are a vast number of branching and

anastomosing cells, containing a quantity of black pigment, and also vessels and nerves, besides a series of striped muscular fibres, which, together, make up the substance of the choroid. The choroidal vessels pierce the sclerotic posteriorly, and ramifying on its inner surface, they give off numerous branches, terminating in a layer of capillaries, some of which are in contact with the elastic lamina; it is evident, therefore, that if the hexagonal cells be destroyed, some of the larger vessels of the choroid will be seen with the ophthalmoscope through the transparent media of the eye; the intervascular spaces, being occupied by the pigment cells of the choroid, will appear as black islands encircled by the vessels.* The capillary network, situated immediately behind the elastic lamina, is remarkably intricate, its vessels, when congested, occupying more space than the intervals between them, so that they form, as it were, a thin veil in front of the stroma of the choroid, and conceal a considerable portion of its pigment-cells.

In the fair-haired European, there is but little colouring matter in the cells of the choroid or elastic lamina, hence the reflection from the fundus of the eye appears of a bright red colour, when examined with the ophthalmoscope. Supposing, in the case of a native, that the hexagonal cells have been removed, and that the stroma of the choroid is hidden by its layer of injected capillaries, the reflected light from the fundus of

* These remarks apply to the eye of the native.

his eye will then be of much the same hue as that of the European. On the other hand, if the hexagonal cells of the elastic lamina are not displaced, and contain their normal quantity of colouring matter, the choroid cannot well be seen. We are consequently unable to detect pathological alterations in this tissue, until the hexagonal epithelium has been removed; but as the cells of this layer are of a most perishable nature, and are usually speedily destroyed in disease of the choroid, we may generally make out any serious changes which take place in it. Less important affections must be often overlooked; for instance, I know of no appearance of these parts which is pathognomonic of œdema, or even of hyperæmia in its early stages. It will be advisable, however, to consider the diseases of the choroid in regular order, though you will readily understand, that the diagnosis between passive hyperæmia and inflammation cannot always be drawn with precision. In almost all serious affections of the choroid, the retina becomes implicated in the disease, though the converse of this does not hold good.

Hyperæmia of the choroid may be acute, and attended with pain and intolerance of light; or it may run a slow and chronic course.

You will frequently meet with cases of *passive hyperæmia*, among persons who are not aware of having anything at all the matter with their eyes. The globe of the eye is of normal tension, the iris responds to the stimulus of light, and, in fact, by external examination, the organ appears healthy. In

the majority of cases of cataract, I believe that some passive hyperæmia of the choroid exists, and, in fact, this form of congestion is about as common among the patients you will be called upon to examine with the ophthalmoscope, as conjunctivitis is amongst our out-patients. Fortunately, this condition does not in itself give rise to impairment of vision, although it often induces changes in the vitreous and lens, which, by impeding the passage of light to the retina, occasion the dimness of sight which sometimes accompanies congestion of the choroidal vessels.

You may meet with cases of passive hyperæmia under circumstances somewhat as follows. A few days ago, I dilated the pupil of one of the coolies belonging to the ophthalmic ward, supposing his eye to be in a normal condition, and intending to show it to some of the students, in contrast with that of a patient suffering from retinitis. I found that this man's optic disc and retina were perfectly healthy; but in place of the fundus of the eye being of a grey colour, the larger vessels of the choroid could be seen meandering about behind the elastic lamina, the interspaces being filled up with islands of black pigment. Plate IX., Fig. 1, represents the appearance of the fundus of this individual's eye. His sight was perfect, and he was a strong robust person; he stated, however, that on several occasions he had suffered from pain in the eyes and supra-orbital region, accompanied with congestion of the conjunctiva and intolerance of light; he remembers having had six or eight attacks of this description, but they usually

passed off in the course of a few days, and he thought very little of them. Supposing that we could continue to watch a case of this kind from time to time for a series of years, we should find the individual gradually becoming short-sighted, and his vision defective, and ultimately, opacity of the lens would supervene. Impairment of vision, in the first instance, being induced by haziness of the vitreous, the nutrition of which is deranged by the altered circulation in the choroid, and subsequently, by degenerative changes in the lens arising from the same cause.

One of the earliest alterations observed in cases of passive hyperæmia of the choroid, is the removal of the hexagonal cells of the elastic lamina from over the course of the larger vessels. Generally speaking, these cells become disintegrated and destroyed, but in some instances they are simply pushed on one side, and afterwards they resume their former shape and position; so that passive hyperæmia may exist for a time, giving rise to these appearances, and ultimately all traces of it may disappear, the parts returning to their normal state. But besides these alterations in the epithelial layer, the stroma of the choroid must be pressed upon to a greater or less extent by the congested vessels in all cases of hyperæmia, and its pigment cells, being squeezed up into dense masses, are apt to become altered in character, and many of them completely destroyed. Although passive hyperæmia, therefore, may apparently continue for years, without causing any impairment of vision, still, as I have above noticed, it is too often the

starting-point of serious disease, and should not, therefore, be overlooked.

I have already said, that impairment of the nutrition, and so of the transparency of the lens and vitreous, are among the most serious effects of congestion of the choroid; should you therefore meet with cases of this description, do not rest satisfied until you have, if possible, got at the root of the evil; inquire carefully as to the occupation and habits of the patient. Passive hyperæmia is often the result of *exhaustion*, and may be caused by overwork, or it may follow a defective innervation of the vascular system, arising either from debility induced by disease, or from self-abuse, a very frequent cause of much evil among certain classes of natives. It is not an uncommon thing to be consulted by young men on account of gradually increasing loss of sight; they are weak, with a small and irritable pulse, and a nervous uneasy manner; there is no history of fever, or other debilitating cause, sufficient to account for these symptoms, nor is there any apparent defect in the accommodation of the eye; but on examination you may detect a well-marked passive hyperæmia of the choroidal vessels, and some slight opacity of the vitreous. In such a case, it will, of course, be all important to determine if overwork, disease, or venereal excess, is the exciting cause of the hyperæmia; under any circumstances you must enforce rest; and, if practicable, direct your treatment towards the removal of the cause of the congestion, not forgetting to insist on the observance of the strictest chastity, where you have reason to

suppose it has been violated, plainly telling your patient the risk he runs if he does not attend to your advice.

Passive hyperæmia may result from *mechanical causes*, such as pressure on the vessels of the eye, or disease of the heart. If from the former, it is probable that some effusion will have taken place into the retina, such as I have already described as occurring in cases of obstructed circulation; and in the majority of cases of heart disease, a marked increase in the pulsation of the retinal veins will be noticed, besides which, there will be the general history and physical signs of the principal malady to aid the diagnosis. You will have to weigh carefully the symptoms attending these various forms of disease, before you can arrive at an accurate idea of the cause of the hyperæmia; but, as I have before remarked, when speaking of the analogous conditions of the retina, it is by the correct appreciation of such slight departures from the standard of health, that your success in practice will mainly depend: they are of every-day occurrence, and are the origin of a vast deal of subsequent irremediable mischief.

In a future lecture I shall describe the history and symptoms of *hypermetropia*, and it is only necessary for me therefore now to mention this condition, as being by no means an uncommon cause of hyperæmia of the choroid. Hypermetropia consists essentially of a want of power in the refractive media, during repose of accommodation, to bring any but convergent rays of light to a focus on the retina. A patient affected

in this way is consequently compelled to exert a more or less considerable accommodative effort, in order to bring even parallel rays, from remote objects, to a focus; and this constant straining of the eye induces hyperæmia of the choroid. All that is necessary, in order to relieve this state of things, is to supply the patient with a pair of suitable convex glasses.

Hyperæmia may pursue a different course from that above described, in which we noticed that the congestion is chiefly confined to the larger vessels of the choroid. If the capillaries also become involved in the disease, the islands of black pigment, between the vessels, are to a great extent concealed by the layer of congested capillaries, which intervenes between the coloured cells of the stroma and the elastic lamina. This is the condition of the parts in *acute hyperæmia of the choroid*. It is, however, impossible to draw any well-defined line between this form of the disorder and *inflammation*; and I shall therefore simply observe, that acute hyperæmia (as distinguished from the chronic and passive forms) must be considered as the first stage of *choroiditis*.

A patient suffering from general sub-acute inflammation of the choroid, *choroiditis diffusa*, complains of fulness and an aching pain in the eyeball, frequently extending to the eyebrow and temple; there is always some intolerance of light and increased lachrymation, together with impairment of vision, and these symptoms are aggravated by exerting the eye. The pupil responds slowly to the stimulus of light, and

takes a long time to dilate after the application of atropine. As the disease progresses, these phenomena are more marked, the tension of the eye-ball is increased, and the vessels of the sclerotic and conjunctiva become more or less congested; the pain is often most acute, and the vision so much impaired as to render the patient almost blind. On examining the deep structures of the eye with the ophthalmoscope, we find that the dioptric media are more or less hazy, the optic disc appears contracted in size from the bulging inwards of its choroidal margin, and of a deep pink colour from congestion. The vessels of the retina are generally of normal size and appearance; but the natural grey reflection from the fundus of the eye is changed into a brilliant red glare, almost as bright as that seen in the eye of a fair-haired European. This appearance arises from the destruction of the hexagonal cells of the elastic lamina, and the universal congestion of the choroid; not only are the larger vessels deeply injected, but the capillaries also, so that the pigment cells of the stroma are concealed, and, in very many instances, broken down and destroyed.

But inflammation of the choroid may be partial; that is, the progressive changes just described, instead of involving the whole of that structure, may be confined to particular parts of it, the remaining portions of the fundus of the eye retaining their healthy appearance. This condition has been described as *choroiditis disseminata* (in contradistinction to *choroiditis diffusa*), and is particularly apt to occur as a consequence of syphilitic disease.

In considering what form of treatment to adopt in cases of choroiditis, you must bear in mind the distinction between the specific and non-specific forms of the disease ; in the former, you will find a course of bichloride of mercury, combined with tonics, the most successful. In the non-specific variety, you should endeavour to discover, if possible, the conditions which have led to the development of the complaint ; thus it may, and often does arise from overwork, among persons of a rheumatic or gouty diathesis, in which case alkalies and colchicum, or the iodide or bromide of potassium will be found most useful, and the latter drug is often of marked service where there is no rheumatic history. Counter-irritation should never be neglected, and you will find that issues opened in the temple have a better curative effect than blisters. Pure air, combined with a generous diet, will be necessary in all cases, and rest must be strictly insisted upon in the acute stages of the disease ; in the more chronic forms, if your patient is obliged to go about in the glare of the sun, he should use a pair of blue-tinted glasses, but the closer he can keep to his rooms during the heat of the day, the sooner will he recover the use of his eyes. In this class of cases, the cold eye-douche cannot be too strongly recommended. Among the natives, it is rare indeed to meet with an instance of choroiditis, even in the acute form, in which you could venture to prescribe local blood-letting ; but nevertheless, it may occasionally be indicated, and then you will find it convenient to employ the artificial leech applied to the temple. I

would advise you, however, never to abstract blood unless there is great pain and intolerance of light, accompanied by irritative fever ; the pain may generally be relieved by one or two subcutaneous injections, and if you use the leech, you should not neglect to employ counter-irritation at the same time. In conjunction with these local measures, constitutional treatment must be carefully maintained, which, among the natives, usually resolves itself into a more generous dietary, and a prolonged course of tonics.

Very many instances of choroiditis appear to arise simply from overwork ; a native employed in an office will write away all day, and when he gets home at night, sit up working before the dim light of an oil lamp. This overstraining of the eyes, particularly when the head is kept in a bent position, and in a person subsisting upon a very low diet, necessarily engenders hyperæmia, and ultimately passive inflammation of the choroid. We may thus, in a measure, account for the numerous cases of opacity of the lens, which we meet with in India among comparatively young men ; the affection of the choroid induces malnutrition of the lens and vitreous, and degenerative changes take place in these structures, terminating, for the most part, in opacity of the former, and a fluid condition of the latter.

Choroiditis, in the sub-acute form which we are now considering, may give rise either to serous exudation, or extravasation of blood into the choroid, or to the formation of plastic exudation in this tissue, or lastly, to suppuration ; I shall return to the considera-

tion of these different results of the inflammatory process by-and-by. There are a class of cases, however, which require special notice in this place, on account of the rapid and dangerous course which the inflammation runs, the patient losing his sight within a few days from the commencement of the attack. The following is a good example of this *acute form* of the disease :—

Kaboleram, aged thirty-five, was admitted into the Hospital on the 22nd of January, 1864; he was a native of the Upper Provinces, and a well-made, robust-looking man. Until about five years previously his eyesight had been perfect; he was then at Lahore, and was suddenly seized with the most violent pain in the left eye, which became very red and inflamed; he speedily lost the sight in it, which he has never since regained in the slightest degree. The pain in the eye-ball continued for some two or three months, and then gradually passed away. The eye is now shrivelled up and destroyed. He did not, however, come to consult me about that eye, but regarding the right one, which had been healthy, and the sight perfectly good, until within three days of his admission, when he was attacked with violent pain in the eye-ball, which extended over the side of the head. The patient was led into the Hospital; in fact he could only just distinguish light from darkness; the tension of the globe of the right eye was T + 2, the pupil was dilated, and the lens and vitreous were hazy, the former being pushed forward so as almost to touch the cornea; there was considerable congestion of the

vessels of the sclerotic and conjunctiva. On examining the eye with the ophthalmoscope, I found that the veins of the retina were congested, the retina itself was œdematous, and the optic disc appeared cupped, from the swollen condition of the choroid. The retinal vessels, after passing over its edge, were evidently on a plane anterior to the one they had occupied when crossing the optic disc, the parts looking at first sight very much as they do in glaucoma. The venous pulse was well marked, but not the arterial. The hexagonal cells of the elastic lamina were destroyed, and the vessels of the choroid could be plainly seen through the retina; and as the appearance of the pigment cells of the stroma was almost entirely lost, I concluded that the capillaries, as well as the larger vessels, were deeply congested. Towards the ora serrata, there were numerous small patches of extravasated blood in the choroid; they did not, however, extend further inwards towards the axis of vision.

As this appeared to be a very favourable case for iridectomy, I at once put the patient under the influence of chloroform, and performed the operation, removing a considerable portion of the upper part of the iris, great care being taken to drag it away from its attachments. The operation was perfectly successful, and certainly its results exceeded my most sanguine expectation. You will observe, that iridectomy was performed on the 22nd of January, at 9 A.M.; the patient was then completely blind, and in the most intense agony. At 2 P.M. I saw him, and he was

almost free from pain ; as the eye had been carefully closed, I did not think it advisable to remove the bandages. At 8 P.M. his condition was equally favourable. On the following morning, I found he had slept well during the night ; he was quite free from pain, and on opening the eye he could distinguish the features of my face. His vision continued to improve till he left the Hospital, when the sight in the right eye had become as good as it had ever been ; the tension of the globe was normal, and the conjunctival and sclerotic congestion had entirely disappeared ; the optic disc and retina were healthy, and though the hexagonal cells of the elastic lamina were destroyed, thus leaving the larger vessels of the choroid exposed, still the capillary hyperæmia had disappeared, and the pigment-cells of the choroidal stroma were again visible.

Before proceeding to make any further remarks on this case, I must call your attention to another of a similar nature, which has very lately been under our observation ; and though the result does not redound much to my own skill, still it conveys a most important lesson when contrasted with the instance above detailed.

Issabally, aged forty, was admitted into the Ophthalmic Hospital on the 5th of November ; he had always enjoyed good eyesight up to within four days of his admission, when he was seized with a violent pain in the right eye, and in a few hours the sight became so dim that he could only see a few yards in front of him. He came to the Hospital, as I said,

four days after the commencement of the attack ; I then found the conjunctiva and the sclerotic much congested.; the tension of the eye-ball was $T + 3$; the pupil was dilated, and did not respond to the stimulus of light ; the lens and vitreous were too opaque to allow of my seeing the retina or optic disc distinctly, but there was evident congestion of the vessels of the choroid ; the lens was thrust forward, and it required care to avoid wounding it in making the necessary incision for iridectomy. There could be no doubt that the proper plan of treatment consisted in the skilful performance of this operation, and the patient was therefore placed under the influence of chloroform ; but before I had completed the requisite opening in the anterior chamber, he commenced vomiting, and the operation was thus delayed. As the man was constantly belching and retching, I was anxious to discontinue the administration of the chloroform as quickly as possible, lest, by these straining efforts, the congested vessels should be ruptured, and destructive hæmorrhage take place into the choroid ; and consequently, I only managed to excise a small portion of the iris, without taking sufficient care to drag it away from its attachments.

In the evening, the pain in the eye had not diminished, and the eye-ball still felt somewhat full, though not nearly so tense as in the morning. The patient, however, suffered from excruciating pain during the following three days ; and as the tension of the eye-ball was then very great, I determined to operate again, and to excise a larger portion of the

iris. This was effectually done, and care was taken, this time, to drag it away from its attachment; in fact, the operation of iridectomy was now performed, and not the mere removal of a portion of the iris, as on the previous occasion. From this time the pain and tension of the eye-ball gradually subsided; but, unfortunately, the three days' delay, between the first and second operation, had been fatal to the patient's vision; the lens during this period had become densely opaque, and doubtless irreparable mischief had been done to the choroid and retina. The globe of the eye, nevertheless, remained of normal tension, and the patient perfectly free from pain.

My principal object, in dwelling on this unfortunate case, has been to impress on your mind this important point in connexion with *the operation of iridectomy*,—that it is not sufficient simply to excise a portion of the iris, but the part removed must be torn away from its attachment, in order to insure the benefits which the operation is capable of affording; unless this point be attended to, you might just as well leave the iris alone, and simply puncture the anterior chamber, allowing the aqueous to escape.

The question naturally arises, How can iridectomy effect such marked benefit as we constantly see following its employment in cases of this kind, attended with increased intra-ocular pressure? I am aware that, in attempting to discuss this question, I shall be entering upon debateable ground, yet I cannot help offering a few remarks on a subject of so much in-

terest ; the operation itself I shall describe more fully when speaking of glaucoma. I have already described the space included between the sclerotic and elastic lamina, as occupied by the structures of the choroid and ciliary processes ; it is evident that, if the nozzle of a fine syringe be inserted beneath the sclerotic, this sac could readily be injected, to such an extent as to make the globe of the eye very tense. In practice, we find that this may be done, and yet not a particle of the injected fluid will escape through the elastic lamina. Suppose, for instance, we inject some of Beale's blue fluid into the choroid in this way, and then slice off the cornea, not a vestige of it will be seen till the hexagonal cells have been removed, when the blue colour will be noticed behind the elastic lamina, extending from the ciliary body to the optic disc. If this space has been carefully and fully injected, so as to make the eye-ball of stony hardness, and if a needle be then passed into the anterior chamber, in front of the iris, and its point be made to press back the pillars of the iris, and puncture the elastic lamina covering the ciliary body ; as soon as this has been done, the coloured fluid will pour out into the anterior chamber through the hole in the elastic lamina ; and as the needle is withdrawn from the eye, and the aqueous humour escapes, its place being occupied by the injected fluid from the choroid, the tension of the eye-ball will completely subside. I cannot help thinking, therefore, that the success of the operation of iridectomy in acute choroiditis, depends upon the fact of the elastic lamina being broken down, and the

effusion behind it escaping into the anterior chamber ; and hence the benefit of the proceeding in the case of Kaboleram, and its failure in that of Issabally.

The wound in the sclerotic, no doubt, heals very rapidly after iridectomy ; but the choroidal effusion may, nevertheless, escape into the anterior chamber and become absorbed. Daily experience teaches us how speedily absorption takes place in this locality, so that we are by no means compelled to suppose that the effusion must pass away through the wound, in order that the tension of the parts may be relieved.

I cannot conceive that an excess of aqueous alone could cause the symptoms of intra-ocular pressure noticed in these cases, and therefore, that the removal of a piece of the iris, by diminishing its secreting surface, can effect much good. The lens, moreover, is invariably thrust forward towards the cornea, which could not be the case unless the effusion were situated behind it ; if an excess of aqueous were the cause of the increased tension, the lens would be pushed backwards into the vitreous chamber. Nor do I think that the removal of a portion of the iris alone will account for the decrease in the tension of the globe after iridectomy ; for, so soon as the wound in the sclerotic has healed, the aqueous must occupy exactly the same space as the excised portion of the iris had formerly done. Thus, in the instance of Issabally, a portion only of the iris being excised, but no opening having been made through the elastic lamina, the operation failed : the pain was not relieved

by the escape of the aqueous humour, and the eye was speedily destroyed. After the second operation, in which I took care to drag a portion of the iris away from its attachments, and thus, as I suppose, to tear open the bag of the choroid, the effusion it contained escaped into the anterior chamber, and the pain from which the patient had been suffering disappeared, the tension of the eye-ball returning to its normal state. The delay, however, was, as I said before, fatal to his sight.

It is evident, therefore, that in cases of acute choroïditiſis, you muſt perform iridectomy completely, and as ſoon as poſſible after the commencement of the attack; the ſight may be entirely deſtroyed within forty-eight hours. If a patient come to you complain- ing of ſudden and acute pain in the eye, extending to the temple and ſide of the head, and if you find the globe is tenſe, the pupil dilated, and the lens and vitreous hazy, the optic diſc, if viſible, being apparently cupped, from the overlapping of its choroidal border, and laſtly, if the veſſels of the choroid and veins of the retina are intenſely congeſted—under theſe circumſtances you ſhould at once perform iridectomy, although, I believe, that breaking through the elastic lamina with a needle, in the manner I have before deſcribed, ſo as to let the effuſion behind it eſcape into the anterior chamber, would frequently anſwer as well. It is no uſe waiting to try what leeches or purgatives will do in a caſe of this deſcription; iridectomy is the only alternative; and, until authenticated caſes of recovery have been recorded, it

would not be sound teaching on my part, to recommend you to trust simply to breaking open the sac of the choroid in cases of such grave importance.

From the above remarks, you will observe, that I consider the form of disease I have been describing as essentially *acute choroiditis*, attended with rapid effusion of serum into the choroid, that is, between the sclerotic and elastic lamina. This affection has an evident tendency to attack first one eye and then the other. I have seen several instances of this kind, but I am unable to give you any information as to the probability of its so returning after iridectomy has been performed; in none of the cases that I have operated on has there been any relapse, although this may have occurred, and yet the fact may not have been brought to my notice. The relief from pain afforded by the operation is instantaneous, and, as in the case of Kaboleram, sight may be perfectly restored; in fact, this result may be invariably expected, I believe, if the operation is skilfully and early performed.

It is seldom that you will have an opportunity of examining the eye of a patient suffering from acute choroiditis in the early stages of the disease, that is, before the lens and vitreous have become hazy; but if you are fortunate enough to meet with an instance of the kind, you will find the optic disc as I have described it, looking smaller than normal, its rounded choroidal margin being very prominent, so as in fact to overlap the disc; the retinal vessels, as they cross the disc, are, consequently, on a plane posterior to

the one they occupy when passing over the surface of the retina, where they are thrust forward by the swollen choroid. As the hexagonal cells are very speedily destroyed, the vessels of the choroid will be seen to be intensely congested, and the fundus of the affected eye will appear of a bright scarlet colour, the cells of the stroma being either at once broken up and removed, or else the congestion so great, that the vascular network entirely conceals them.

The invariable result of this acute form of the disease is total loss of vision, unless the effusion into the choroid be speedily relieved. But you may perhaps ask, Why not then puncture the sclerotic at once, and allow it to escape in this way? Unless, however, the opening in the sclerotic were a minute one, prolapsus of the choroid and detachment of the retina might easily occur; and if the puncture were very small, a sufficiently free opening would not be made to allow the effusion to escape externally, for the sclerotic being a dense fibrous tissue, the opening would close up directly it had been made.

Fortunately, inflammation of the choroid seldom runs so rapid and acute a course as that above described; in fact, these are rare instances of disease, whereas subacute choroiditis is of very common occurrence; and, as I mentioned to you in a former part of this lecture, it may terminate either in resolution, or in the effusion of serum, blood, or lymph, into the choroid; or lastly, in suppuration.

It is, I believe, impossible to detect *serous exudation*

in the choroid with the ophthalmoscope, in the eye of the native, at any rate in its early stages. Effusions of this kind probably often occur without displacing the hexagonal cells; and till these are removed, as I have often told you, we cannot see what is going on behind them. There can be no doubt that serum may be so poured out, and again become absorbed, without inducing any structural alterations in the choroid. It seems probable, that under certain circumstances, the fluid may percolate through the elastic lamina, and collecting behind the retina, cause it to become detached from the hexagonal cells; this condition, however, is of rare occurrence, when compared with the number of cases of congestion, and consequent serous exudation, which we meet with.

Extravasation of blood into the choroid frequently occurs in choroiditis, the clots passing through the same changes as those described in similar affections of the retina. The effused blood, if poured out in any quantity, generally collects in patches of various sizes behind the elastic lamina, and completely hides the vessels and pigment-cells of the choroid. The nervous tissue of the retina, however, can be traced over the patches, and more particularly the retinal vessels; these, together with the remains of the hexagonal cells of the elastic lamina, are sufficient landmarks to guide us in the determination of the seat of hæmorrhage, and in distinguishing extravasations of blood into the choroid, from those into the retina.

It is not uncommon to meet with cases of sudden blindness, coming on after severe straining — for instance, after violent vomiting. Thus a man, perhaps after a night's debauch, is seized with retching, and he wakes up in the morning and discovers that he is blind with one or both eyes. You examine the eye with the ophthalmoscope, but can detect nothing abnormal, and in the course of fifteen or twenty days the patient begins to regain his sight. The most probable cause of an attack of this kind is the rupture of one or more of the vessels of the choroid, and the effusion of blood into its substance. We are frequently unable to see the clot, on account of the cells of the elastic lamina, but we know from analogy, and also from observations made on Europeans, that effusions of blood into the choroid do take place under these circumstances. Such extravasations usually become absorbed very rapidly, and unless of considerable size, and immediately in the axis of vision, are not likely to lead to permanent impairment of sight. If the hæmorrhage has been very extensive, the elastic lamina may be broken through, and the effused blood may tear down the retina, inflicting of course irreparable injury upon its delicate structure.

Hæmorrhage into the choroid often occurs in consequence of an injury or blow on the eye. Attention to the history of the case, and to the ophthalmoscopic appearances, will insure a correct diagnosis; and provided there is no lesion of the retina, or great injury done to the choroid, directly in the axis of vision, you may venture on a favourable prognosis. Should the

hæmorrhage, however, be extensive, it is probable that serious damage will be done to the structure of the choroid, and very possibly a portion of it may be detached from the sclerotic; in which case, the lens and vitreous will most likely degenerate, and ultimately become hazy. You may be consulted as to the probable effect which a lesion of this kind is likely to exercise upon the patient's future prospects, and I believe you may safely remove all fears lest the injured eye should prove a source of impairment to the sound one, through sympathy, provided there is no foreign body present to complicate the case; for it is a matter of experience, that a blow or wound, which has even so far injured the choroid as to induce degeneration of the lens and vitreous, does not set up diseased action in the other eye; and a patient, under these circumstances, may safely continue his work, without fear of any ill consequences, so far as the uninjured eye is concerned.

The *formation of lymph* in the choroid is by no means an uncommon result of inflammation; fortunately, however, in the majority of instances, it is re-absorbed. It usually appears as a light, whitish-brown streak, external to, and following the course of the larger choroidal vessels, but here and there accumulating in nodules, like those noticed in iritis; while in this condition it may be entirely removed by absorption. Should the lymph become organized, it gives rise, as in other situations, to white-looking patches, which may be distinctly seen with the ophthalmoscope; their position may be ascertained by

reference to the vessels of the retina, and the remains of the hexagonal cells, both of which must be anterior to the exudation. The retinal vessels form a particularly good landmark: as they cross over the white patch, they are thrown out into bold relief, showing that the effusion is not in the retina, but in some of the structures posterior to it. It may be a matter of doubt, however, as to whether these appearances are due to plastic exudation, or to detachment of the choroid from the sclerotic, or to atrophy; and the distinction is one of importance in a practical point of view, as a judicious course of treatment may do much to facilitate the absorption of effused lymph, whereas it would be useless in detachment or atrophy of the choroid. In the latter form of disease, if the atrophy be partial, the affected portions of the choroid will appear of a dirty brown colour, in consequence of the remains of the choroidal pigment adhering to the sclerotic; in the majority of cases, a few choroidal vessels will be seen coursing over the parts; and lastly, the margins of the atrophied spots are usually marked by a border of black pigment. If the atrophy be general, the hazy lens and vitreous, together with the symptoms to be presently noticed as characteristic of this form of disease, will at once remove all doubt from your mind as to its nature. In the case of detachment, the choroid may be seen, either bent back, or else floating about in the vitreous; with the binocular ophthalmoscope the sides of the torn structures may be distinctly defined, and through the rent, the glistening whiteness of the sclerotic will be very

apparent, some shreds of pigment usually remaining attached to it.

Plastic exudations, besides forming patches in the choroid, almost always follow the course of the larger vessels, which become lined by a border of whitish organized lymph; and it is not uncommon to find the fundus of the eye presenting the appearance of a very fine silver gauze, stretched out behind the retina, through which the vessels of the choroid appear like silver cords. This condition is occasioned by the presence of a thin layer of organized lymph, situated posteriorly to the elastic lamina, and by the exudation external to the walls of the choroidal vessels having become organized, so as to form a white envelope round them.

We have lately had a very marked instance of this kind attending the Hospital. The patient, Marum, came under our notice on the 16th December; he was apparently a strong and healthy individual, but had suffered from gradual loss of sight for the past ten months, with an occasional aching pain in the eye, extending over the temple. His sight had become so far impaired, that he could no longer continue his employment as a shopkeeper. I found the tension of both eye-balls slightly increased; there was no congestion of the conjunctiva or sclerotic, and the external appearance of the eye-ball was healthy. The pupil took a long time to dilate after atropine had been applied to the eye, and this circumstance, alone, led me to suppose that there was disease of the choroid. With the ophthalmoscope, I found the deep parts presented

very much the appearances described above, as of a silver gauze, behind which the enveloped vessels of the choroid could be seen. As the disease, in this case, had been steadily progressing for months, I did not expect the patient would derive much benefit from treatment, more particularly as there was no history of syphilis; I ordered him, however, iodide of potassium, and subsequently bichloride of mercury; issues were also opened in the temples. As the patient did not improve under this treatment, after pursuing it for two months, and as his general health was remarkably good, I discontinued all medicines for a time; but by a prolonged use of bromide of potassium, I hope, if not to improve the man's sight, at any rate to stop the progress of the disease. I have sometimes seen these plastic exudations in the choroid entirely disappear under the influence of appropriate remedies, especially among young and robust people, and where the lymph has not become fully organized.

Suppuration of the choroid may follow inflammation; in fact, from constitutional or other causes, the effused lymph, in place of becoming organized, may degenerate into pus, and the suppurating process, having been once established, is almost certain to terminate in the destruction of the eye. These changes in the choroid cannot be observed with the ophthalmoscope, as the lens and vitreous always become so opaque, prior to the commencement of suppuration, that it is impossible to observe the changes going on behind them. The symptoms, however, of increased pain and tension of the eye-ball, and the appearance of pus in the an-

terior chamber, speedily furnish unmistakable signs of the nature of the disease.

It sometimes happens that *tubercular matter* is formed in the choroid. It is generally found amongst persons of a scrofulous diathesis, or those actually suffering from phthisis, and it is usually supposed, that the accompanying impairment of vision is due to an anæmic state of the retina. If, however, a patient's eye be examined under these circumstances with the ophthalmoscope, patches of rough tubercular matter will be seen; they generally appear near the ora serrata, and as they gradually increase in size, they push the pigment-cells of the choroid on one side; their outline is consequently marked by a border of black pigment, and their raised and uneven surface can hardly be mistaken for any other condition of the parts. As the disease advances, the functions of the choroid become impaired, and the vitreous passes into an opaque condition, rendering all further changes in the structures posterior to it very indistinct. It does not appear that the tubercular masses themselves excite irritation in the choroid, nor do they induce any pain in the eye. The impairment of vision, noticed in these cases, is not directly due to the tuberculous exudation, but to the disseminated disease of the choroidal vessels; the walls of which will be found infiltrated with earthy matter, causing atony of the ciliary muscle, and a hazy state of the vitreous. No doubt, if the tubercular matter were formed directly in the axis of vision, it would, by displacing the retina, destroy its functions to some

extent; but it does not often happen that it is situated in this particular spot, and consequently, as above stated, it is seldom the immediate cause of loss of sight.

In this form of disease, I need hardly say, that our first object will be, if possible, to arrest the formation of tubercle, and we may even hope for the removal of that already existing in the choroid, if we can place the patient in an advantageous position as regards pure air, exercise, and generous living; but these are just the very things which it is so difficult to enforce among native patients, and without them, no amount of cod-liver oil, or anything else that I know of, will be of the slightest service towards relieving the diathesis and the accompanying choroiditis.

General atrophy of the choroid, as distinguished from the partial form, may follow inflammation, or the disease may gradually come on without any such exciting cause. However induced, the calibre of the choroidal vessels gradually diminishes, and they ultimately dwindle away to mere threads. The fundus of the eye then presents a dingy, brownish hue; for, as the vascular supply gradually diminishes, the other structures of the choroid degenerate, and the material, from the disintegrated pigment-cells of the stroma, is left attached to the inner surface of the sclerotic; it is the light reflected from this discoloured surface, which occasions the dirty brown tint above noticed. General atrophy of the choroid cannot, however, be traced with the ophthalmoscope up to this stage of the disease, but is

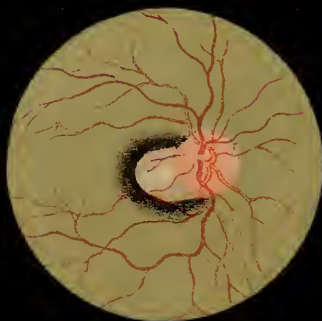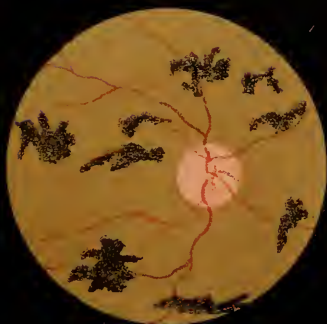
only to be detected on *post-mortem* examination ; for if the choroid has become altogether atrophied, the lens and vitreous will be so far altered in character as entirely to conceal the fundus of the eye.

Atrophy, however, may occur *in patches*, following choroiditis disseminata ; in which case the appearances above described will be limited to the degenerated portions of the choroid, and may be distinctly traced by the aid of the ophthalmoscope. Fig. 2, Plate IX. is drawn from the eye of a patient suffering from this form of disease.

Kally Doss, aged forty, applied for relief at the Hospital on the 6th of January, 1865. He was a strong, healthy-looking man, by occupation a baker at Benares. He stated that he had perfectly good vision up to within the last eighteen months, when he began to suffer from pain in the eye-balls ; he attributed this to overwork. He soon discovered that he was growing short-sighted, and that the impairment of vision was much increased after a hard day's work. In the course of a few months, these symptoms became so much augmented as to give him great uneasiness, and if he attempted to use his eyes, he suffered from an aching pain extending to the temples, and also from some intolerance of light. The loss of vision has been very gradual ; at present, he can just distinguish a person's features with the right eye, but with the left, he can only see the shadows of opaque objects held between him and the light ; the tension of both eye-balls is normal ; the pupils being dilated, the lens appears opaque. It was on this last account

especially, that he had come to me ; he believed the disease he was suffering from to be simply cataract, and that its removal would restore his sight. With the ophthalmoscope, however, I discovered that the optic disc of the left eye was of normal size and colour, the calibre of the retinal vessels was diminished, and the choroid presented the appearance shown in Fig. 2, Plate IX., the dark patches being the atrophied structure, with spots of pigment scattered over it. A few retinal vessels could be seen coursing over the choroid.

Patches of atrophied tissue may remain stationary for months and years, without the disease progressing further, or involving other portions of the choroid ; but, of course, it is impossible to hope for any improvement from treatment in a case of this kind, though much may be done towards preserving that portion of the choroid which is in a comparatively healthy state, and thus preventing the patient from becoming completely blind.



LECTURE IX.

Diseases of the Choroid resumed. Tiger-striped Retina. Sclero-choroiditis Posterior. Stationary and Progressive Forms. Results. Staphyloma of the Optic Disc.

IN my last lecture, I described the symptoms and treatment of some of the more marked diseases of the choroid, and, as you may remember, I divided hyperæmia of its vessels into two kinds: the passive, a common affection, unaccompanied with pain or any prominent symptoms, but nevertheless, gradually leading to degenerative changes in the dioptric media; and active hyperæmia, which is the first stage of inflammation. We saw that choroiditis may give rise to serous or sanguineous effusions, to the formation of lymph or pus in the choroid, or to atrophy of the nervous structures, the lens and vitreous at length becoming opaque, and preventing our observing any of the subsequent changes which take place.

Either one or all of the above lesions may arise from the effects of inherited syphilis, and this you should bear in mind; for if the disease be detected in time, before the degenerative changes have run their course, they may almost always be checked by the use of appropriate remedies. It would be useless

entering again upon a description of the treatment to be employed in cases of this kind ; this I have already done in my third lecture, when giving an account of some of the more important of these syphilitic degenerations. In my last, I described the ophthalmoscopic appearances of the fundus of the eye, when affected with syphilitic choroiditis ; and I shall now only add that, whether the constitutional disease be primary or inherited, the local changes will be precisely similar ; in the latter case, however, they usually appear soon after birth, or at any rate before the patient has reached the age of sixteen, which could not well happen if the disease had been the result of primary infection.

Before leaving this subject, I may briefly refer to an affection of the choroid, which, in its progress, involves the retina ; it has been described and figured by Liebreich as the *tiger-striped retina*. He says it is most commonly met with among the offspring of persons nearly related to one another ; but this can hardly be the cause of the disease among the natives of India, as they are most scrupulous in observing the restrictions they place upon the intermarriage of relatives, and yet I have seen some twelve or fifteen instances of the tiger-striped retina among my native patients within twelve months. Free colouring matter from the blood may be deposited in the retina, giving rise to the formation of black, irregular-shaped bodies in its substance, and ultimately to atrophy of its nervous structure ; but these cases are not to be confounded with those now under consideration.

In all the instances of genuine tiger-striped retina which I have seen, there has been a distinct history of impairment of vision, commencing soon after birth, but not, probably, sufficiently marked to attract much attention in early life ; nevertheless, if careful inquiries be made, the defect of vision may usually be traced back to infancy. I am disposed to look upon the disease as a result of inherited syphilis. I have never been able to refer these symptoms to the effects of any of the so-called inflammatory changes ; the disease seems to me to be one of a degenerative character, progressing very slowly, and often becoming stationary for years. The only facts, which, in my mind, are opposed to this view of its relation to syphilis are, that I have not noticed the notched teeth, nor have I seen the affection in more than one member of a family ; and lastly, the disease does not seem to be influenced in the least by a specific, or any other mode of treatment with which I am acquainted.

As I have before stated, the tiger-striped retina is a disease which commences in early life, although it may not be noticed till after the patient has reached the age of manhood. It runs its course without the slightest pain, and the external appearance of the affected eye is probably healthy, the symptoms usually complained of being a gradual loss of sight, most marked after sunset. The field of vision becomes much contracted, and ultimately the patient's sight is almost lost ; notwithstanding this, the iris may remain healthy, the pupil dilating and contracting freely, and the dioptric media continue transparent.

On examining the eye with the ophthalmoscope in childhood, that is, in the early stages of the disease, the optic disc and retinal vessels appear of normal size; the retina is more or less œdematous, and the superficial and deep layers of the choroidal vessels are congested; this is particularly the case towards the ora serrata, and in this situation, minute dots of colouring matter, like that contained in the hexagonal and pigment-cells of the choroid, may be seen from the commencement of the disease. These spots of pigmentary matter appear to grow, spreading out their roots among the nervous elements of the retina; but before they have become developed to any considerable extent, further changes may be observed in the stroma of the choroid: it becomes atrophied, and the circumference of the optic disc is consequently flattened; the calibre of the choroidal vessels is contracted, but their channels are not occluded, so that the dioptric media remain transparent.

While these changes are going on in the choroid, the black pigment-spots continue to grow in the retina, pushing its nervous elements on one side, and spreading gradually from the periphery to the axis of the eye; the retinal vessels become atrophied, and ultimately, when the patient has nearly lost his sight, the eye presents the following appearances: Optic disc of normal size, and of a pale rose colour, not particularly depressed in its centre, but looking flat, and no choroidal margin to be seen; retinal vessels dwindled away to mere threads, extending probably only a short distance beyond the margin of the disc; the fundus of the eye

has a mottled, yellowish appearance, and is covered with a number of black, spider-shaped bodies ; these are particularly distinct towards the ora serrata.

I do not remember to have met with a case, in which a person, under forty years of age, has been rendered completely blind from the effects of this form of disease ; it usually takes years to advance from the stage characterized by the symptoms of hemeralopia to that of general impairment of vision ; but its progress, though slow, is sure. I have tried every means to stop it, but have never succeeded in doing so ; the atrophy of the choroidal stroma, and the growth of the pigmentary deposits in the retina, continuing in spite of our best efforts. We must therefore give an unfavourable prognosis to patients suffering from this disease ; we may console them with the fact, that its development will be slow, and may possibly be arrested by nature for several years at any stage of its progress ; but beyond this, no reasonable hope can be entertained of improvement, much less of recovery.

It appears, therefore, that the affection known as the tiger-striped retina, commences either as a congenital defect, or from some form of inherited dyscrasia, which subsequently induces permanent disease of the choroid and retina. In the majority of those cases which have come under my notice, syphilis appears to have been at the root of the evil, the effects of which, beginning in the cellular structure of the choroid, continue, till fatty degeneration and atrophy of the stroma supervene. The accumulation of

pigment in the retina is composed of a material similar in its nature to that contained in the cells of the stroma and elastic lamina; it does not appear to destroy or replace the nervous elements of the retina, but to take root and grow in it, pushing its elements on one side.

As these changes approach the axis of vision, they of course cause permanent injury to the retina, and consequently loss of sight. In a case which I had an opportunity of examining after death, a short time since, I was struck with the healthy condition of the yet remaining nervous elements. There does not appear to me to be any evidence of the pigmentary matter passing from the choroid into the retina; on the other hand, the coloured cells of the stroma are the very first elements that suffer; the elastic lamina becomes thickened, not from increased growth, but from the remains of the hexagonal and choroidal cells which become incorporated with it, thus augmenting its thickness, and causing it to assume a brownish-yellow colour. It is upon this substance that the black pigment growths are formed, which produce the appearance that has given rise to the name of the tiger-striped retina. There can be no doubt that, in some cases of choroiditis, the elastic lamina is destroyed, and the colouring matter of the choroidal stroma is to be found among the elements of the retina; but instances of this description are distinct in their symptoms and progress from those of the tiger-striped affection. The peculiar colour of the fundus of the eye in this complaint, certainly does put

one in mind of a tiger's skin, though I never saw a tiger with star-shaped spots over his body. I am not, however, disposed to quarrel with this designation, it is far more apt than many others of a similar kind, and the appearance, being compared to something with which you are familiar, is more likely to make a lasting impression on your minds.

I must now pass on to consider, briefly, another important affection of these parts, known as *sclero-choroiditis posterior*, or *staphyloma scleroticæ posticum*. I cannot do better than quote a passage from Carter's translation of *Zander*, page 179, on this subject.

“The recognition of this disease, so common as to be the cause of four hundred and twenty cases of amblyopia in a thousand, is so far easy, according to Von Gräfe, that the observer has usually to direct his attention only to the entrance of the optic nerve.

“He will there remark a white figure inclosing the outer margin of the nerve. In the early stages this figure is sickle-shaped, its concave margin in a certain degree coincident with the margin of the nerve-disc, while its convex margin looks towards the posterior pole of the eyeball. As the disease progresses, the white figure continually increases, so that its outer border extends farther from the nerve, and the whole patch changes its sickle-shaped outline in various ways; sometimes extending itself outwardly, and assuming the aspect of a horizontal band proceeding from the papilla; sometimes spreading upwards and downwards, and appearing as a white figure of very

variable outline surrounding the outer border of the nerve, and separated from the surrounding fundus by an angular and indented margin. Lastly, the degeneration may also encircle the inner side of the nerve-entrance, so that the latter appears as an island inclosed in a white or sometimes a bright green coloured surface, the outer part of which, however, is always more developed and broader than the inner. The light reflected from the diseased surface exceeds every other ocular reflex in its intensity, and is much brighter and whiter than that from the optic nerve; so that the latter appears comparatively less illuminated, and of a dull grey or reddish tint."

"The retinal vessels can be distinguished upon the white diseased surface more clearly than in the normal state; and, since the observer can perceive even the finest branches, it is very easy considerably to over-estimate the actually existing hyperæmia of the retina. Another error dependent upon the illumination is, that the retinal vessels appear to vanish at the periphery of the white figure, and to be lost either in the deeper parts of the textures or in the accumulations of pigment, an error depending upon the fact that the vessels become less evident as they pass over to a darker background."

The above description of sclero-choroiditis posterior, as observed in the eye of the European, does not exactly apply to the native of India. The degenerative changes described, around the whole or a portion of the optic disc, doubtless occur; but in their early stages, when it is most important to recognise them,

the alteration in the pigmentation of the affected part is often very slight indeed. The disease may in fact run its course, ending in fluidity of the vitreous and detachment of the retina, without the affected portion of the choroid losing its dark colour; consequently, it is difficult, at times, to discover the existence of sclero-choroiditis in the eye of the native, and you will have to examine the part most minutely in order to detect it in its early stages.

Cases of sclero-choroiditis may be divided into two classes; in the first, may be placed those in which the disease is *stationary*, and in the second, those in which it is *advancing*.

In the former, the patient suffers more or less from myopia, which may not have been noticed until he reached the age of twelve or fifteen years. I have seen several cases in which the defective vision was first discovered upon a boy's attempting to decipher words or figures on a black-board, at a distance of thirty or forty feet, or in some such way; his fellow-students could probably readily make them out, but they appeared hazy and ill-defined to him, unless he went up to within a few yards of the board. He may never have suffered from any pain in the eyes, and upon a casual examination, they appear, to be perfectly healthy, and with the exception of the myopia, there is no obvious impairment of vision. The eyeball, perhaps, is rather more prominent than usual, but this is not a constant symptom, and is unimportant as a means of diagnosis. If you examine the eye with the ophthalmoscope, in a well-marked

instance of this kind, you will be struck by the appearance of the optic disc, which seems to be distorted in shape and altered in size, while the retinal vessels are healthy. On further inspection, you may notice, that at the outer circumference of the disc, the hexagonal cells have been partially destroyed, and the stroma of the choroid is more or less blanched, so that some of the rays of light are reflected back from the sclerotic, the diseased part thus appearing of a light grey colour; its outer border is well defined by a rim of black pigment, beyond which, again, the fundus of the eye appears healthy. In the majority of these cases the choroid and sclerotic project backwards at this spot, forming a *posterior staphyloma* as it is called.* These appearances are represented in Fig. 3, Plate IX.

The abnormal condition above described may remain stationary for years, and in fact for life; but on the other hand, active changes may at any time be set up, and you should explain this fact to your patient, informing him, that if the eye begins to trouble him, if he gets an aching pain over the brow after exerting it, or if the glare of the sun is felt to be

* Donders considers, that in *staphyloma posticum*, together with atrophy of the choroid, an abnormal separation of the two divisions of the sheath of the optic nerve exists. The outer sheath, he states, runs into the sclerotic, and the inner one envelopes the trunk of the nerve as far as the choroid; the two are separated by loose connective tissue. It is, first, the inner layer bulging backwards, together with atrophy of the choroid, that give rise to the symptoms of *staphyloma posticum*. This condition of the parts is congenital, but is increased in after life by causes which induce congestion of the fundus of the eye.

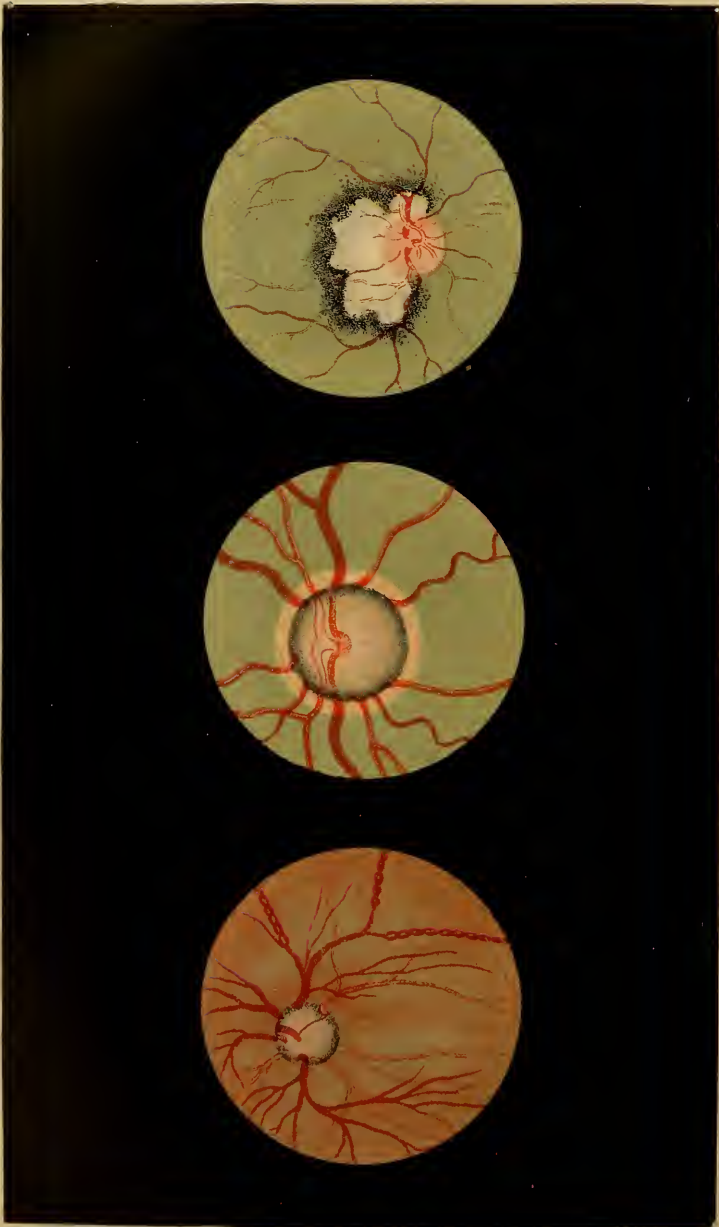
particularly dazzling and uncomfortable, the sight becoming somewhat hazy—that these symptoms indicate advancing mischief, and should be at once attended to. Supposing, however, no such complications occur, you may content yourself with simply ordering a pair of concave glasses, to correct the myopia, and caution your patient particularly not to overwork his eyes, and to use the cold water douche at least twice every day. It will be well also to order him a pair of blue-tinted glasses, which he should always wear when exposed to the glare of the sun.

Before describing the progressive form of sclero-choroiditis, I must draw your attention to the fact, that sometimes a congenital defect exists in the eye of the following kind: A portion of the choroid, immediately around the optic disc, and for a variable extent beyond it, is entirely deficient, so that the sclerotic is seen as a glittering membrane (like that noticed by Zander in the eye of the European suffering from sclero-choroiditis), the remainder of the choroid being of normal appearance. In these cases, defective vision will probably have been observed from childhood, but with the ophthalmoscope, several of the appearances described above as pathognomonic of sclero-choroiditis, will be wanting—there is an entire deficiency of colouring matter, and no marked line of pigment surrounding the outer rim of the diseased part. A correct appreciation of the differences between these abnormal appearances is important, because, in the case of the simple congenital defect, no

ulterior consequences are likely to follow, and medical treatment is utterly useless, which is not the case in sclero-choroiditis. I shall have an opportunity, on a future occasion, of explaining to you how it is that prismatic glasses may sometimes prove serviceable in cases of this kind, but that beyond this nothing can be done for the patient.

We may now proceed to consider the symptoms and treatment of *progressive* sclero-choroiditis posterior. A patient suffering from this malady, will tell you, perhaps, that he has been myopic for some time; he does not consult you, however, on this account, but for general impairment of vision, which increases after over-exerting his eyes. At such times he complains of an aching pain in the orbit, extending to the temple, and also of more or less intolerance of light; the glare of the sun is extremely trying, and induces not only an uncomfortable aching feeling in the eye, but also photophobia. He may have suffered from repeated attacks of this kind, lasting for a month or six weeks, and then passing off; reappearing, however, after unusual exertion of sight, or derangement of the general health. After each attack the sight becomes dimmer, till at length all perception of light is lost.

If an eye affected in this way, be examined with the ophthalmoscope in the early stages of the disease, the fundus appears healthy, with the exception of a portion surrounding more or less of the disc, where, usually on the outer side, a patch of choroid will be observed of a lighter grey colour than normal, the



vessels of the part being congested, (*vide* Fig. 1, Plate X.) The alteration in the colour of this spot will be most marked near the disc, from thence, passing through a gradation of shades, it ultimately merges into that of the normal tissue. Irregular patches of black pigment will be seen scattered over the external border of the diseased spot, but the strongly-marked ring of pigment, pathognomonic of chronic sclero-choroiditis, is never seen. In fact, the difference between the two forms of disease consists in this, that in the progressive affection, owing to the active changes which are going on in the part, the line of demarcation between the diseased and sound tissue has broken down, and the degenerative process is extending outwards, or more probably in every direction.

As before stated, an attack of this kind may pass off in the course of a few weeks, but the injury done to the tissues, during the time it lasts, cannot be repaired. The process appears to be essentially one of a degenerative nature, and not inflammatory; at any rate no lymph is formed, nor does suppuration ever occur, so far as I am aware; but the stroma of the choroid, and the corresponding portions of the sclerotic, pass into a state of fatty degeneration; and as the latter loses its power of resisting the internal pressure of the vitreous, a posterior staphyloma is produced. This condition having once commenced, at each fresh attack, the protrusion increases in dimensions, until it often becomes of considerable size.

This accident, however, is by no means the only

ill effect which is likely to follow sclero-choroiditis posterior; opacity and fluidity of the vitreous, and detachment of the retina, are unfortunately too frequently the direct result of this form of disease. The former affection will be recognised at once: on examining the eye with the ophthalmoscope, a number of black, flocculent-looking shreds may be noticed floating in the vitreous; these will be best observed, as I have before explained to you, by the direct method of examination; they are to be seen whisking about in all directions, upon the slightest movement of the eye, causing the patient the greatest annoyance. The state of the choroid may often even then be observed through the fluid vitreous; if not, examine the other eye carefully, and the chances are, that sclero-choroiditis posterior will be detected in it, and thus we may be able to form a tolerably safe conjecture as to the cause of the fluid vitreous in the diseased eye.

During the progress of this affection, detachment of the retina is likely to take place; for if the staphyloma project backwards to any extent, one of two things must occur: either the retina will be stretched in following the sinuosities of the choroid, so that it will be torn across, or else, in bulging backwards into the staphyloma, it will be dragged away from its attachments, either at the optic foramen, or ora serrata, or at both. If the dioptric media are sufficiently transparent, we may watch these changes with the ophthalmoscope; frequently, however, the vitreous becomes so hazy that the retina cannot be seen, though we

may be pretty well assured of its disorganized condition, by the almost complete loss of vision from which the patient suffers.

It is absolutely necessary, therefore, that we should do all in our power to stop the progress of sclero-choroiditis in its early stages, in order to prevent the occurrence of these unfortunate terminations. I have already described the leading symptoms and ophthalmoscopic appearances in chronic sclero-choroiditis ; if, therefore, you find a case presenting these features, and learn that there has been any recent aggravation of the symptoms, you should make careful inquiries regarding the patient's employment, habits, and general state of health, with the view of correcting whatever may be wrong. Very often overwork, or excess in eating and drinking, are the exciting causes of the attack ; under any circumstances you must enforce absolute rest of the eye, and the cold douche should be used three times a day.

In addition to these general measures, if the patient is of a bilious temperament, administer an active purgative, and apply two leeches to the temple for three consecutive nights, fomenting the part well afterwards. The patient should be put on low diet, and be kept in a dark room, until all symptoms of pain and intolerance of light have passed away ; he may then be permitted to take exercise in the open air, wearing a pair of blue glasses when exposed to the glare of the sun or lamp light ; but he must not be allowed to resume his work, until you find that the congestion of the choroid has completely disappeared. In by far the

larger number of instances, however, met with in this country, the patients will be found to be anæmic subjects, in which case, attention to the state of the bowels, together with the cold douche and rest, will be the chief curative means at our disposal. Leeches must never be used under these circumstances, but an issue should be opened in the skin of the temple. A plain, non-stimulating, but generous diet should be enjoined, and the general health improved in every possible way, not overlooking regular exercise. To keep the eyes at rest, a pad of cotton-wool, retained in its place by a light bandage, may be worn with advantage for several hours during the day; in fact, the longer a covering of this description is kept over them the better, unless it produce a heated and uneasy sensation in the part, when it should be discontinued for a time. By a judicious plan of treatment of this kind, the symptoms indicating active changes in the choroid will gradually subside, and the patient may then be allowed to use his eyes, though he cannot be too careful not to strain them. If these precautions are strictly observed, we may with confidence hope to preserve our patient's sight; taking care, whenever the uneasiness or pain in the eyes returns, to have recourse to a plan of treatment similar to that above described, so as to prevent the destructive changes, which follow each attack, from making further progress.

If the vitreous has already become fluid, and the black shreds which float in it are annoying to the patient, an issue should be kept open in the temple

for a month or six weeks, and his general health carefully attended to; the cold-water douche and rest being also employed. Lastly, if the retina has become detached in the progress of this disease, no hope of permanent amendment can be entertained; but if only one eye is affected, you may endeavour to save the other one, by adopting some such plan of treatment as that I have above recommended.

Staphyloma of the optic disc is occasionally met with as an uncomplicated affection. Von Gräfe says, "That in the present state of our knowledge, the lesion of the optic nerve alone is no longer to be considered as defining glaucoma, because in a series of cases it has a pathogenesis quite foreign to glaucoma." As an illustration of the accuracy of this statement, I may refer to a case now under observation, among the out-patients of this Hospital.

Shreenauth Mullick, aged fifty, applied to me on the 4th of January, 1865, for a certificate; he stated, that with the right eye he could scarcely see at all, and that as the left one was becoming dim, he was afraid he should lose the sight in it also, if he continued to work any longer as a writer. On questioning him, I discovered that twelve years ago he had been under the care of Dr. Martin; he was then suffering from gradual loss of vision in the right eye, attended with pain in the head, but not in the eye-ball; he was bled and took mercurials, after which the pain speedily left him and has never returned, but the sight was gradually lost. He has done his

work regularly, as a writer in a Government office, ever since, the affected eye being now in precisely the same condition as it was twelve years ago. Within the last six months, the left eye has begun to grow dim. On examining it, I found a cataract forming, but in other respects it was perfectly healthy. The tension of the right eye was normal, the iris healthy, and the dioptric media clear; but the optic disc was of a perfectly white colour, and deeply cupped, the sides of the depression being perpendicular, so that the vessels, after entering through the disc, appeared lost on its sides, and again became visible as they bent over its margin; they seemed healthy and of normal colour. The nervous tissue of the retina was opaque, and in some places evidently atrophied, but beyond this, the white appearance, and deep depression or retraction of the disc, were the only marked features of disease. In this case, there was not a single symptom of glaucoma present, beyond the cupping of the optic disc; and from the man's history, we may, I think, conclude that this condition of the papilla had existed for some twelve years. It was impossible to discover the cause of these changes: whether the atrophy occurred first, and subsequently the cupping of the disc, I am unable to say; but the appearance of the part led me to suppose, that rupture of the fibres of the optic nerve had occurred in consequence of the staphyloma of the cribriform fascia. It is evident from the fact of the tension of the globe being normal, that intra-ocular pressure was not the immediate cause of the cupping of the disc;

and from the transparent state of the dioptric media, the healthy condition of the choroid, and the entire absence of the proper symptoms of glaucoma, we are, I think, quite warranted in stating, that whatever the pathology of the disease may have been, the process which ordinarily induces glaucoma had nothing to do with it.

LECTURE X.

Mode of Registering the Tension of the Eye. Investigation of the Nature and Cause of Glaucoma. General History and Symptoms. Ophthalmoscopic Appearances. Treatment by Iridectomy. Details of the Operation. Iridectomy in other Affections.

IN this lecture I shall endeavour to give you a short account of the symptoms and treatment of *Glaucoma*; but before doing so, I must request your attention to Mr. Bowman's method of determining the *tension* of the eye-ball. The patient is directed to close the lids of the eye under examination, the surgeon then places the tip of one forefinger on the outer part of the eye-ball, exerting gentle pressure on the opposite side of the globe with the other finger; the amount of resistance offered indicates the degree of tension. In its healthy state, the globe can be easily dimpled, but in chronic glaucoma it becomes of stony hardness. Mr. Bowman remarks:*

“I have found it possible, and practically useful, to distinguish nine degrees of tension, and for convenience and accuracy of note-taking, have designated them by special signs. The degrees may be thus exhibited:

* See Report of a Paper read at the Meeting of the British Medical Association, Aug. 5th, 1862. *British Medical Journal*, vol. ii. p. 378.

“ T. represents *tension*, T. N. *normal tension*. The interrogative (?), marks a *doubt*, which in such matters we must often be content with. The numerals following the letter T, on the same line, indicate the *degree of increased tension*; or if the T be preceded by —, of *diminished tension*, as further explained below. Thus :—

T. 3. *Third degree, or extreme tension*. The fingers cannot dimple the eye by firm pressure.

T. 2. *Second degree, or considerable tension*. The fingers can slightly impress the coats.

T. 1. *First degree, slight but positive increase of tension*.

T. 1. ? Doubtful if tension increased.

T. n. Tension normal.

— T. 1. ? Doubtful if tension be less than natural.

— T. 1. First degree of reduced tension. Slight but positive reduction of tension.

— T. 2.) Successive degrees of reduced tension, short

— T. 3.) of such considerable softness of the eye as allows the finger to sink in the coats. It is less easy to define these by words.

“ In common practice, some of these may be regarded as refinements; but, in accurate note taking, where the nature and course of various diseases of the globe are under investigation, I have found them highly serviceable, and they have as much precision as perhaps is attainable or desirable. It is also to be borne in mind that the normal tension has a certain range or variety in persons of different age, build, or temperament; and according to varying temporary

states of system, as regards emptiness and repletion.”*

In a former lecture, I noticed the appearances which the *excavated optic disc* presents when examined by the ophthalmoscope, and I then remarked, that this abnormal condition may arise from various causes.

First, from congenital defect; in which case the circumference of the excavation may not include the whole of the papilla.

Secondly, from atrophy of the nerve and retraction of the disc, the sides of the excavation sloping gradually downwards from the circumference to the centre of the papilla; the atrophied retinal vessels may be seen crossing over the disc.

Thirdly, the excavation is said to arise from the disc being thrust back by increased intra-ocular pressure. In this case, the whole of the disc is involved, and the retinal vessels are apparently interrupted in their course over it: they seem to terminate in small hook-like processes at its circumference, as shown in Plate X., Fig. 2; and on crossing the disc, they appear, not only on a plane posterior to the retina, but also situated either above or below their continuation at the margin of the papilla.

It is this latter form of excavation which is commonly supposed to be characteristic of glaucoma, and

* In employing these signs in the present lectures and elsewhere, I have found it more convenient to write $T + 1$ for T. 1., $T - 1$ for -T. 1., and so on.

on this subject I have a few observations to offer. When describing the appearance of the fundus of the eye in acute choroiditis, with effusion behind the elastic lamina, I mentioned that the disc looked as though excavated, from its choroidal margin being thrust forwards; and if the effusion lead to hypertrophy of the choroid, this appearance of the papilla will become permanent. Under these circumstances, the vessels, as they cross the disc, are really in their normal position, but beyond its margin are pushed forwards by the effusion behind the elastic lamina. It occurred to me, that a similar condition of the parts might account for the appearances in glaucoma. I by no means deny that in many chronic cases of that malady, the lamina cribrosa does protrude backwards; but I believe, that in most of these instances that defect arises from congenital malformation of the part, the glaucomatous hardness of the globe being a subsequent affection, due, in the majority of cases, either to effusion into, or hypertrophy of the choroid.

In proceeding to give my reasons for having arrived at this conclusion, I shall first observe, that in the early stages of glaucoma, the retinal veins are always more or less dilated, and generally very tortuous, presenting at times a peculiar beaded appearance, as shown in Plate X., Fig. 3. The arteries on the other hand are contracted; but you will especially notice, that in both sets of vessels a *distinct pulsation* is to be seen; should it not already exist in the arteries, it may be induced by the slightest pressure

exerted on the globe of the eye. In the next place, I would request your attention to the results of the two following experiments.

Exp. 1.—If you get a white rabbit, and having given him chloroform, take a syringe with a very fine needle-pointed nozzle, and filling the instrument with water, thrust its point through the sclerotic and slowly turn down the screw of the piston, so as gently to force the contents of the syringe into the *vitreous*—in doing this, you will notice, as the tension of the eye-ball increases from the injected fluid, that the retinal vessels gradually contract, and ultimately disappear, in consequence of the circulation through them being arrested by the intraocular pressure. You may prove this to be the case, by retaining the nozzle of the syringe in the eye, so as to keep in the injection, while the animal is killed by blowing into one of its jugular veins; then remove the eye-ball, and the retinal vessels will be found collapsed and bloodless.

There are some other points deserving notice in connexion with this experiment. If the injection be gently forced into the vitreous, long before the eye-ball becomes as tense as it would be in the case of ordinary glaucoma, the lens will be pushed forward against the cornea, the iris being jammed between them. At length, as the pressure increases, the cornea begins to lose its transparency; but usually, before it has become so far opaque as to prevent the fundus of the eye being seen, one or more of the vessels of the iris or ciliary processes gives way, and the anterior chamber becomes filled with blood.

I would particularly insist, however, on the fact, that the circulation in the retinal vessels is stopped by the forcible injection of fluid into the vitreous chamber ; for, if this be the effect of fluid mechanically introduced into the vitreous, we can hardly suppose, that if formed there by hypersecretion, or in any other way, so as to cause a greatly augmented tension of the eye-ball, the opposite effect would result, and the retinal veins become deeply congested, as is undoubtedly the case in glaucoma. It appears to me, therefore, that the cause of the increased tension which always exists in this disease, must be looked for elsewhere than in the vitreous chamber. I am convinced that, if sufficient force were exerted in this direction to thrust back the dense lamina cribrosa, the circulation of blood through the retinal vessels would necessarily be stopped ; on the other hand, we know that force exerted external to the vitreous, as for instance the pressure of the finger on the eye-ball, will induce an arterial pulse even in the healthy eye, and this, as I have before mentioned, is one of the symptoms of glaucoma.

Exp. 2.—If we inject the *choroid* only, a train of phenomena occur, different from those above described. It will be necessary to operate either on a horse, or dog, or some such animal, instead of the rabbit, as the sclerotic of the latter is very thin, and, the animal possessing no tapetum, it is difficult to demonstrate the point under consideration.

Having made preparations for the injection, an assistant should fill the syringe with a warm solution

of gelatine coloured with vermilion ; a minute incision must then be made through the sclerotic, and the point of the syringe very carefully inserted along its inner surface for a few lines, so as to enter the choroid, but not to pass through the elastic lamina ; this point must be strictly attended to. If the piston of the syringe be then gently screwed down, so as to force the injection into the choroid, the eye-ball will become intensely hard, its tension being as great as in chronic glaucoma. If the fundus be examined with the ophthalmoscope during this proceeding, the circulation in the retinal vessels is seen to be uninterrupted. Not a particle of the red fluid injected into the choroid will be observed in front of the elastic lamina, for it is entirely hidden by the hexagonal cells. If the injection be well managed, the choroidal border of the papilla will be forced forwards, and in the dog's eye, the connexion of the retinal vessels at the margin of the disc will be no longer seen ; in fact, you have as near an approach to the appearance of the excavated disc of glaucoma as it is possible to conceive.

To complete the experiment, the nozzle of the syringe should be retained *in situ*, and the animal killed by blowing into one of his veins, or dividing the spinal cord high up in the neck, so as not to lose any blood ; and the eye-ball having been carefully removed from its socket, the cornea should be slit through, and the eye allowed to soak in a solution of chromic acid for two or three days, so as to harden the tissues. You will then find every particle of the

injection collected as a diffused mass between the sclerotic and elastic lamina, extending from the ciliary body to the optic disc. I need hardly say, considering the delicacy of the tissues we have to deal with, that many injections will fail; but the phenomena above described are exactly those presented, if the manipulation be successful.

Although, as I before said, I by no means deny the existence of the cupped disc in glaucoma, for I have dissected eyes in which it was present, and many cases of a similar kind have been recorded; yet I have grave doubts as to the soundness of the view which has been commonly taken of the causes producing it. In the majority of these instances, the increased intra-ocular pressure (the supposed mechanical cause of the cupping) is not due, I believe, to hypersecretion of fluid into the vitreous, but to serous effusion into, and subsequent hypertrophy of the choroid; and this suggests a very different explanation of the cupped appearance of the disc, referring it rather to elevation of its choroidal margin, than depression of its centre. But, whether this is the correct interpretation of the appearances or not—and it is quite possible that excavation of the disc may take place from pathological changes which we do not understand—still, the pressure hypothesis appears to me quite irreconcilable with the results of the foregoing experiments and observations. For, in the first place, even in the case of the rabbit, in whose eye there exists in the normal state a certain depression of the centre of the disc, no increase of this condition was caused by

injecting fluid into the vitreous ; but its immediate effect was to stop the circulation of blood in the retinal vessels. Secondly, pressure capable of thrusting back the dense lamina cribrosa in the human subject, must, I conceive, by mechanically stretching the parts, cause the cornea and lens to become so completely hazy, that the fundus of the eye could not possibly be seen. It is true, these structures do become opaque in glaucoma, but this appears to result from the pressure exerted on the ciliary nerves in their passage through the choroid, which occasions anæsthesia, and ultimately degeneration of the laminated tissue of the cornea.

Leaving these questions in the pathological anatomy of glaucoma, we must now pass on to consider the general history and symptoms of the malady. Mr. Soelberg Wells remarks, that “we may divide cases of glaucoma into two principal classes :—

“ I. Cases attended with inflammatory symptoms.

“ II. Cases in which there are *apparently* no inflammatory symptoms present.

“ Glaucoma may exist as a primary disease, or may complicate a previously existing affection.

“ We find that the different varieties of glaucoma show certain common characteristics, and we may generally recognise the four following stages :—

“ 1. A premonitory stage.

“ 2. A stage in which the glaucoma is fully developed.

“ 3. A stage in which quantitative perception of light has been completely lost for some time.

“4. A stage in which the eye undergoes glaucomatous degeneration.”*

I wish, however, to avoid all mention of inflammatory changes in connexion with glaucoma, and I shall therefore restrict myself to describing two forms of the disease:—

I. *Glaucoma*, which may run either a rapid or a more protracted course (active or chronic).

II. *Glaucoma simplex* of Donders, the symptoms and pathology of which are very nearly akin to the above form of disease.†

Glaucoma seldom attacks a person under forty years of age. In the first instance the patient complains of rapidly advancing *presbyopia*; he finds, that month after month, he has to increase the distance between his eye and the book he may be reading, in order to see the letters distinctly. The reason of this is, that the power of accommodation is in a great measure destroyed by changes going on in the choroid; which, though often hardly sufficient to cause any increased tension of the globe, may nevertheless affect the ciliary nerves, and probably the fibres of the ciliary muscle, so that it cannot act on the lens, and render its anterior surface sufficiently convex

* *Glaucoma, and its Cure by Iridectomy*, by J. Soelberg Wells. 1864, p. 5.

† “This disease was for a long time considered as distinct from glaucoma, with which it was supposed to have nothing in common but the excavation of the optic nerve. Von Graefe described it first under the title of ‘Amaurosis with Excavation of the Optic Nerve,’ but he has now also admitted it into the glaucomatous group of diseases.”—*Id.*, p. 32.

to bring divergent rays of light to a focus on the retina.

On inquiry, you will probably find that your patient has suffered from uneasiness, and often from a considerable amount of *pain*, of a periodic character, situated over the eyebrow and along the side of the nose. This pain, which is due to periodic exacerbation of the choroidal congestion, and consequent augmentation of the tension of the eye-ball, usually comes on towards evening, and lasts for a few hours, the patient's sight becoming very misty during the paroxysm. The degree and character of the pain are uncertain; in some cases it is very intense, while in others it is trifling. You must be on your guard not to mistake hemicrania for glaucoma; an anxiety to detect the latter affection has, to my knowledge, caused an erroneous diagnosis of this kind to be made more than once; and this may readily happen, as in hemicrania the patient is apt to complain of a darting, shooting pain in the eye, and the fundus will be found deeply congested.

Another symptom, often noticed at an early period of the complaint, is that the patient sees a *halo* surrounding the flame of a candle, or any other luminous object in front of him. The field of vision also becomes gradually contracted; but I purposely omit any further notice of this symptom, because I find it almost impossible to test a native's sight in this way. If you can make your hospital patients fix their eyes steadily on a black spot, while you place a series of dots or lines at various distances from it, which they

can see at the same time as the central spot, you will accomplish more than I could ever do ; for in spite of all my efforts, the patient invariably follows the hand with both his eyes, and thus makes it impossible to sketch out an accurate map of his field of vision.*

In the early stages of glaucoma, the *tension* of the eye-ball is only slightly increased, and this is most apparent towards evening ; subsequently the increased tension becomes permanent, and varies according to the stage of the disease from T + 1 to T + 3. On inspecting the eye, you will probably notice several enlarged vessels coursing over the sclerotic. The aqueous appears muddy, rendering the fibres of the iris indistinct. The state of the *pupil* will be found to vary according to the progress which the affection has made : at an early stage, it acts sluggishly on the stimulus of light, but as the disease advances, it gradually becomes less active, until at length it remains widely dilated and quite insensible to light.

On making an *ophthalmoscopic examination*, the vitreous will be discovered to be somewhat hazy, and the retina hyperæmic, with its veins tortuous and deeply congested. The arteries in the early stage of the disease are normal, and subsequently perhaps slightly contracted ; in both sets of vessels a distinct pulsation will be noticed, or, if it does not already

* The more simple plan of holding the finger before your face, the patient being directed to look steadily at your eye, while you move your finger about in various directions to test the range of vision, has equally failed.

exist in the arteries, it may be induced by slight pressure with the finger on the eye-ball. The only change observable in the optic disc at this period is, that its choroidal margin is rather prominent; except in cases complicated by congenital staphyloma of the papilla, in which, of course, the excavation will be more marked in consequence of the bulging backwards of the lamina cribrosa. As the disease advances, the vessels of the choroid will be found uniformly congested, but blurred and indistinct from effusion into its substance, and from the hexagonal epithelium not being completely destroyed.

These symptoms having lasted for a longer or shorter period—it may be for months or perhaps a year or two—they all become gradually augmented; the tension of the eye-ball increases, and the ciliary neurosis becomes very intense. The cornea is hazy, and its sensibility is decidedly diminished, so that it may be touched by a bit of paper without the patient being aware of it. The dimness of vision increases, the pupil is widely dilated, and the lens is apparently of a *green colour*. This last appearance arises from the lens itself assuming a yellowish hue, while the aqueous becomes of a bluish tint, the combination causing the green colour, which at one time was supposed to be pathognomonic of glaucoma, and gave rise to its name.

If now the eye be examined with the ophthalmoscope, the cornea and lens remaining sufficiently transparent to allow of the rays of light reaching its

fundus, the retinal veins will be seen to be very tortuous and greatly congested; they are sometimes beaded, as represented in Plate X., Fig. 3. The calibre of the arteries, on the other hand, is contracted, and a distinct pulsation may be noticed in both sets of vessels. The fundus of the eye is of a brick-dust colour, owing to the capillaries of the retina and choroid being uniformly congested; and spots of extravasated blood are not uncommonly noticed both in front and behind the elastic lamina. The choroidal margin of the optic disc is very prominent, and as the nervous structure of the papilla becomes atrophied, the disc appears to be *deeply cupped*. No doubt in some cases it is also excavated, that is to say, the lamina cribrosa protrudes backwards, so as to occupy at this part a plane posterior to that of the sclerotic; this appearance is shown in Plate X., Fig. 2. As the disease advances, the dioptric media become hazy, and it is impossible to see the further changes that take place in the fundus of the eye.

Glaucoma simplex is a very insidious disease. The patient complains of little or no pain in the eye, and the only constant symptoms noticed, are the steadily increasing presbyopia and augmented tension of the eye-ball, which, though scarcely perceptible at the commencement of the attack, become, after a few years, marked features in the case. The changes in the fundus of the eye progress at an equivalent rate, and are much the same as those observed in ordinary glaucoma; and the termination of the disease is similar, namely, stony hardness of the globe, dilated

pupil, opaque lens, a hazy anæsthetic condition of the cornea, and total loss of vision.

With regard to the *treatment* of glaucoma, there can be no doubt whatever that *iridectomy*, if practised sufficiently early, will cure the disease; in the latter stages, this operation will relieve the pain in the eye, but of course, if the retina has become atrophied, iridectomy cannot possibly exercise any restorative effects as regards the patient's sight. I had been in the habit of practising iridectomy prior to 1860; but in August of that year, my attention was particularly directed to the subject by an article in the *Dublin Quarterly Journal*, which was followed soon afterwards by a communication from Mr. Bowman, in the *Medical Times* for August the 24th, 1860. The differences of opinion expressed by the able writers of these articles, regarding the advantages to be derived from iridectomy in glaucoma, were so remarkable, that I was anxious to test the efficacy of the proceeding upon an extended series of cases; and I can now safely assert from my own experience, that iridectomy is not only a *safe* but a *sure* means of cure in all cases of incipient glaucoma, whilst, in chronic cases, it relieves the tension of the globe, and prevents subsequent recurrence of pain in it. In making this assertion, you must distinctly understand that by iridectomy I do not simply mean the excision of a portion of the iris, however large it may be; the operation consists in the successful removal of a section of the iris together with its ciliary attachments, and I consider this indispensably necessary for

the cure of glaucoma. In certain cases of sloughing ulcers of the cornea, in which iridectomy is recommended, it does not appear necessary to detach the iris ; all that is requisite is, to remove so much of it as will prevent the secretion of the normal amount of aqueous, and thus, by diminishing the pressure from behind, prevent the corneal tissue being stretched, and ultimately forced into a staphyloma. But in glaucoma, more than this must be done ; I have punctured the cornea time after time, and allowed the aqueous to escape, thus relieving the tension of the eye-ball, without the slightest permanent benefit to the patient.

I must not, however, omit to mention in this place, Mr. Hancock's operation for the division of the ciliary muscle, which he strongly recommends in cases of glaucoma. M. Wecker, and many other surgeons, also speak in the highest praise of this proceeding. I have divided the ciliary muscle according to Mr. Hancock's plan on various occasions, but my experience of the results of this operation has not been, at present, sufficient to enable me to offer an opinion upon its merits. It appears to me, that however advantageous it may be to divide the muscle, yet the curative effects which follow this proceeding may, perhaps, in some degree be accounted for, by the opening made into the choroid.

Mr. Hancock thus describes his operation in the Ophthalmic Hospital reports for July, 1860, p. 18 :—
“A Beer's cataract knife is introduced at the outer and lower margin of the cornea, where it joins the

sclerotica. The point of the knife is pushed obliquely backwards and downwards, until the fibres of the sclerotica are divided obliquely for rather more than one-eighth of an inch; by this incision the ciliary muscle is divided, whilst if there be any fluid accumulated, it flows by the side of the knife."

With regard to the method of performing iridectomy, the instruments required will consist of a Weiss' stop speculum to keep the lids apart, and a lance-shaped knife, the base of which must be less than half an inch broad, so as to enable you to make an incision through the sclerotic. As it is not always advisable to puncture it from the outer side of the eye, knives with blades of various forms, and having different degrees of curvature, will also be necessary, so that you may open the anterior chamber either from above or to its inner side, as may be most convenient. A pair of fine-toothed and curved forceps will also be required, to withdraw the fold of iris through the wound, their curvature corresponding to the situation of the opening made in the sclerotic. A second and larger pair of toothed forceps will be necessary to hold the eye-ball steady during the operation, and lastly, a pair of scissors must be provided to cut through the iris.

It is advisable to give your patient chloroform when performing this operation. If he is kept without his evening meal the day before, there is little chance of its producing vomiting; and it is far better to run even this risk, than that he should move his head just as you are about to excise the iris. You must take

care, however, that he is fully under the influence of the chloroform during the operation.

Having rendered the patient completely insensible, and placed him in the recumbent position on the operating table, his eye-lids being separated by means of the spring speculum, (supposing the external part of the iris is to be removed) the surgeon stands behind him, and taking hold of a fold of the conjunctiva internal to the cornea with a pair of forceps, so as to steady the eye-ball, he passes his knife through the sclerotic into the anterior chamber, at a point close behind the junction of the cornea and sclerotic, pushing the blade on till he has made a free opening in the tissues. The forceps are then introduced through the wound, and a fold of the iris carefully laid hold of, and dragged out of the eye, so as to enable the surgeon, as Mr. Bowman remarks, "to divide it with a small pair of scissors, on one side of the forceps, from the pupil to the ciliary border, the forceps pulling it gently at the same time, so as to ensure this complete division of it." "The end held by the forceps is then torn from its ciliary attachment as far as the angle of the incision, and even dragged upon a little, so as to detach it beyond this angle, and then divided with the scissors close to the angle. The cut end then retracts into the anterior chamber. The opposite side of the prolapsed part is then seized, and dealt with in exactly the same way. No iris should be left in the angle of the incision." For my own part, I prefer cutting through the iris from its pupillary margin to the ciliary attachment, on either side of the forceps, so as

to remove a fourth of it, and then dragging the flap of iris from the ciliary attachment, care being taken that the flap is completely separated from its connexion with the rest of the iris. To make sure that its ciliary attachment and the elastic lamina are broken through, I usually run a spatula immediately beneath the sclerotic through the ciliary body, as far backwards as to a line corresponding with the ora serrata, making in this way a free passage from the choroid into the anterior chamber; but beyond this, I never introduce an instrument into the eye after iridectomy.

Sometimes the anterior chamber becomes filled with blood, but it may be allowed to remain there, for it is rapidly absorbed, and any attempt to get rid of it by means of a scoop, is likely to set up irritation, without being followed by any corresponding advantage. It is well, however, always to have ice at hand, and if the hæmorrhage appears to be more profuse than usual, it should be applied to the eye at once. The only subsequent treatment required, consists in keeping the eye perfectly quiet by means of a cotton pad and bandage tied over it. Once again, I cannot too strongly impress upon you, that in iridectomy your aim must be, not simply to remove a fourth of the iris, but, in doing so, to drag away its ciliary attachments also, otherwise the operation can succeed only by accident.

You may ask, perhaps, at what stage of glaucoma may iridectomy be most advantageously performed? Under all circumstances, I would advise you to operate as soon as you possibly can, the earlier the

better, for you may thus save your patient's eyesight, while you can do no harm, provided the operation is managed with ordinary skill. I have no hesitation in saying that iridectomy is almost a certain cure, if performed before the glaucomatous disease has made such progress as to destroy the function of the retina or choroid; and even in advanced cases, where you cannot expect to restore the sight, the operation may still relieve the patient from protracted suffering; and I need hardly say, that no other method of treatment at present known can afford a reasonable hope of a like result. I know of only one cause likely to lead to a failure, and that is, the rupture of some of the distended blood vessels, either in the choroid or retina, immediately after the operation. I have never had a case of this kind in my own practice, but doubtless such may occur, and you must therefore be prepared to meet with them occasionally.

Before closing this lecture, I may make a few remarks upon the advantages to be derived from iridectomy in other affections of the eye besides glaucoma; and first, as regards its use either before or at the time of *extracting an opaque lens*.

Among our Hospital patients, we seldom meet with cases in which iridectomy can be first performed, to be followed, after recovery, by extraction: my experience teaches me that it is useless proposing it, as patients of that class will not put up with the delay thus caused. This objection does not however hold good, if the iris be excised at the time of the extraction; it

is then a safe proceeding, and one which should generally be resorted to. If you determine to combine iridectomy with extraction, it will be necessary to give your patient chloroform; for unless you do so, it is impossible to make sure of his passing the third stage of the operation, without such an amount of straining, as will almost certainly force out a quantity of vitreous from the eye. In these cases the upper part of the iris should be removed, so that the lid may subsequently overhang the opening made in it. The advantages of this proceeding are, that by removing a portion of the iris, that structure is not bruised when the lens is pressed through the pupil, and what is of still greater importance, that we thus take the best preventive means against cyclitis; for under these circumstances, if inflammation of the ciliary body supervenes, there will be a free opening into it, from which any effused fluid can escape into the anterior chamber, thus preventing the injurious effects of pressure upon the ciliary vessels and nerves. I think, therefore, that other circumstances being favourable, iridectomy should be performed in most cases during the operation of extraction, provided no reason exists for not administering chloroform, otherwise it is better not to attempt the iridectomy before extracting the lens.

In some cases of *occlusion of the pupil*, Von Graefe states that the eye is prone to become glaucomatous, and that iridectomy should be insisted on under these circumstances. I am in the habit of performing this operation in instances of extensive synechia, even

when it might be possible to separate the bands of adhesion without wounding the lens; for, in such cases, if the iris has been much damaged by repeated attacks of inflammation, it is better that a portion of the diseased structure should be removed, because, though the adhesions between it and the lens may be broken down, fresh attacks of inflammation are very apt to occur, and the parts return to their former condition. In operating under these circumstances, it is better to remove about one-eighth of the iris instead of a fourth of it, a clear pupil is thus formed, and any tendency to sub-acute inflammation which may exist in the ciliary body, is prevented.

Lastly, iridectomy may be of essential service in extensive *sloughing ulcers of the cornea*, especially if they have not reached its centre, so that the axis of vision is still clear. Under these circumstances, the operation not only relieves the tension of the anterior chamber, and in this way prevents the occurrence of staphyloma, but the ulcer heals far more rapidly than it otherwise would. The upper part of the iris should always, if possible, be the portion removed in affections of this description.

LECTURE XI.

Cataract from Constitutional Syphilis. Use of the Ophthalmoscope in Cases of Cataract. Extraction of the Lens. Results of the Author's Experience in India. Advantages of Linear Extraction. Instruments. Management of Complications.

I MENTIONED on a former occasion, that the lenses of persons affected with syphilis sometimes undergo degenerative changes, similar to those described in my third lecture as occurring in the cornea. A cataract may arise from the effects of inherited venereal disease, but it does not generally become developed till after the adult period of life; it is by no means a common sequence of primary infecting syphilis, unless the patient's constitution has been thoroughly impregnated with the disease, and it may then be a difficult matter to determine how far the degenerative changes in the lens are directly due to syphilis, and how far to inanition engendered by the debilitating effect of the disease. I have not the slightest doubt however, that constitutional syphilis occasionally causes changes in the lens, which lead to its becoming opaque. If these cases are brought sufficiently early under our observation, and a long continued and judicious course of bichloride of mercury and cod-liver oil be employed, the transparency of the lens may be restored. I have

seen more than one instance of the kind, and think, that if carefully sought for, they would prove to be of more common occurrence than we might otherwise suppose.

The ophthalmoscope affords us only negative aid in the diagnosis of these cases, for if the pathological changes are confined to the lens, the fundus of the eye will appear healthy. In the early stages of the disease, light, flocculent-looking patches may be noticed in the lens, and these gradually increase in size and number until the whole structure becomes opaque. With the exception of these syphilitic (and some traumatic) cases, you will seldom meet with an instance of cataract in which some morbid appearances may not be observed, either in the choroid or retina: dilatation of the choroidal vessels, and subsequent atrophy of its structure, are the pathological alterations most commonly met with; these may arise from senile degeneration, or from other causes such as I have noticed in a former lecture.

I have before explained to you, that hyperæmia of the choroid, though interfering with the nutrition of the lens and vitreous, does not necessarily destroy the functions of the retina; so that although you may discover opacity of the lens to be complicated with chronic hyperæmia of the choroid, you may remove the lens with a fair prospect of the patient's sight being considerably improved. If in addition to the congested capillaries, you find the optic disc abnormally white, or the retinal vessels contracted, you had better decline to interfere; and this decision will be

confirmed, if you observe spots of atrophied retina, or such like changes in the fundus of the eye. It is surprising how very many instances of this description you will meet with; and it is simply because they have not been looked for, and their importance taken into consideration, that so many cases of extraction have terminated unfavourably, and the operation has fallen into undeserved disrepute in this country. A very similar error has rendered the division of the muscles for strabismus an unpopular proceeding.

But you may wonder how you are to see the deep structures of the eye through an opaque lens. If the opacity is so dense in both lenses, as to obstruct the passage of light to the fundus of the eye, you cannot of course observe its condition. But in the majority of cases, one lens becomes affected before the other, so that you may generally ascertain the state of the fundus in the eye which is least impaired, and so form a tolerably safe inference as to the condition of the other. The patient must invert his eye, and you may then see the fundus through the margin of the lens, even when its centre is densely opaque, particularly if the pupil be well dilated with a strong solution of atropine. A prismatic glass, held in front of the eye, is often of the greatest use in such cases.

The ophthalmoscope, therefore, assists us to distinguish cases of opacity of the lens in which we can advantageously operate, from those in which we could not hope for a successful issue, although the lens were extracted and the section healed without any trouble. Besides investigating the ophthalmoscopic appearances,

we should of course always inquire as to the presence of other symptoms contra-indicating extraction, as for instance, obscure pain over the temple, increased tension of the globe, or alteration in the condition of the iris. The eye, however, may be apparently healthy, and its fundus, nevertheless, extensively diseased; so that an ophthalmoscopic examination should never be neglected before an operation for the removal of cataract is attempted.

It was formerly considered a matter of some importance, to ascertain if the cataract were a hard, mixed, or soft one, in order to decide upon the means best adapted for its removal. If the ophthalmoscope assists us in determining this point, it is now seldom necessary to have recourse to it, as cataracts of all kinds are, without doubt, best removed from the eye by the operation called *linear extraction*.

I may lay claim to having been the first surgeon in this Presidency who had operated for *extraction* to any extent prior to 1862; and shown that it was not only a feasible proceeding, but also yielded far better results than *reclination*. Dr. Martin, it is true, had extracted the lens in a few cases; but he states, that he and his predecessors did not operate in this way, being of opinion that it did not give their patients the best chance of recovery. Until the year 1861, it appears from my predecessor's reports that he invariably performed *reclination*, and it was not until 1862 that he began to extract. But in June, 1861, I had published a paper in the 14th number of the *Indian Annals* on the subject of extraction, showing that for

some years prior to this date, I had been in the habit of extracting the lens with very favourable results. In the Calcutta Ophthalmic Hospital, under Dr. Archer's care, the average number of recoveries after extraction were about 42 per cent., but then he operated under peculiar difficulties; his wards being, as he describes them, "mere cellars beneath the Medical College Hospital, without proper ventilation, drainage, or light;" and it is a wonder to me that any of his patients lived in this filthy hole, much less recovered from so serious an operation as extraction.

The principal difficulty which we have to contend against, in successfully performing the operation of extraction among the natives, arises from their own imprudence; for in spite of our best efforts, they will not submit to the necessary after-treatment.* But beyond this, I have no hesitation in saying, that the natives of Lower Bengal are more liable to suffer from an insidious form of cyclitis after extraction than the inhabitants of the Upper Provinces. No doubt, in the case of the patients in the Medical College, this tendency was augmented by the stinking air they were compelled to breathe. Diffuse suppuration of the cornea, moreover, was frequently seen among these cases, and probably more eyes were lost in this way after extraction than by cyclitis. Before, therefore, testing a comparatively new method of removing the

* I shall enter more fully upon the subject of extraction, reclamation, and solution, in a subsequent lecture. The relative advantages and method of performing these operations are admirably described in Mr. Dixon's work on the eye.

lens, it seemed very advisable to get my patients into other wards. This was accomplished on the 1st of April, 1865, and I am now able to place before you the result of about a hundred cases of linear extraction which I have performed during the past nine months. I propose dividing this period into three parts, and analysing the results of the operation in each separately, for the sake of comparison. During the *first* period, which extended over two months, they were as follows :—

Total number of cases, 33. Number cured, 64 per cent. The mean age of those suffering from hard cataract was 53 years; of these, $33\frac{1}{2}$ per cent. recovered.

The mean age of those affected with mixed* cataract was 47; of these, 84 per cent. were cured.

The mean age of those suffering from soft cataract was 34; the whole of these cases recovered.

The average duration of these patients in hospital was seventeen days.

During the *second* period, from the 1st of June to the 19th of October, I operated with Schufler's knife and scoop, with the following results :—

Total number of cases operated on, 46.

Number cured, 69·5 per cent.

Of these, 52·9 per cent. were hard cataracts.

82· ,, ,, mixed cataract.

62· ,, ,, soft cataract.

* By a mixed cataract I mean an opaque lens having a hard nucleus, and outside this a layer of soft lenticular matter.

The *third* period extends from the 19th of October to the present time. I operated on nineteen cases with a knife and scoop made for me by Messrs. Weiss and Co.; the results were—

Number of cases operated on, 19; of these 94·7 per cent. were cured.

Nine cases of hard cataract; the whole of these were cured.

Mixed cataract, 10 cases; 90 per cent. cured.

You will observe that the per centage of recoveries was greater in the second than during the first period. I attribute this to two causes; first, I had gained experience in the operation; and secondly, I had then commenced the practice of excising a portion of the iris, when operating on cases of hard cataract. To the first of these causes too much importance cannot be attached; it would be absurd to expect to be as successful as we could wish without practice; it is, however, by no means uncommon to hear of men discarding an operation of this kind, because their first few cases have not been as perfect as they had hoped they might be. With regard to excising the iris in hard cataract, there can be no doubt whatever of the advantage of this proceeding; I shall not, therefore, stop to discuss its merits, but lay it down as an axiom, that in the majority of cases of hard cataract, a portion of the iris must be excised, prior to the removal of the lens by linear extraction.

As I have before remarked, during the first and second periods above referred to, I had used Schuft's knife and scoop. The former, I found, was not broad

enough at the base to make a fair opening through the cornea, and it was too long from apex to base, frequently transfixing the cornea in making the necessary incision. The scoop also was too small, and the cataract was frequently broken up in consequence. To rectify these defects, I ordered the instruments from Weiss which I now invariably use. No doubt the number of cases (19) treated since the 19th of October, are not sufficiently numerous to enable me to form an accurate forecast as to the ultimate success of the operation; nevertheless, 94.7 per cent. of recoveries, up to the present time, January, 1866, makes me very sanguine on this point, particularly as the latter months of the year are by no means favourable for extraction.

The instruments required for linear extraction are a short-bladed triangular knife (Fig. 7), its base being about half an inch broad, and the distance from base to apex rather less than this; secondly, a scoop (Fig. 8), which should not be quite so broad as the knife; its extremity must be hooked and serrated, so as to take a firm hold of the lens. For the extraction of a hard cataract, there should be a hole



FIG. 7.

FIG. 8.

through the centre of the scoop, so that the most convex part of the lens may rest in it. A pair of forceps will be required to keep the eye-ball steady, and a second pair to withdraw the fold of iris through the incision in the cornea ; and lastly, a pair of curved scissors.*

Before the operation, the patient's pupil should be well dilated with atropine ; he is then to be laid on a convenient table, and placed fully under the influence of chloroform. The surgeon stands behind his patient, and a stop speculum having been adjusted, so as to keep the lids apart, (the right eye being under operation) the surgeon nips up a fold of conjunctiva with a pair of forceps, close to the inner margin of the cornea, and thus keeps the globe steady. With the other hand he thrusts the knife through the outer circumference of the cornea, a little anterior to its junction with the sclerotic, making an incision about half an inch long. The smaller the opening the more difficult it is, of course, to get out the lens, but, on the other hand, there is less chance of prolapse of the iris than if the incision were a large one.

Before withdrawing the knife from the eye, its point is to be run into the lens, so that the capsule may be freely lacerated ; and in withdrawing the instrument, it is well to drag on the iris a little, so that the pupil may assume a pear-shaped form, the nar-

* I have requested Messrs. Weiss and Co., Strand, London, to make up small cases containing a stop speculum, and the instruments necessary for linear extraction.

row end being at the section. If the cataract is a *mixed* or *soft* one, as soon as the capsule has been lacerated, the outer soft lenticular matter gives way, and the elastic vitreous pushes the nucleus of the lens forward, so that its anterior surface rests against the cornea, and the pupil is of course forced open. Under these circumstances, the curved extremity of the scoop can be easily passed through the section, and pushed against the outer circumference of the lens, which immediately turns on its axis and comes to rest in the hollow of the scoop; the curved and serrated edge of the instrument being hooked over the inner margin of the lens, the latter may then readily be withdrawn from the eye. It will be necessary, afterwards, to remove any broken pieces of lenticular matter from the anterior chamber with a spoon-shaped scoop. With regard to the turning of the lens on its axis, my meaning will be readily understood if a lens be laid on the middle finger of the left hand, and the scoop gently pressed against one edge, the thumb being kept against the opposite side of the lens, to prevent it from slipping away before the scoop; under these circumstances, the lens will tilt over on its axis (exactly as it does in the eye) and come to rest in the hollow of the scoop.

Supposing, however, the lens is a *hard* one, it is evident that, after its capsule has been lacerated, there being no soft lenticular matter at its margin, the vitreous will not be able to force the lens through the pupil, its bulk being too great to allow of this; consequently the pupil contracts, and the elastic

vitreous forces the lens and iris forwards against the cornea. The question now arises, How are we to pass the scoop through the pupil under these circumstances, so as to get the instrument behind the lens? There are two ways of doing this: a fold of the iris may be seized, and having been withdrawn through the section, it may be excised by an assistant; by this means the pupil is enlarged, and the scoop can be pressed against the margin of the lens, and the operation completed as above described. Or, in place of excising the iris, if, after puncturing the lens, you see that the cataract is a hard one, by very carefully bending the point of the knife downwards, so as to catch the margin of the pupil, it may be dragged outwards towards the section, inducing, in fact, a temporary prolapse of the iris. You will thus have a large pear-shaped pupil, through which you can easily pass the scoop and prevent the necessity of excising the iris. This is an advantage, as you obtain a clear central pupil in place of a distorted one; for after the lens has been removed, the pupil may be restored to its position by means of a spatula.

It often happens that, towards the end of the operation, the patient begins to regain his consciousness; if this be the case, you must administer more chloroform, for two reasons—first, you should never close the eye till you are convinced the iris is perfectly *in situ*, and that there is a clear central pupil; and secondly, by having the patient well under the influence of chloroform up to the last moment of the operation, the sensibility of the part is destroyed, and

there is no involuntary straining, and therefore but little chance of prolapse of the iris.

While performing the operation, you should attend strictly to the following points:—First, that the patient is completely under the influence of chloroform. Secondly, that the opening in the cornea be about half an inch long, and that the scoop be passed steadily and boldly behind the lens. Thirdly, no lenticular matter should be allowed to remain in the anterior chamber. As a general rule, it is not advisable to operate on both eyes at the same time; our hospital patients may keep one eye closed for twenty-four hours, but very few of them will remain in total darkness for that period; and however dense the cataract may be in the eye you have not operated on, the patient can generally see to grope his way about the ward with it. Nor is it advisable to prevent this; it does no harm after linear extraction if the patient moves about, provided the eye operated on is kept closed. I have performed linear extraction on several individuals with admirable success, who have immediately afterwards been led away from the Hospital, and subsequently attended as out-patients.

The after-treatment will depend upon the condition of the parts. If there is a tendency to prolapse of the iris, a saturated solution of Calabar bean may with advantage be dropped into the eye; in the majority of instances, however, I apply an eight-grain solution of atropine, and then close the lids, keeping them shut for twenty-four hours with a compress of cotton wool and a bandage. At the end of that time, the eye may

be examined; the incision should have healed, and the cornea appear bright and convex; there will be little, if any, congestion of the conjunctiva. Under these circumstances, the bandage, without the compress, should be re-applied over the eye that has been operated on, the other one may be left open. In the course of a few days the patient may use the eye, a shade being worn when he is exposed to a bright light. I allow him full diet, and, in fact, almost anything he pleases in the way of food, from the day of the operation, but usually prescribe a dose of castor oil the morning afterwards, particularly if there is any pain in the eye.

The circumstances which may complicate the after-treatment are principally these:—

1. If the cataract has not been fully developed at the time of the operation, you may have removed all the opaque portions of the lens, and yet, on opening the eye next morning, will discover that the anterior chamber is full of flocculent matter, consisting of that portion of the lens which was probably perfectly transparent the day before, and therefore not perceptible. Under these circumstances, the eye may be left alone; the lenticular matter will be rapidly absorbed, provided there be no inflammatory action going on.

2. It may be, that on examining the eye, you find a portion of hard lenticular matter in the anterior chamber. It is then advisable at once to re-open the incision, and remove the offending particle; if it remains in contact with the iris, it must act as a foreign

body, setting up irritation and inflammation, and the sooner it is got rid of the better.

3. It sometimes happens, in withdrawing a hard lens from the eye, that the epithelium of the posterior elastic lamina is injured; in which case the cornea often assumes a hazy appearance, and at first sight looks very much as though it were about to suppurate. You need not fear the result in a case of this kind; but it is well to keep the pupil dilated with atropine, as you cannot see what mischief may be going on in the iris. The cornea, however, in the course of a few weeks or a month, will regain its transparency, as it does after keratitis.

4. In some cases the uvea is scraped off the iris during the operation, and often a small amount of blood exudes into the anterior chamber, so that on the morning after the operation, you find it full of dark looking matter, which prevents your seeing the pupil, or, in fact, the iris. In these cases, apply a strong solution of atropine to the eye, and extract of belladonna over the temple, and keep the lids closed with a pad and bandage, provided there be no great pain or irritation in the eye; the probability is, that the patient will do very well.

5. Occasionally, severe inflammation follows the operation, in which case you must do all in your power to get the pupil to dilate by the instillation of a strong solution of atropine, and keep the eye perfectly at rest. The subcutaneous injection of morphia under the skin of the temple will relieve the pain. With regard to constitutional treatment, you must be

guided entirely by the circumstances of the case ; one patient will require leeches and low diet, and another just the reverse ; in fact, it is impossible to lay down any definite rules upon this point.

During the last ten years I have operated on a great many natives suffering from cataract, by extraction, reclinatio, and solution ; and I have no hesitation in saying that *linear extraction* affords them by far the best chance of recovery. One advantage it possesses over extraction, to surgeons in this country, is, that the knife need not have that exquisite edge which is absolutely necessary in extraction, and which cannot be had in India, unless, indeed, the instruments are constantly sent home to be set. Furthermore, suppuration of the cornea and cyclitis seldom occur after linear extraction ; from the day of the operation you may allow your patient to move about and take his food, a very important point, for, as you are aware, the majority of our patients will not touch food or water, if given them by a stranger. Lastly, chloroform may always be administered during the operation, for should the patient vomit afterwards, it does no harm to the eye.

When I return to this subject in a future lecture, I shall endeavour to draw a line between those cases of opacity of the lens in which you should extract, and those which you should decline to interfere with. You are aware of the opinion I hold, that, except in cases of traumatic, congenital, or syphilitic cataract, the lens does not become opaque, unless there has been some pre-existing disease of the choroid.

LECTURE XII.

Disorders of Accommodation, Refraction, and Binocular Vision. Diplopia. Myopia. Hypermetropia. Presbyopia. Asthenopia—Motor, and Accommodatory. Astigmatism.

BEFORE commencing this lecture, I may remark, how surprisingly few cases of impaired vision, due to anomalies of the refraction and accommodation of the eye, we meet with among the lower classes in this country. In fact, whole races of people appear to be actually strangers to these diseases. For instance, some years ago I was employed among the Sonthals, who, you know, are the aborigines of this part of India, and dwell among the Rajahmahal hills, and I then took every opportunity of examining the eyes of the people I was brought in contact with, for the purpose of discovering if myopia and such like diseases existed among them; and I may affirm, that I never yet saw a Sonthal whose eyes were not emmetropic. The organ was, of course, often the seat of disease; but the abnormal condition, as far as my experience went, never depended upon anomalies of refraction or accommodation. The same remarks apply to nearly the whole of the lower classes in Bengal, with the exception of those living in Calcutta and other large towns, where overwork, sensual indulgence, and a polluted atmosphere have done a vast deal of harm to the eyes, as well as to the constitutions of the inhabitants;

so that myopia, and in fact the numerous ills consequent on defects in the refraction and accommodation of the eye, may there be met with every day.

It is an established fact, that, for correct vision, rays of light which enter the eye from every point of an object under observation, must be brought to a focus upon the bacillar layer of the retina ; it follows, therefore, that the healthy eye possesses an inherent power, by means of which, both finite and infinite rays are brought to a focus on the retina ; that is, both divergent and parallel rays are made to converge to a point on its bacillar layer.* It is to the anomalies which occasionally exist in the human eye, with regard to its power of effecting these changes, that I would now wish to draw your attention.

It has been found very advantageous to have a fixed scale by which to test the acuteness of vision, and which may be used, not only as a standard of comparison between one person and another, but also to ascertain whether a patient's sight be improving or otherwise under treatment. Dr. Snellen's test types are now commonly employed, and are those which I have adopted in this hospital. Corresponding types have been written in Bengalee and Nagree, together with a set of tables of different sized dots, which may be used by patients who are unable to read.†

The range of accommodation varies in different indi-

* Finite rays are those proceeding from objects within eighteen feet of the eye ; they are divergent. Rays from a point beyond this are considered as being parallel to one another, and are called infinite rays.

† These will be found in an Appendix at the end of the volume.

viduals and at different periods of life; in the normal or emmetropic eye, the nearest point of distinct vision is from three and a half to four inches, and the furthest point is at an infinite distance, being limited only by the loss of the rays of light, due to atmospherical or physical causes. In my second lecture, I gave you a short description of what appeared to me the most satisfactory way of accounting for these changes, namely, by the action of the ciliary muscle upon the ciliary body, and through it on the suspensory ligament and lens, causing the anterior surface of the latter to become more or less convex. If the object under observation is situated at a distance of more than twenty feet from the eye, the ciliary muscle is passive; but on its being brought nearer, the muscle contracts and the curvature of the anterior surface of the lens is increased. There can be no doubt as to the fact of the alteration in the shape of the lens during accommodation; Helmholtz has demonstrated this point most conclusively with his ophthalmometer; clinical experience, moreover, teaches us, that when certain branches of the third nerve are diseased, causing paralysis of the ciliary muscle, the accommodation of the eye is destroyed, and that without the activity of the pupil being affected. In confirmation of this, I may refer to a remarkable case lately in Hospital, which most of you will be able to call to mind, exactly corresponding to one described by Von Graefe, in which the iris was torn from its attachments by the patient suddenly drawing away his head whilst a part of it was being excised. I demonstrated to the

class, that, in this instance, the power of accommodation was not destroyed by the absence of the iris, and that a weak solution of atropine did not prevent its operation; but that a stronger solution, by paralysing the action of the ciliary muscle, destroyed the accommodation. And lastly, that the effect of Calabar bean on the nerves supplying the ciliary muscle was very marked, the accommodation being completely in abeyance for four or five hours, after a saturated solution had been applied to the eye.

Not only, however, must the conditions of the nervous apparatus, the dioptric media, and power of accommodation be perfect, in order to ensure correct vision, but the two eyes must also work in unison; for if the rays of light do not fall upon exactly corresponding portions of the two retinae, double vision or *diplopia* is the result. If you refer to the Ophthalmic Hospital Reports for October, 1859, and the

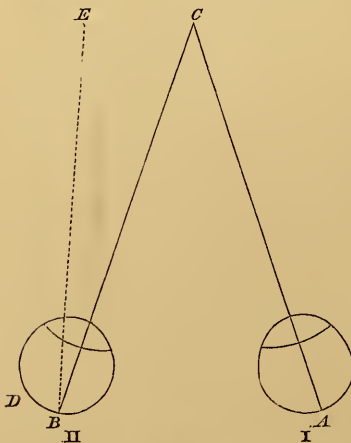


FIG. 9.

following numbers, you will find some excellent lectures on this subject by Mr. J. S. Wells. He states that there are two forms of diplopia, the *direct* and the *crossed*; the former may be best understood by referring to Fig. 9, taken from the same lectures. The left eye, B, in this case is supposed to be inverted, the right eye,

A, is normal, and directed towards the object C, the rays from which fall on the macula lutea at A; but in consequence of the left eye being inverted, the rays from C will fall on the point B, internal to the macula lutea D, and the image formed will be mentally projected, in a line perpendicular to this spot, in the direction of E; and thus two images of the figure C will be visible, one in its real position, and the other to the left of C at E. The reverse of this would, of course, hold good, if the right eye were inverted; the second image would then be to the right instead of the left of C.

In the second form of diplopia, as its name implies, the images cross one another, as shown in Fig. 10, from the same lectures. The left eye, B, is supposed to be everted, and the right eye, A, is in its normal position, the rays of light from the luminous point C falling upon the macula lutea at A; but as B is everted, the rays from C do not impinge upon its macula lutea at B, but on a point external to it at D,

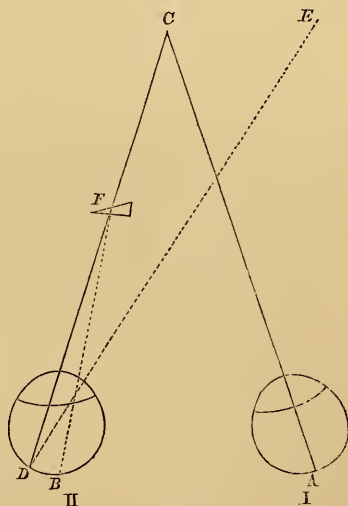


FIG. 10.

and are projected in a line perpendicular to this point in the direction of E, so that they cross those proceeding from C to A, and hence the crossed diplopia.

I may here remark, that the course of the rays C D may be changed by means of a prism, as at F, by which they are bent towards the base of the prism, and so fall on the macula lutea at B; in this way the diplopia will be corrected; for although the eye B is everted, the rays from C are directed upon its macula lutea by means of the prism F, and binocular vision is thus restored.

Prisms of this kind are now in constant use, not only for rectifying slight diplopia, but also as a test of the presence of binocular vision, in cases of *strabismus*. As I have before explained to you, it is most important that we should be accurately informed on this point; for, unless binocular vision exists, we dare not operate for the cure of *strabismus* with any hope of success. It does not at all follow, that because a patient squints, he must suffer from diplopia; in fact, in the majority of cases of long-standing *strabismus*, the functions of the whole or a portion of the retina in the affected eye are destroyed or suppressed, and it is then useless to interfere, unless for appearance sake.

The existence of binocular vision is ascertained in this way. If a prism be held with its base inwards, before either eye, rays passing through it will be refracted towards its base, and falling on the retina, will form an image internal to the macula lutea, which being projected, as in Fig. 9, in the direction E, direct diplopia will be the result. But the other eye will immediately and unconsciously endeavour to correct this, and by an involuntary motion, it will turn inwards (become inverted), so that the rays of light

from the object under observation may fall upon a corresponding portion of its retina, internal to the macula lutea, and thus correct the diplopia. Consequently, if under any circumstances the prism has this effect, we may be sure that binocular vision exists, and the reverse, if no such changes are induced.

By *Emmetropia* is meant the normal condition of the eye as regards its visual range. In this case, parallel rays of light are brought to a focus on the retina when the eye is at rest, and by a voluntary action of accommodation, divergent rays are also focused on the bacillary layer of the retina; so that objects at all ordinary distances can be clearly and distinctly perceived, while the nearest point for distinct vision is at about four inches from the cornea. As a test of this condition, Snellen's types may be clearly deciphered at the respective distances assigned to them; and after the instillation of atropine, so as to paralyse the ciliary muscle, we find that the patient's long sight is hardly affected at all. In fact, in the normal eye, as I have before stated, the lens is passive when examining objects at more than twenty feet distance, consequently paralysis of the ciliary muscle only slightly affects the far point.

In *Myopia*, or short-sightedness, parallel rays of light are brought to a focus anterior to the retina, divergent rays alone being focused on the retina. This condition may be induced by increased refractive power of the dioptric media, or by elongation of the eye-ball in the antero-posterior axis.

Myopia is often congenital, but may arise from over-exerting the eyes upon minute objects, or by straining them in consequence of defective vision caused by opacities in the dioptric media. Under these circumstances, congestion of the choroid is brought on, and, among those predisposed to the disease, a bulging of the sclerotic takes place posteriorly, so that the antero-posterior axis of the eye is elongated, and rays of light are brought to a focus anterior to the retina. It is not that their point of intersection is in an abnormal position in this case, but the layer of rods and bulbs is drawn backwards, so that rays impinging on it form a dispersed circle of light. In this way sclero-choroiditis posterior is a common cause of myopia; in fact, Von Graefe states, that as a general rule, if a patient's far point does not exceed five inches, the myopia is due to that disease; and there can be no doubt that nearly half the cases of short-sightedness we meet with arise from this cause. As I have already described, in a previous lecture, the symptoms, progress, and probable termination of sclero-choroiditis, there is no necessity for my entering on a further examination of this cause of myopia. You cannot, however, too strongly impress on your patients who may be suffering from that affection, the necessity of avoiding overwork, particularly in the stooping posture; if they persist in this, they must inevitably, in time, become hopelessly blind. Nor should such patients be allowed to read with the object too close to their eyes, for the force exerted by the internal rectus to keep up the convergence of the

eyes under these circumstances, causes an amount of pressure on the globe, which tends to augment the congestion of the choroid.

Short-sightedness may be induced by the fibres of the lens having lost their elasticity, in consequence of long-continued work at minute objects; for the convexity of its anterior surface being, under these circumstances, constantly increased, to keep up the necessary accommodation, the lens ultimately retains this form, and of course its refractive power is augmented, and myopia is the result.

It would appear almost unnecessary to remark, that when a patient consults us for shortness of sight, we should, in the first instance, ascertain if the case be one of simple myopia, or of some other form of disease inducing symptoms of a somewhat similar nature; nevertheless, mistakes too often arise through neglecting to make these necessary inquiries. Myopia is characterized by objects at the near point of vision being distinctly seen, whereas those at a distance are very indistinct; but on placing a suitable pair of concave glasses before the myope's eyes, he at once defines distant objects with perfect accuracy, provided there be no impairment of vision in addition to the myopia. On the other hand, if the apparent shortness of sight arise from other causes, near objects will generally appear dim, and the far sight will certainly not be improved by concave glasses. The physiognomy of many myopes is peculiar, they are in the habit of almost closing their eyelids when looking at an object; by so doing they exclude a number of the

rays entering the eye, and diminish the circles of diffused light on the retina.

As I mentioned in my first lecture, it is by no means uncommon to meet with individuals feigning to be myopic; but with the ophthalmoscope, any such attempt at deception may be detected; for if, under these circumstances, the direct method of examination be employed, the fundus of the eye will be clearly seen at a distance of 14 inches, but the disc, or any other part of the retina then brought into focus, will seem to move in the opposite direction to the eye of the observer, the image being reversed. It is important to remember this, because in hypermetropia the fundus of the eye may be seen equally well, but the image will be erect, as I shall presently explain to you. The ophthalmoscope will also at once reveal the cause of the myopia, if it arises from sclerochoroiditis posterior. In the remaining cases, the fault lies in the too great refractive power of the eye, and we may with confidence trust to afford the patient relief by supplying him with a well-selected pair of concave glasses; unless, indeed, the myopia be rapidly increasing, in which case the prognosis must be most guarded, for in the majority of instances, symptoms of this kind are of a very serious import.

It is an error to suppose that, as a general rule, those suffering from myopia have prominent corneæ; Donders states that the reverse of this is usually the case, though no doubt conical corneæ may give rise to short-sightedness.

With regard to the form of glasses to be used by

patients suffering from myopia, or, in fact, from any disease of the eye requiring them, spectacles are far the best. They should be made to fit so that the glasses may be parallel with the patient's irides, and they should be placed as near the eye as possible, without allowing the cilia to brush against them when the lids are closed.* Those with a spring fitting over the nose are objectionable, because the patient is apt to clap them on carelessly, sometimes close to the eyes, and at other times on the tip of the nose; moreover, they are frequently worn anything but parallel with the irides. An eye-glass is still more objectionable than the spring spectacles; a common consequence of wearing it is, that one eye, being seldom used, takes to squinting outward, the strong external rectus muscle tending to drag it in that direction when unopposed by the internal rectus. The latter muscle, under ordinary circumstances, is constantly in use to keep the axis of the eyes inverted for near vision, and if unemployed for a long time, becomes atrophied, when the external rectus assumes its superiority and draws the eye outwards.

To determine the focal length of the glasses to be given to a myopic patient, it will be necessary, in the first instance, to ascertain what is the furthest distance at which he can read No. 1 of Snellen's test types; in fact to determine the distance of his "far point."† Suppose he can clearly define No. 1, up to eight

* Sichel on *Spectacles, their Use and Abuse*, page 21.

† Vide *Lectures on Long, Short, and Weak Sight*, by J. Soelberg Wells. 1864. Page 61.

inches from the eye ; this being his far point, he will require a concave lens of eight-inch focal length, which, by the dispersive power it possesses, will counteract the excessive refractive power of his eye, enabling him to bring parallel rays to a focus on his retina, and thus correct the existing myopia. It may be, however, that No. 8 is not precisely the power best adapted to the case, and this may be ascertained by first placing a concave and then a convex glass before the No. 8 lens ; should the former improve the sight, No. 8 will not be sufficiently powerful to neutralize the myopia ; if, on the other hand, a convex lens improve the sight, No. 8 is too strong a glass, and we must try a weaker one ; but should neither concave nor convex glasses improve the sight, we may depend upon this being the power necessary to correct the existing myopia. Mr. Wells observes,* “ a short-sighted person may desire to have spectacles which enable him to see objects at a distance of about two feet (for instance, the music, whilst he is playing the piano). Let us suppose that he requires concave 12 for distant objects. How are we to find the right number for objects two feet distance ? Simply thus :—If his myopia equals about $\frac{1}{12}$, the number required for objects at 24 inches will be found thus : $-\frac{1}{12} + \frac{1}{24} = -\frac{1}{24}$. Hence a concave 24 will suit him for seeing at 2 feet distance.”

Whatever glasses you may recommend, the patient should be ordered to wear them close to his eyes and

* *Lectures*, page 64.

to use them constantly, so as, if possible, to prevent his eyes from being overstrained either in reading, or writing, or in fact in any other way; for, as I have before pointed out to you, any long-continued effort on the part of the myope to distinguish either near or distant objects, must cause congestion of the choroid, or at any rate induce changes in the lens, which of themselves are sufficient to produce myopia in those predisposed to the disease. As a general rule, the patient as he advances in life will require weaker glasses.

Hypermetropia is a defect of vision depending on a want of refractive power in the dioptric media, or else on a shortening of the antero-posterior axis of the eye-ball, so that, during repose of accommodation, parallel rays of light which enter the eye, converge towards a point behind the retina, and convergent rays alone can be brought to a focus upon it. The consequence is, that the hypermetropic eye is obliged to exert its accommodating power to bring even rays from distant objects (parallel rays) to a focus on the bacillar layer; and for near objects (divergent rays) this effort has to be considerably increased, so that both the far and near point of vision are disturbed. *Hypermetropia* may not be attended by any very striking symptoms; the patient's sight is imperfect, but by an effort of accommodation he can generally so far overcome the defect as to be able to perform all ordinary work. Sooner or later, however, symptoms of *asthenopia* supervene, the words which he is

either reading or writing appearing to run into one another, and becoming very indistinct; distant objects, are also confused, so that in fact the patient's sight becomes exceedingly defective. The immediate cause of this new state of things, must be sought in the straining to which the accommodatory mechanism of the hypermetropic eye is exposed, in order to increase the convexity of the anterior surface of the lens, so as to compensate the existing deficiency of refracting power, and to correct, in some measure, the hypermetropia; after a time, the patient can no longer maintain the accommodatory effort which is necessary for this purpose, and hence the symptoms above noticed (asthenopia).

Hypermetropia may arise from congenital malformation of the eye-ball, its antero-posterior axis being shortened; or the same result may follow from *aphakia*, that is, absence of the crystalline lens. Under these circumstances we can readily understand, that rays of light passing through the dioptric media cannot be brought to a focus on the retina, unless, indeed, the focal distance be shortened by means of a convex lens held in front of the eye. The majority of cases of hypermetropia, however, are induced by a diminution of the refractive power of the dioptric media, which, by subsequently causing asthenopia, gives rise to the defective vision.

It is by no means an uncommon circumstance to meet with cases of *hypermetropia complicated with strabismus*; this is explained by the fact, that when a person is using his eyes for near vision (divergent

rays) the action of the internal recti, in converging the optic axes upon the object under examination, is accompanied by a corresponding automatic action of the ciliary muscle to produce the requisite amount of accommodation. In hypermetropia the convergence no longer corresponds with the accommodation required, but the hypermetropic patient unconsciously avails himself of this natural association of movements, and assists the sustained action of the ciliary muscle which is necessary for distinct vision, by an extraordinary exertion of the internal recti.* This appears to be one of the most common causes of internal strabismus. In the earlier stages of the disease, when the strabismus is intermittent, it may be corrected by the use of convex glasses, to neutralize the hypermetropia, but in the majority of cases it is necessary to divide the internal rectus. This operation should be performed as soon as possible, otherwise the sight of the squinting eye becomes materially impaired; the image formed upon it being ignored by the sensorium, and the nervous apparatus not being exercised, atrophy ultimately ensues. After tenotomy, it is absolutely necessary the patient should be supplied with glasses to neutralize the hypermetropia.

In a case of suspected hypermetropia the ophthal-

* "There exists a certain connexion between accommodation and convergence of the visual lines; the more strongly we converge, the more powerfully can we bring our faculty of accommodation into action. A certain tendency to increased convergence, so soon as a person wishes to put his power of accommodation upon the stretch, is therefore unavoidable."—*On the Anomalies of Accommodation and Refraction of the Eye*, by F. C. Donders. Translated by W. D. Moore. 1864. Page 294.

moscope should be made use of, and if this affection exist, we shall notice, by the direct method of observation, at a distance of fourteen inches from the eye, an *erect* image of a vessel or any spot on the retina, the test being that the object moves in the same direction as the eye of the surgeon. The reason of this is, that the course of the rays of light reflected from the fundus, on emerging from the hypermetropic eye, must be divergent, whether the condition arise from diminution of the axis of the eye or from a too low power of its refractive media; and they consequently present the observer with an erect image of the retina. In myopia, the image is *inverted*, in consequence of the rays of light crossing one another before they reach the observer's eye; and in the emmetropic eye, the image, by the direct method of examination, at a distance of fourteen inches, is so indistinct, that the details of the fundus cannot possibly be defined.

If the hypermetropia arise from the eye-ball being flattened from behind forwards, it may generally be detected by making the patient turn his eye inwards, when the peculiar conformation of the globe will be at once noticed. If we test the sight of a person suffering from hypermetropia with Snellen's types, we shall find that there is considerable imperfection of vision at both the near and far points, the larger types being proportionately better seen than the smaller ones, which the patient will naturally hold very close to his eyes, so as to gain the full advantage, which the convergence of the optic axes affords him,

of increasing the power of accommodation, and also of enlarging the retinal image. In looking at objects at a distance, as, for instance, No. 20, at twenty feet from the eye, although the letters may be clearly defined at first, the accommodatory apparatus being brought into play to focus even parallel rays; yet this strain on the ciliary muscle soon becomes greater than the patient can bear, and its tension giving way, the letters become indistinct, and a tendency to internal strabismus is observed. If suitable convex glasses be now placed before the patient's eye, all these symptoms disappear, the rays of light being brought to a focus upon the bacillary layer of his retina; and this, in fact, is the correct mode of treatment in cases of this kind, though no doubt, till Von Graefe and Donders, by their admirable researches, had elucidated the nature of hypermetropia, many patients suffering from it underwent all sorts of torture, for suspected incipient amaurosis and the like.

Donders divides hypermetropia into three classes:—*The facultative*; in which the patient is able to see well (with parallel optic axes) at infinite distance, with or without the aid of convex glasses, and his sight is generally sufficiently acute to enable him to read small print; but after a time symptoms of asthenopia arise.

Relative hypermetropia: in this form, the accommodation and range of vision are also good, but the patient is obliged to assist the action of the ciliary muscle by the internal recti, converging the optic

axes on some point nearer than the object he is looking at, and he thus acquires an internal squint. The sight is always more or less defective.

Absolute hypermetropia ; in which vision is very indistinct both for near and far objects, the patient not being able to focus rays of light on the retina, however great the effort of accommodation, combined with the strongest convergence of the optic axes. On a superficial examination, such a person might be mistaken for one suffering from amblyopia.*

You will observe, therefore, that hypermetropia, as a general rule, is complicated with anomalies of the accommodation of the eye, and it frequently becomes necessary to ascertain to what extent the impairment of vision is due to alteration in the shape of the eye-ball, or to a too low power of the refractive media, as distinguished from impaired accommodation ; this may be readily done by paralysing the ciliary muscle with a strong solution of atropine. For example, a patient comes to us suffering from symptoms of hypermetropia, and we find that he can read No. 20 of Snellen's test types, at a distance of twenty feet, with a No. 20 convex lens ; we then paralyse the ciliary muscle with atropine, and find that he cannot distinguish the letters with No. 20, but requires No. 10 convex lens to see them clearly : the difference, therefore, between these lenses, expresses the amount of accommodation employed in this case.

In order to ascertain the number of the glasses

* *Vide* S. Wells' Lectures, page 159.

necessary to correct the defect of vision in a case of hypermetropia, the patient should be directed to read No. 20 of Snellen's test types at a distance of twenty feet; this he will probably be unable to do without the aid of convex glasses. Supposing that with No. 30 he reads this sized print clearly, it will then be necessary to destroy his accommodating power with atropine, and this having been done, we find, perhaps, that he now requires No. 20 convex glasses to define the same letters; we must therefore strike the difference between the two powers, and supply our patient with No. 24 or No. 26 lenses. We may further test their defining power, by placing first a convex and then a concave glass in front of his spectacles: if neither of these improve his sight, we may be sure that the glasses we have given him are correct, otherwise they must be altered, as I explained to you when speaking of myopia.

We sometimes meet with cases of hypermetropia, in which there is considerable hyperæmia of the retina, induced by constantly overstraining the eye; and if this condition has lasted for some time, the nervous apparatus will be more or less damaged, and imperfect vision must be a permanent result. The patient's sight, however, may be considerably relieved by the use of convex glasses, unless irreparable damage has been done to the nervous tissue. If the latter class of cases be excluded, a pair of properly adjusted spectacles will completely remove the symptoms of hypermetropia, the rays of light being brought to a focus upon the retina; and as there will be no further

necessity for any increased accommodative effort, the asthenopia will disappear together with the hypermetropia.

The distinctions between the various affections of the eye we have been considering, are well shown in this table, copied from Mr. J. Z. Laurence's work on the *Optical Defects of the Eye*, p. 30.

The Eye in a State of Rest, (= Crystalline at its Minimum Curvature; Optic Axes Parallel.)

1. Eye:—	2. Parallel rays are focused:	3. Far-point:	4. Eye in a state of rest, adapted for:	5. Effect of glasses for distant objects:
I. Normal.	<i>On</i> the retina.	At an in- finite dis- tance.	Parallel rays.	Convexes and concaves deteriorate vision.
II. Myopic.	<i>In front</i> of the retina.	At a definite distance and positive.	Divergent rays.	Concaves im- prove vision.
III. Hyper- metropic.	<i>Behind</i> the retina.	At a definite distance and negative.	Convergent rays.	Convexes im- prove vision.

Presbyopia is essentially a disease of old age; it consists in a defect in the accommodating power of the eye, arising from alterations in the fibrous structure of the lens, which prevent the convexity of its anterior surface from becoming increased, in correspondence with the contractile power exercised by the ciliary muscle; and, in consequence, the near point of sight is removed to a distance of not less than eight inches from the cornea. In an uncomplicated case of

presbyopia, however, the focal error may be completely corrected by applying a suitable convex lens in front of the eye, so as to compensate the loss of refractive power caused by the changes in the lens.

The alterations which result in presbyopia may be said to commence from the age of ten years, when the near point begins to recede. At five-and-forty, its distance from the cornea is usually upwards of eight inches; the eye is then pronounced to be presbyopic, and as the patient experiences, for the first time, some little inconvenience in reading and writing, he probably applies for relief. His far point, however, remains unaffected; for, as I have repeatedly stated, the lens and ciliary muscle are passive, when objects at a distance of twenty feet, or upwards, are under examination.

Presbyopia, as I have before remarked, may be completely neutralized by proper lenses, and we may safely order our patient convex glasses, which will enable him to read No. 1 of Snellen's test types at 12 inches from his eyes. The spectacles should be worn so that the patient may look over them when using his eyes for distant objects. This defect of vision may be complicated, of course, with myopia, hypermetropia, or, in fact, with any other form of disease, which, if it exists, must be taken into account, independently of the presbyopia.

Asthenopia arises from defective muscular action, the internal rectus being at fault in motor asthenopia,

and the ciliary muscle in the accommodatory form of the disease.

If a ruler, or any other object, be held at a distance of some twenty feet from a person's face, and he be directed to keep his eyes steadily fixed on it, as it is gradually brought nearer to him, we notice that his eyes converge upon it; and, when the object is brought within four inches of his eyes, they will be inverted in a very marked manner. This inward movement of the eyes is perfectly symmetrical in healthy vision, so that the rays of light proceeding from the object under observation, fall upon precisely corresponding spots on both retinae (the maculae luteae). If, however, from any cause, the power of the internal rectus in one or both eyes becomes weakened, so that when the patient is engaged in looking at a near object, as for instance in reading, the muscle can no longer contract sufficiently to counteract its antagonistic muscle; under these circumstances, the eye, in place of being inverted, will be more or less everted by the external rectus, and the rays from the object under examination not falling upon exactly similar points of the retinae in both eyes, diplopia results (*vide* Fig. 10). It is this condition which constitutes *motor asthenopia*.

In the case of a person suffering from myopia, it is evident that, as he reads and writes with the book or paper close to his eyes, the internal rectus must be kept constantly contracted; and from being thus overstrained, in the course of time, the muscle becomes exhausted, and the person being no longer able to maintain the effort necessary to invert the eyes, the

external rectus asserts its superiority, and the globe is turned outwards. This is often increased by the peculiar conformation of the eye-ball, which being elongated in the antero-posterior axis, its centre of motion becomes altered, necessitating increased action of the internal rectus to converge the eye upon near objects ; and thus the tendency to motor asthenopia, from overstraining of the internal rectus, is augmented. If a change of this kind in the direction of the eye takes place while the patient is reading, the words appear to run into one another, and become very indistinct, and he is obliged to rest his eyes for a time till the exhausted muscle can recover itself. Should the patient, however, in place of discontinuing his work, endeavour by an increased effort to go on with it, he may possibly be able to do so for a short time ; but the eyes then begin to give him pain from congestion of the choroid, and headache supervenes, so that he is ultimately compelled to take rest.

Motor asthenopia, therefore, is seldom met with, unless among myopes, or those engaged in work which necessitates their bringing the object upon which they may be employed very close to the eye ; in either case the overstraining of the internal rectus is the origin of the disease. The symptoms of this affection are those I have above described ; the patient complains that, after writing or reading for a time, the words or letters appear to run into one another ; and if he persist in using his eyes, he suffers from pain in them, extending to the eyebrow and side of the head. After resting for an hour or so, these symptoms disappear,

and he can again continue his employment for a longer or shorter period.

The most simple way of detecting the existence of this form of asthenopia, is to place a ruler or some such object in front of the patient, and direct him to look at it steadily while you slowly bring it nearer to his face. If motor asthenopia exist, you will notice, in the course of a few minutes, that one of the patient's eyes will begin to quiver, and then gradually become everted, and he will at once tell you he can no longer see the object distinctly. Von Graefe has devised a very simple means of detecting not only the existence but also the degree of asthenopia. A large black spot, about the size of a split pea, is to be made on a sheet of white paper, and through this spot a perpendicular line must be drawn; the patient is then directed to look steadily at the figure, and a prismatic glass, with its base turned upwards, is to be placed before first one eye, and then the other. If he be emmetropic, the prism will simply cause two spots to appear on the paper, one above the other; but if asthenopia should exist in either eye, one of the spots will be seen in its real position, and the other above it, and to the right or left of the perpendicular line. Now, in order to discover the degree of the diplopia, which is the cause of this deviation of the spot from the perpendicular line, all that is necessary, is, to put a second prism, with its base outwards or inwards as the deviation of the spot may indicate, in front of the first one. The angle of the prism, required to restore the spot to its position on the perpen-

dicular line, will indicate the amount of existing diplopia.

The treatment of motor asthenopia may either be palliative by means of glasses, or complete, by division of the muscle antagonistic to the weakened one.* If the former plan of treatment be adopted, the use of concave lenses, by preventing the necessity of the patient's bringing objects very close to his face, as in reading and writing, saves the constant strain which would otherwise be exerted on the internal rectus; and by harbouring the strength of this muscle, enables it to contract when called on to do so, and to converge the optic axes upon an object close before the eyes. Or we may, by the use of proper prisms, correct the diplopia by bending the rays of light upon the macula lutea of the everted eye, in this way reproducing binocular vision. In very slight cases these means may prove effectual; but in the majority of instances, it will be necessary to do more than this, and to cut through the tendon of the external rectus in the manner I described to you when lecturing on

* Donders remarks that "Von Graefe has established the indications for tenotomy with great accuracy. The condition for the operation is this, that under the attempt at single vision, a sufficient divergence of visual lines should appear to be possible. This should be tried (after neutralization of the myopia by concave glasses placed at a proper distance from each other) with prismatic glasses; we should investigate with what prismatic glasses held with the refracting angle outwards before the eyes single distant vision is still attainable. The strongest glasses then which can still be overcome give the measure of the possible divergence. It is allowable now so to perform tenotomy that this possible divergence shall be completely removed. If the strabismus is evident without prisms there can be no doubt of the propriety of dividing the internal rectus."—Moore's Translation of Donders, p. 428.

strabismus. Great care, however, is necessary to divide only so much of the muscle as will prevent it from overcoming the contractile power of the internal rectus, otherwise you will simply complicate matters by converting the external into an internal strabismus. If the operation be properly performed, and the antagonistic muscle to the overstrained one, whichever that may be, is carefully divided, motor asthenopia cannot, of course, exist.

Accommodatory asthenopia.—The symptoms of this form of disease are very much akin to those described as characteristic of motor asthenopia, except that the patient's eye is not everted after being used for a time. Patients suffering from accommodatory asthenopia have often very good long and short sight; they simply complain of the words or letters they may be reading appearing confused, and running into one another after a few hours' work. If, in spite of this, an effort is made to continue reading, the eyes become painful and weary, and it is then absolutely necessary to rest them for a time; but in ten minutes or a quarter of an hour the patient can resume his employment. These symptoms arise from inability on the part of the ciliary muscle to keep up the accommodative effort, which is necessary for bringing divergent rays to a focus on the retina. The muscle, from being overworked, or from general debility, soon becomes fatigued, and being no longer able to contract, it gives way; the anterior surface of the lens then recedes, so that parallel rays of light are alone correctly focused on the bacillar layer. The patient

can therefore see objects at a distance, although the words he may be reading or writing appear indistinct. A little rest speedily restores the power of the ciliary muscle, and he can again set to work for a time.

The ophthalmoscope may be useful in these cases, to enable us to ascertain that no positive disease exists, either in the dioptric media or the fundus of the eye. Hyperæmia of the retina, it is true, will generally be detected; and, as I have before observed, this should never be regarded as a small matter, although in this instance it may not indicate any serious derangement of nutrition, being merely an effect of the prolonged strain to which the apparatus of the eye has been exposed, in the effort to maintain the necessary accommodation.

The majority of cases of accommodatory asthenopia depend upon hypermetropia, and when this is corrected with proper convex glasses, the ciliary muscle, being no longer overstrained, will be able to maintain the necessary convexity of the lens to focus divergent rays, and the symptoms of asthenopia will disappear. Under any circumstances, a pair of weak convex glasses, by increasing the refractive power of the eye, will obviate the necessity for any great alteration in the convexity of the lens for near objects, and thus relieve the ciliary muscle; but the patient should be enjoined to rest the eye as much as possible, and very often a tonic plan of treatment is called for. I have known several cases of this kind, in which the asthenopia had apparently been brought on by general


derangement of the health, and a change to Europe entirely removed the troublesome symptoms from which the patients were suffering.

By *astigmatism* is meant, a peculiar condition of the dioptric media, such that their refractive power varies in different meridians of the eye, so that in one plane it may be hypermetropic, and in another myopic; the consequence is, that "rays emanating from one point, are not reunited into one point" after traversing the eye, and thus a very imperfect image is formed on the retina, as stated in an earlier part of the lecture.* The patient usually complains of the letters or words he may be reading crossing one another, and becoming confused, and in the effort which he makes to accommodate, first for one meridian and then for the other, the ciliary muscle becomes strained and asthenopia is the result.

Astigmatism is, in the majority of cases, an hereditary affection, but it may be caused by disease, leading to alteration in the normal curvature of the cornea; in the former class, both eyes are usually affected in a symmetrical manner, but in the latter this is not likely to be the case. Donders says that very many instances of supposed incurable amblyopia arise from astigmatism, especially among persons suffering from hypermetropia; the astigmatism and hypermetropia being caused by malformation or abnormal changes in the cornea. It appears from his

* *Vide J. S. Wells' Lectures*, p. 179, and the present lecture, p. 250.

Fig. 11.



researches, that even in the emmetropic eye, there is a marked difference between the refractive power possessed by the horizontal and vertical meridians of the eye. This fact may be demonstrated by placing a series of lines, like those drawn in Fig. 11, at a distance of ten or twelve yards from the observer; the perpendicular stripes can be clearly seen, whereas the horizontal ones will remain indistinct at even a nearer distance from the figure. The converse of this holds good; if the lines are brought close to the face, the perpendicular ones become confused, whereas the horizontal remain well defined. It is evident, therefore, that the horizontal and vertical meridians of the healthy eye differ in refractive power; but so slight is this defect, that it causes us no inconvenience under ordinary circumstances, though it is easy to understand, that if this state of things be increased, very considerable impairment of sight must result.

Several very ingenious methods have been invented to test the amount of astigmatism in any particular case; among these, the ophthalmoscope holds a very prominent position, and it seems to me to afford the most easy means not only of detecting astigmatism, but also of determining its degree, and the plane in which it is situated.

If an eye affected with astigmatism be examined by the *direct* method, the optic disc will appear elongated either in the vertical or horizontal direction, its greatest apparent diameter corresponding to the direction of the most convex meridian of the cornea; for it is evident that the rays of light in this plane

will suffer a greater refraction, and therefore present a more highly magnified image of the disc, than in any other. If the eye be now examined by the *indirect* method, the direction of apparent elongation of the disc will be exactly reversed.

If a person, whose eye is healthy, be directed to look through a plate of violet coloured glass, fixed in a black screen, the glass will appear to be surrounded with a red rim; this is accounted for by the different refrangibility of the rays of light. In the case of astigmatics, the refraction seems to be completely altered; for if the above experiment be repeated upon a patient suffering from this form of disease, the vertical meridian being myopic and the horizontal hypermetropic, the opening in the screen will appear surrounded above and below by a blue rim, and on either side by a red one. Another method of ascertaining the existence of astigmatism, is to place the patient at some distance from a bright spot of light, upon which he is directed to keep his eye steadily fixed, looking at it through a hole in a screen; before this opening, first a concave, and then a convex lens is to be held, thus rendering the eye alternately myopic and hypermetropic. If astigmatism exists, the spot of light will appear elongated either in the vertical or horizontal direction, as the foci of the rays of light proceeding from it are altered by the uneven surface of the cornea. Von Graefe's optometer is the most easily managed instrument yet invented for the detection of astigmatism; but as I have before stated, for all practical purposes the ophthalmoscope affords

us an admirable means of distinguishing cases of this nature.

Donders has divided astigmatism into three kinds:—

I. *Simple astigmatism*, in which the principal meridian is emmetropic, the other being myopic or hypermetropic.

II. *Compound astigmatism*; either myopia or hypermetropia existing in both of the principal meridians, but differing in degree in each.

III. *Mixed astigmatism*, in which one of the meridians is myopic while the other is hypermetropic.

Astigmatism may be corrected by properly adapted *cylindrical lenses*. J. Z. Laurence remarks that “A spherical lens is a segment of a sphere, and refracts the incident rays of light equally in all planes of the segment; a cylindrical lens is the segment of a cylinder, and refracts rays of light most in a plane at right angles to the axis of the cylinder of which it is a segment, whilst those rays of light which strike it in the plane of the axis, undergo no refraction whatever. For the sake of simplicity we may therefore restrict our considerations to these two directions—that of the axis and that of the transverse diameter. A 6-inch convex cylindrical lens means one which refracts a pencil of parallel rays thus: (1), those which strike it parallel to the transverse diameter of the cylinder are focused at 6 inches from the surface of the lens; (2), those which strike it parallel to the axis of the cylinder are not focused at all by the lens, but pass through it refracted not more than they

would have been by passing through a piece of plain glass.”* To counteract, therefore, defective vision induced by astigmatism, in which the principal meridian is normal, the other being myopic or hypermetropic, a cylindrical lens is employed; the rays passing through its axis undergo no change, while those passing through a plane at right angles to this, should undergo the amount of refraction necessary to neutralize the abnormal condition of the corresponding meridian of the cornea; and the same principle applies to the other forms of astigmatism.† Having, therefore, in the first instance, discovered the exact nature of the changes that have occurred in the curvature of the cornea, cylindrical glasses must be adapted to counteract the abnormal refraction. A very considerable amount of study and experience is required, to enable one to master difficult and complicated cases of this kind; but having once overcome them, one of the greatest triumphs in the practical application of ophthalmic science is achieved; namely, the adaptation of cylindrical glasses to correct the impairment of vision caused by astigmatism. I may here quote one of Donders’ cases bearing upon this point.

“CASE VI.—Mr. V., aged 59 years The *right* eye is nearly emmetropic: improvement of vision at a distance by convex $\frac{1}{60}$ is doubtful; concave $\frac{1}{60}$ acts injuriously. Experiments with the point of light afford no proof of abnormal regular astigmatism, but indicate a highly-developed irregular astigmatism.

“From youth, the patient has been unable to use his *left* eye; however, there exists neither obscurity nor organic change in the fundus oculi. Positive and negative spherical glasses produce no improvement. The

* *Optical Defects of the Eye*, by J. Z. Lawrence, p. 65.

† *Vide* S. Wells’ *Lectures*, p. 192.

reflected images of the cornea had suggested the idea of asymmetry. Examination with the ophthalmoscope afforded the proof of it: in the non-inverted image, I, as an emmetrope, saw, with some tension of my accommodation, vertical vessels of the retina perfectly acutely; horizontal vessels, on the contrary, appeared, on tension of accommodation, very faint, and on perfect relaxation were not well defined. I hence inferred the existence of myopia in the vertical, and of hypermetropia in the horizontal meridian. On examination with the point of light the principal meridians seemed to deviate little from the vertical and horizontal planes; the most slender vertical line was seen with convex $\frac{1}{45}$, the most slender horizontal with concave $\frac{1}{30}$. The diagnosis was: mixed astigmatism = $\frac{1}{18}$ composed of

$$\text{Myopia } \frac{1}{30} + \text{Hypermetropia } \frac{1}{45}.$$

The cornea more than fully accounted for this: the radius of curvature in the visual line amounted, in the horizontal plane, to 8.29 mm., in the vertical = 7.69,— indicating an astigmatism of 1: 11.67. While (at least by the method with the point of light) only a mixed astigmatism $\frac{1}{18}$ was found, the crystalline lens appeared to compensate in part for the astigmatism of the cornea.

“Quite in accordance with the ametropia in both principal meridians, the left eye sees at a distance vertical lines a little better than horizontal. With convex $\frac{1}{45}$ horizontal lines are still more indistinctly visible, while vertical lines are acutely seen. *Vice versa*, with concave $\frac{1}{30}$ horizontal lines are very well seen, vertical lines, on the contrary, are only faintly perceptible.

“For distance, a flat glass was prescribed for the right eye; for the left a bi-cylindrical glass of $\frac{1}{45} c \text{ } \Gamma - \frac{1}{30} c$. For close work, I was anxious, the acuteness of vision not being perfect, to bring the far point to 12". This was effected by means of a spherico-cylindrical glass of $\frac{1}{20} s \text{ } \subset - \frac{1}{18} c$: with $\frac{1}{20}$, in fact, the far point in the vertical meridian ($\frac{1}{30} + \frac{1}{20} = \frac{1}{12}$) becomes = 12", and with $\frac{1}{18} c$, the far point in the horizontal is made equal to the far point in the vertical. Hereby the right eye now acquired simply $\frac{1}{12} s$. The images were of nearly equal magnitude, and the vision was with both eyes at the same time very pleasant. Vision with the left eye was more acute than with the right.”*

Should the astigmatism have been induced by ulceration of the cornea, it will often be necessary to make an artificial pupil, and then, with the aid of cylindrical glasses, the patient's sight will probably be vastly improved.

If a minute hole be drilled in a piece of metal, and

* Moore's Translation of Donders, p. 530.

held close to an emmetropic eye, accommodated for distant vision, the spot, instead of appearing round, looks as if it were star-shaped; that this is due to the lens, is proved by the fact, that when the lens is removed no such appearance is produced, and if the cornea be neutralized by holding the eye open in a small vessel of water, bounded by a convex glass side, the hole appears still to be star-shaped, provided the lens is *in situ*. Donders explains this fact by reference to the anatomy of the lens, which is, as you are aware, divided into sectors by its fibrous bands, each sector forming a separate image. He further demonstrates it by moving a small opening in a metallic plate before the eye; "when the opening comes in front of the boundary between two sectors, two faint images appear, of which, on further displacement, that first seen disappears, while the one which has supervened remains alone and brighter." If, therefore, there be any abnormal condition in these sectors of the lens, we can readily understand that it must interfere with the perfection of vision; more particularly as the rays of light passing through each sector are subject to the laws of spherical aberration. The anomalies of refraction thus caused are classed by Donders under the heading of *Irregular Astigmatism*, and I cannot do better than refer you to his work on the *Accommodation and Refraction of the Eye* for further information on the subject; and also to Mr. S. Wells' *Lectures on Impaired Vision*, to which constant reference has been made in this lecture.

কমি সোভারেনে লেই বিলাসঃ শাস্ত্রতোতমঃ। তব নানাভিহে হাটুগাম্য যত্নে বহিঃশেখিতমসি। অথ নদ্যঃ খিটবৎগাম্য যত্নে জমাতমল বুদ্ধিবলোমহি ভগ্নমসি কুশুরিতৌনামকৈ
বস্তুমসি হাটুপতননাম্য ভাষ্যঃ বহুতঃ কৃন্যসিহি হিহিসমটমৎ ভাধমবপ্য়ত্। তমবলোম্যবিন্ধ্যত্ প্রথ শতরোমিহি চুটু স্তমং জাতং নমো কিসনশিবনং দক্ষিণাশ্চি।

শ্রেয়ঃ যোগ্যঃ বশেণ প্রদলনঃ অবলোমহিঃ প্রতি অশেণেব দৃষ্টি অভিহায়ে। পুরুষপরে মধ্য জাহাশেত শিষ্কন বিধান প্র নিজাত্ত জাবিশ্চাক, কছিত্র
অন্তলন পূর্ববন্ধন প্রবনান হইয়েনা, অশেণ অশক্ মশেণ ৩ ইশকিত ২ জবুলনন বই; ইহাও অশল বৃক্ষিগায়ে। অশবলোমিহি এই ইশেণে মশ-হিহি

* * * * *

N° 2.

মদি স্তমরমগাম্য নাপি সৃশো ঋশ্মিতি যুক্মিতিঃশ্যাতঃ প্রমাতম্। কৃষ্ণ মরগ্য মব পূয় শিব বন্তোঃ কিমিতব মুখা মসিনং যশ্ঃকুরু ধবম্ ॥
পুত্রেমিতোম্য; তদ্বলমিত্যনো ময় রূপলৈচুপমগা; ময় স্ত জালি, কনকঅলধর্ প্রমাণ্যসুরেপ্তা বগবহ্মিননকলীত স্য স্মগা মুগা ম্ভেগ্ন যানত
বামাশেব বিদ্যা শিষ্কর কতক গুলি প্রতি বন্ধক আছে। তাহার মময় পায়না, উৎসাহ পায় না, শিষ্করক সাত্ম্যও জাপূশ লাভ করিতে
পারেন। অতএব অশেণ মময়ে জাপন জাময় মতে প্রয়ো জনীয় জ্ঞান সকল উপার্জন করিতে পারে এরূপ কোন উপায় না হইলে তাহা

* * * * *

N° 4.

এবং শুল্ক তু চুবস্য প্রজ্ঞাচলুর্নরাধিপঃ। চুররাহুে দ্বিধাক্ষিতঃ শোকার্ভঃ সমবহত। তু যৌধনশ্চ কর্ণীশ্চ শুল্কনিঃ সৌতল স্তাশ্চ।
হুঃ শাসনচলুর্থা স্তে মন্থ যামাসুরেকতঃ। ততো তু যৌধনৌ রানা ঘটয়চ্চুম্মা মন। শাবস্তেবেশোময়ং ন স্যাতানু দ্বিধাস্থযাশা মন্বাত।

(জাননা ও সুরনার কথা) কখনো। জাননা। সুরনা। জামি হলে বড় দুঃখিত হইলোম্য জুয়ি না কি আর লেখা পড়া কর না?
সুরনা। জুয়ি কই জান, লেখা পড়ার জন্যে আটা আমার ডারি হইলু ছিল। কিন্তু কি করিবে? পাঁচ জনার পাঁচ কথা শুল্ক আমায় মন ফিরে

* * * * *

N° 6.

তব কেবিত বুবন্তি স্ম ব্রাহ্ময়ানির্ময়াসলদা। শীনাত্ টছ্যা পাপেভু স্যুতান তৌব মৃষাদুঃ শ্বিতাঃ ॥ নিবমং পবুযতে রাজা সর্ভাশ্চ তু সুমব্ধীঃ।
কৌরব্যো গুতরাহু স্তু নচ ধর্ম প্রপময়তি ॥ নহি পাপমপাযাশা রোষপ্রিথ্যতি পাপেহতঃ। মেমো বা বলিনাং ঐক্যঃ নৌশৌধো বা ধন স্ত্যয়ঃ। —
বামাশেব বিদ্যা শিষ্কর কতক গুলি প্রতি বন্ধক আছে। তাহার মময় পায়না, উৎসাহ পায় না, শিষ্করক সাত্ম্যও জাপূশ লাভ
করিতে পারেন। অতএব অশেণ মময়ে জাপন জাময় মতে প্রয়ো জনীয় জ্ঞান সকল উপার্জন করিতে পারে এরূপ কোন

* * * * *

N° 8.

দ্বাষ দ্বাষসস্তে ন নিবেগ সর্চ শিবালাপকশ্যা যুবেন তস্য চরসঃ সনীপং যগৌ। তনৌ মত্মগে দূরাৎ লঘুপতনকমা-
লোক্য উত্থাষ যথোচিত মা বিধ্যং বধায সুধিকশ্যা স্মতিজিযত্কারং চকার। বায়রৌ বদন্ত বস্মে মত্ময় মদ্বি-
নাবদা। নতুন যদি কিছু ভাল হয় তা কর্তে কোষ মাই কিন্তু একটা নতুন কাপড় কেও যা ভাল বলেনা তা কেমন
জরদা। লেখাপড়াটা শেখা কত বড় উপকারি পরে বলতো, আটা জোয়ার আর সব মজেহ যাক্। এটা যে

* * * * *

N° 10.

অস্মি বস্মকামিধানায়াং ননশ্মী পদ্বিজক্রা বস্ময়ঃ। তচ বুদ্ধাকর্গী নাম পরি স্কলকঃ প্রাত বস্মতি।
রোগো চিগ প্রবাসী পরাম্ভোমী পরবস্ম অশ্মী। বজ্জীবতি তম্বরগাং যম্বরগাং শৌস্ব শিষ্কামঃ নমঃগৌ
নুতন কাম্য কে জোগয় বজ্জৈ? যদি দেশের আশোকার খবর রাখতে, তাহলে জোগার লেখ হতো
আগে সব মেয়ে লেখা পড়া করতো। আজও কতো বড় বড় মেয়েদের নাম শোনায়! খনার

* * * * *

তত্বিচাঙ্কলঘুপনকাভ্যাং শীঘ্রং গন্বা তথা অনুচ্চিহে দতি স্মাঘ: জান: পানীয়ং পীত্বা তরো রুধ
 স্বাদুপমি চ স্বাখাবিধং মৃগ মবলোক্য কচ্চপং জল সমীপে নিধায় কর্ত্তিকা মায়াঘ পহু চ মনা মৃগা
 জম্বার বখাশুনো আহ আমার মজে বড লাগ্গে। কিন্তু অতকে বলে মেত্র মানুয়ে কি লেখা
 পড়া শিখা চাকরী কতে যাবে, না গভার প্রে বড়ু জ করিবে? তাহের লেখা পড়ার দরকার কি?

* * * * *

ক্রোধী হন্ত মনুষ্যাণং ক্রোধো ভাবয়িতা পুন:। ইতি বি দ্বি মহাপ্রত্নিক্রোধ
 মূলৌ ভবা ভবৌ ॥ যোহি সংহ রতে ক্রোধং ভব স্তস্য সুশো ভনে ॥ য: পুন:-

অই কিষ্কতি হুফে তুমি আবার জিজ্ঞাসা কর? একবার আমাধের
 অবস্তার গানে চেয়ে দেখ দেখি। পুরুষদের সঙ্গে অমাধের তুলনা

* * * * *

পাপপ্রিয় স্তব কথং গুণিন: স্হায: সুতাत्मज: शु.श
 ধরান্দ য সম্ভব স্য। হন্তা কিরী টিনমহং নৃপ

আমরা এই যে পৃথিবীতে আছি এর আকার কি
 রূপ, এ ক্রমেন করিয়া আছে, এতে জেশ্বরের

* * * * *

रोगी चिरप्रवासी परान्नभो परा
 वसथप्रायी। यज्जीवति तन्मरणा

मिसर देशे समुदाये ३९टा
 गिरामिड् दूष्टं ह्य। कयरो

|| || || || || || || || || || || || || || ||

हिप्ति हिप्ति परिह गथाः

भूसयः पावकेन ॥ नम

भारत वर्षे मान चित्र

|| || || || || || || || || || ||

I N D E X.

ACCOMMODATION, mechanism of, 37; paralysis of, by atropine, 252; not interfered with by removal of iris, 251; connexion between accommodation and convergence, 263.

APHAKIA, 262.

ARTERIA centralis retinae, 33; pulsation of, 44; in glaucoma, 223; embolia of, 145; apparent size of, 44; collection of blood-pigment in, 149.

ASTHENOPIA, causes of, 269; symptoms, 271, 262; accommodatory asthenopia, 274; motor asthenopia, 269; treatment of, 273, 275.

ASTIGMATISM, symptoms of, 276; regular, 276; normal, 277; abnormal, 279; diagnosis of, 277; treatment of, 279; irregular astigmatism, 282.

ATROPHY of optic papilla, 54, 48; of the choroid, 190; of the retina, 127.

ATROPINE, effects of, on accommodation, 252; on pupil, 16; strength of solution, 16, 245.

BINOCULAR ophthalmoscope, 14; vision, 252, 254.

BLOWS causing effusion of blood into vitreous, 86; into choroid, 183; detachment of retina, 133.

CALABAR bean, 252, 245.

CASES:—

- (1) Syphilitic keratitis, 56.
- (2) Iritis, from hereditary syphilis, 63.
- (3) Opacity of vitreous, from hereditary syphilis, 66.
- (4) Opacity of lens, from hereditary syphilis, 73.
- (5) Opacity of vitreous (syphilitic), 76.
- (6) Fluidity of vitreous (syphilitic), 79.
- (7) Degeneration of vitreous (anæmic), 83.
- (8) Foreign body in vitreous, 91.
- (9) Hyperæmia of retina, 98.
- (10) " " " (malarial), 103.
- (11) Hyperæmia of retina (malarial), 104.
- (12) Retinitis, deposits of lymph, 124.
- (13) Atrophy of retina, 128.
- (14) Retinitis (syphilitic), 131.
- (15) Detachment of retina, 133.
- (16) " " " 138.
- (17) Retinal congestion from extra-orbital obstruction, 142.
- (18) Retinal congestion from melanæmia, 153.
- (19) Hyperæmia of choroid (passive), 165.
- (20) Choroiditis (acute), 173.
- (21) " " 175.

CASES :—*continued.*

- (22) Plastic exudation in the choroid, 187.
 (23) Atrophy of choroid (partial), 191.
 (24) Staphyloma of optic disc, 209.

CATARACT, syphilitic, 70, 73, 234; depends on pre-existing disease, 48, 235, 248; extraction of, with excision of iris, 231, 244; linear extraction of, 237—248; the author's Indian experience of, 237; analysis of ninety-eight cases, 239.

CHOROID, anatomy of, 28; hyperæmia of, 164; inflammation of, 169; formation of lymph in, 185; atrophy of, 190; acute inflammation and effusion into, 173; treatment by iridectomy, 180; extravasation of blood into, 183; tubercle in, 189.

CILIARY muscle, anatomy of, 36; action of, in accommodation, 38.

CONJUNCTIVA, anatomy of, 22.

CORNEA, anatomy of, 25; effects of inherited syphilis on, 56; anæsthesia of, 224; changes of, in astigmatism, 276; iridectomy in ulceration of, 233.

CYCLITIS after extraction, 238, 248.

DETACHMENT of retina from injury, 133; from serous effusion, 135.

DIPLOPIA, 252.

DOUCHE in choroiditis, 171; in sclero-choroiditis, 208.

EFFUSION of serum into the retina, 104; into the choroid, 164, 182.

ELASTIC lamina, anatomy of, 27, 158; hexagonal cells of, 28; colloid disease of, 160.

EMBOLIA of central artery of retina, 145.

EMMETROPIC eye, 255, 11, 7.

EXCAVATION of the papilla in atro-

phy of the disc, 54, 214; in congenital malformation, 54; in glaucoma, 54, 53; appearance of vessels in, 52, 225, 214; effect produced by bulging forward of choroidal margin, 174, 215, 218.

FINITE rays, 250.

FOREIGN bodies in vitreous chamber, 90; entozoa in vitreous, 89.

FUNDUS of the eye, ophthalmoscopic appearances of, in Europeans, 40; in natives of India, 40, 95, 96; cause of difference between the two, 41; choroid not seen in healthy native eye, 41.

GLASSES, best form of, 259; prismatic, 254; cylindrical, 279; concave in myopia, 259; convex in hypermetropia, 267; in presbyopia, 269.

GLAUCOMA, 212; symptoms of, 221; treatment of, 226; excavation of the optic disc in, 214; not caused by intra-ocular pressure, 219; experiments relating to, 216.

HEMERALOPIA, 85.

HEXAGONAL cells of elastic lamina, 27; removal of, 158, 166.

HYALOID membrane, 35.

HYPERÆMIA of retina, transient, 94; chronic, 96; from overwork, 97; mixed causes, 97; malaria, 102; mechanical obstruction, 141; embolia, 145; melanæmia, 149; importance of treatment in, 108; of the choroid, 164; of the optic disc, 46.

HYPERMETROPIA, 261, 10; form of eye in, 262; diagnosis of, 264; treatment of, 266; complicated with asthenopia and strabismus, 262, 266, 275.

ILLUMINATION of fundus of the eye, by sunlight, 15; by artificial

- light, 16; principle and method of, 4; lateral, 20.
- INFLAMMATION** of the retina, acute, 113; treatment, 118; chronic, 120; results of, 122; syphilitic, 130; of the choroid, subacute, 169; acute, 173; results of, 182; of the cornea, 56; of the iris, 63.
- INTRA-OCULAR** pressure, 219; by artificial injection, 216; not the cause of excavation of optic disc, 217—220.
- IRIDECTOMY**, 228; in glaucoma, 226; in ulceration of cornea, 233; in effusion into the choroid and choroiditis, 177—180; before extraction of the lens, 231; necessity for breaking through the elastic lamina in, 230, 177.
- IRIS**, anatomy of, 30; nerves of, 31; inflammation of, from hereditary syphilis, 63.
- KERATITIS**, syphilitic, 56.
- LATERAL** illumination of the eye, 20.
- LENS**, crystalline, anatomy of, 36; change of form in accommodation, 37; in irregular astigmatism, 282; in presbyopia, 268; opacity of, in glaucoma, 224; in disease of the choroid, 48, 188, 165, 235; syphilitic opacity of, 70, 234.
- MACULA** lutea, 44; in native, 41.
- MALARIA**, a cause of hyperæmia of retina, 97; of opacity of vitreous, 84; of fatty degeneration of retina, 111; of melanæmia, 151; treatment of disorders from, 109.
- MALIGNANT** growth in the eye, 88.
- MELANÆMIA** of retina, 149.
- MERCURY** in syphilitic disease of the cornea, 62; in opacity of vitreous, 73; in choroiditis, 171; retinitis, 182; opacity of lens, 72; abuse of mercury among the natives, 78.
- MUSCÆ volitantes**, 82.
- MYOPIA**, symptoms of, 255, 9; pathology of, 256; prognosis of, 257; treatment of, 259; with external strabismus, 273; producing motor asthenopia, 271.
- NATIVE** eye (Hindustan), ophthalmoscopic appearances of, 40, 93, 96, 163; amount and disposition of pigment in, 27, 28; office of, 154; native Albinos, 159; colour of disc, 42; of macula lutea, 41.
- NERVES** of the ciliary muscle, 37; iris, 31.
- ŒDEMA** of the retina, 106; of the choroid, 164, 182.
- OPHTHALMOSCOPE**, method of using, direct, 6; indirect, 11; mode of conducting the examination, 17; Liebreich's, 14; Coccius', 13; binocular, 14; use of, in detecting myopia, 9; hypermetropia, 10; astigmatism, 277.
- OPTIC** disc, 42; normal appearance of, 43; inflammation of, 46; congestion of, independently of retina, 47; propagation to or from the brain, 46, 47; excavation of, 214, 52; atrophy of, 46, 48, 54.
- OPTIC** nerve, entrance of into the eye, 24; neuritis of, 46; extravasation of blood into, 51.
- PETIT**, canal of, 35.
- PIGMENT** in hexagonal cells, 27; in cells of choroid, 28; amount and disposition of, in native eye, 158; formation of, in the retina, 197; deposit of, in vessels of the retina, 153.
- POSTERIOR** staphyloma, 199, 209.
- PRESBYOPIA**, symptoms of, 268; pathology and treatment of, 269.
- PRISMATIC** glasses, 254.
- PULSATION** of retinal vessels in health, 44; in glaucoma, 215; in retinitis, 115.

- PUPIL, dilatation and contraction of, in health, 32; in choroiditis, 169.
- QUININE, abuse of, in India, 109; effects of, on vessels of retina, 110.
- RANGE of accommodation, 250.
- RAYS, finite, 250; infinite, 250.
- RETINA, anatomy of, 32; appearance of, in health, 40; in inflammation, 115; in hyperæmia, 99; atrophy of, 127; formation of lymph in, 124; extravasation of blood, 122; suppuration of, 128; detachment of, 133; melanæmia of, 149; fatty degeneration of, 111; central artery and vein of, 43.
- RETINO-CHOROIDITIS, 164.
- ROOM, arrangement of, for ophthalmoscopic examination, 17.
- SCLERO-CHOROIDITIS posterior, 199; stationary form of, 201; progressive, 204; treatment, 203, 207; common cause of myopia, 199; spurious, 203.
- SCLEROTIC, anatomy of, 24.
- SNELLEN'S test types (APPENDIX); use of, 250, 259, 266.
- STAPHYLOMA of the optic disc, simple, 209.
- STRABISMUS, external in myopia, 270; internal in hypermetropia, 262; direct, 252; crossed, 253.
- SUSPENSORY ligament of lens, 35.
- SYPHILITIC keratitis, 56; iritis, 63; cataract, 70; opacity of vitreous, 66, 76; affection of retina, 130; of choroid, 195; thickening of sheath of vessels in cavernous sinus, 144.
- TEETH, appearance of, in inherited syphilis, 59.
- TENSION of the eye, 24; mode of registering (Bowman), 212; increase in choroiditis, 170, 173, 176; in glaucoma, 223; in acute retinitis, 114; diminution in fluidity of the vitreous, 80.
- TIGER-STRIPED retina, 194.
- TOBACCO, effects on optic disc, 49.
- TUMOURS in the eye, 88.
- VESSELS of conjunctiva, 22; iris, 31; choroid, 29; ciliary muscle, 37; retina, 33; of optic disc, 47 (*note*); surround the entrance of optic nerve into the eye, 25.
- VITREOUS humour, opacity of syphilitic, 66, 76; anæmic and malarial, 83; fluid condition of, 79; flocculent bodies in, 82.

END OF PART THE FIRST.

London, New Burlington Street,
May, 1866.

MESSRS. CHURCHILL & SONS'


Publications,

IN

M E D I C I N E

AND THE VARIOUS BRANCHES OF

NATURAL SCIENCE.



"It would be unjust to conclude this notice without saying a few words in favour of Mr. Churchill, from whom the profession is receiving, it may be truly said, the most beautiful series of Illustrated Medical Works which has ever been published."—*Lancet*.

"All the publications of Mr. Churchill are prepared with so much taste and neatness, that it is superfluous to speak of them in terms of commendation."—*Edinburgh Medical and Surgical Journal*.

"No one is more distinguished for the elegance and *recherché* style of his publications than Mr. Churchill."—*Provincial Medical Journal*.

"Mr. Churchill's publications are very handsomely got up: the engravings are remarkably well executed."—*Dublin Medical Press*.

"The typography, illustrations, and getting up are, in all Mr. Churchill's publications, most beautiful."—*Monthly Journal of Medical Science*.

"Mr. Churchill's illustrated works are among the best that emanate from the Medical Press."—*Medical Times*.

"We have before called the attention of both students and practitioners to the great advantage which Mr. Churchill has conferred on the profession, in the issue, at such a moderate cost, of works so highly creditable in point of artistic execution and scientific merit."—*Dublin Quarterly Journal*.

Messrs. Churchill & Sons are the Publishers of the following Periodicals, offering to Authors a wide extent of Literary Announcement, and a Medium of Advertisement, addressed to all Classes of the Profession.

THE BRITISH AND FOREIGN MEDICO-
CHIRURGICAL REVIEW,
AND
QUARTERLY JOURNAL OF PRACTICAL MEDICINE
AND SURGERY.

Price Six Shillings. Nos. I. to LXXIV.

THE QUARTERLY JOURNAL OF
SCIENCE.

Price Five Shillings. Nos. I. to X.

THE QUARTERLY JOURNAL OF
MICROSCOPICAL SCIENCE,
INCLUDING THE TRANSACTIONS OF THE MICROSCOPICAL SOCIETY OF LONDON.

Edited by DR. LANKESTER, F.R.S., and GEORGE
BUSK, F.R.S. Price 4s. Nos. I. to XXII.
New Series.

THE JOURNAL OF MENTAL SCIENCE.

By authority of the Medico-Psychological
Association.

Edited by C. L. ROBERTSON, M.D., and HENRY
MAUDSLEY, M.D.

Published Quarterly, price Half-a-Crown. *New
Series.* Nos. I. to XXI.

ARCHIVES OF MEDICINE:

A Record of Practical Observations and Anatomical and Chemical Researches, connected with the Investigation and Treatment of Disease. Edited by DR. LIONEL S. BEALE, F.R.S. Published Quarterly; Nos. I. to VIII., 3s. 6d.; IX. to XII., 2s. 6d., XIII. to XV., 3s.

ARCHIVES OF DENTISTRY:

Edited by EDWIN TRUMAN. Published Quarterly, price 4s. Nos. I. to IV.

THE YEAR-BOOK OF PHARMACY
AND
CHEMISTS' DESK COMPANION
FOR 1866.

BEING A PRACTICAL SUMMARY OF RESEARCHES
IN PHARMACY, MATERIA MEDICA,
AND PHARMACEUTICAL CHEMISTRY, DURING
THE YEAR 1865.

Edited by CHARLES H. WOOD, F.C.S., and
CHAS. SHARP. Price 2s. 6d.

THE ROYAL LONDON OPHTHALMIC HOSPITAL
REPORTS, AND JOURNAL OF OPHTHALMIC
MEDICINE AND SURGERY.

Vol. V., Part 1, 2s. 6d.

THE MEDICAL TIMES & GAZETTE.

Published Weekly, price Sixpence, or Stamped,
Sevenpence.

Annual Subscription, £1. 6s., or Stamped,
£1. 10s. 4d., and regularly forwarded to all
parts of the Kingdom.

THE HALF-YEARLY ABSTRACT OF
THE MEDICAL SCIENCES.

Being a Digest of the Contents of the principal
British and Continental Medical Works;
together with a Critical Report of the Progress
of Medicine and the Collateral Sciences.
Post 8vo. cloth, 6s. 6d. Vols. I. to XLII.

THE PHARMACEUTICAL JOURNAL,
CONTAINING THE TRANSACTIONS OF THE PHAR-
MACEUTICAL SOCIETY.

Published Monthly, price One Shilling.
** Vols. I. to XXIV., bound in cloth, price
12s. 6d. each.

THE BRITISH JOURNAL OF DENTAL
SCIENCE.

Published Monthly, price One Shilling. Nos.
I. to CXVII.

THE MEDICAL DIRECTORY FOR THE
UNITED KINGDOM.

Published Annually. 8vo. cloth, 10s. 6d.

ANNALS OF MILITARY AND NAVAL
SURGERY AND TROPICAL MEDICINE
AND HYGIENE,

Embracing the experience of the Medical Officers of Her Majesty's Armies and Fleets in all parts of the World.

Vol. I., price 7s.

A CLASSIFIED INDEX

TO

MESSRS. CHURCHILL & SONS' CATALOGUE.

ANATOMY.

Anatomical Remembrancer ..	PAGE	3
Flower on Nerves ..	11	11
Hassall's Micros. Anatomy ..	14	14
Heale's Anatomy of the Lungs ..	14	14
Heath's Practical Anatomy ..	15	15
Holden's Human Osteology ..	15	15
Do. on Dissections ..	15	15
Huxley's Comparative Anatomy ..	16	16
Jones' and Steveking's Patho- logical Anatomy ..	17	17
Maclise's Surgical Anatomy ..	19	19
St. Bartholomew's Hospital Catalogue ..	24	24
Sibson's Medical Anatomy ..	25	25
Waters' Anatomy of Lung ..	29	29
Wheeler's Anatomy for Artists ..	30	30
Wilson's Anatomy ..	31	31

CHEMISTRY.

Abel & Bloxam's Handbook ..	3
Bernays' Notes for Students ..	6
Bowman's Practical Chemistry ..	7
Do. Medical do. ..	7
Fownes' Manual of Chemistry ..	12
Do. Actonian Prize ..	12
Do. Qualitative Analysis ..	12
Freese's Chemical Analysis ..	12
Galloway's First Step ..	12
Do. Second Step ..	12
Do. Analysis ..	12
Do. Tables ..	12
Griffiths' Four Seasons ..	13
Horsley's Chem. Philosophy ..	16
Mulder on the Chemistry of Wine ..	22
Plattner & Musprat on Blowpipe ..	22
Speer's Pathol. Chemistry ..	26
Sutton's Volumetric Analysis ..	27

CLIMATE.

Aspinall on San Remo ..	4
Bennet's Winter in the South of Europe ..	6
Chambers on Italy ..	8
Dalrymple on Egypt ..	8
Francis on Change of Climate ..	10
Hall on Torquay ..	14
Haviland on Climate ..	14
Lee on Climate ..	14
Do. Watering Places of England ..	18
McClelland on Bengal ..	19
McNicoll on Southport ..	19
Martin on Tropical Climates ..	20
Moore's Diseases of India ..	20
Scorsby-Jackson's Climatology ..	24
Shapter on South Devon ..	25
Sjordet on Mentone ..	25
Taylor on Pau and Pyrenees ..	27

DEFORMITIES, &c.

Adams on Spinal Curvature ..	3
Bigg's Orthopraxy ..	6
Bishop on Deformities ..	6
Do. Articulate Sounds ..	6
Brodhurst on Spine ..	7
Do. on Clubfoot ..	7
Godfrey on Spine ..	13
Hugman on Hip Joint ..	16
Templin on Spine ..	27

DISEASES OF WOMEN AND CHILDREN.

Ballard on Infants and Mothers ..	4
Bennet on Uterus ..	6
Do. on Uterine Pathology ..	6
Bird on Children ..	6
Bryant's Surg. Diseases of Child ..	7
Eyre's Practical Remarks ..	11
Harrison on Children ..	14
Wood on Scarlet Fever, &c. ..	16
Kiwisch (ed. by Clay) on Ovaries ..	9
Lee's Ovarian & Uterine Diseases ..	18
Do. on Speculum ..	18
Ritchie on Ovaries ..	23
Seymour on Ovaria ..	25
Smith on Leucorrhœa ..	26
Tilt on Uterine Inflammation ..	28
Do. Uterine Therapeutics ..	28
Do. on Change of Life ..	28
Underwood on Children ..	29
Wells on the Ovaries ..	30
West on Women ..	30
Do. (Uvedale) on Puerp. Diseases ..	30

GENERATIVE ORGANS, Diseases of, and SYPHILIS.

Acton on Reproductive Organs ..	3
Cooté on Syphilis ..	10
Gant on Bladder ..	13
Hutchinson on Inherited Syphilis ..	16
Judd on Syphilis ..	17
Lee on Syphilis ..	18
Parker on Syphilis ..	21
Wilson on Syphilis ..	31

HYGIENE.

Armstrong on Naval Hygiene ..	4
Beale's Laws of Health ..	5
Do. Health and Disease ..	5
Bennet on Nutrition ..	6
Carter on Training ..	8
Chavasse's Advice to a Mother ..	9
Do. Advice to a Wife ..	9
Dobell's Germs and Vestiges of Disease ..	11
Do. Diet and Regimen ..	11
Fife & Urquhart on Turkish Bath ..	11
Granville on Vichy ..	13
Hartwig on Sea Bathing ..	14
Do. Physical Education ..	14
Hufeland's Art of prolonging Life ..	16
Lee's Baths of Germany ..	18
Do. do. Switzerland ..	18
Moore's Health in Tropics ..	20
Parkes on Hygiene ..	21
Parkin on Disease ..	21
Pickford on Hygiene ..	21
Robertson on Diet ..	24
Routh on Infant Feeding ..	23
Tunstall's Bath Waters ..	28
Wells' Seamen's Medicine Chest ..	30
Wife's Domain ..	30
Wilson on Healthy Skin ..	31
Do. on Mineral Waters ..	31
Do. on Turkish Bath ..	31

MATERIA MEDICA and PHARMACY.

Bateman's Magnacopia ..	5
Beasley's Formulary ..	5
Do. Receipt Book ..	5
Do. Book of Prescriptions ..	5
Frazer's Materia Medica ..	12
Nevins' Analysis of Pharmacop. ..	20
Pereira's Selecta & Prescriptis ..	21
Pharmacopœia Londinensis ..	22

MATERIA MEDICA and PHARMACY—continued.

Prescriber's Pharmacopœia ..	PAGE	22
Royle's Materia Medica ..	24	
Squire's Hospital Pharmacopœias ..	26	
Do. Companion to the Pharm- acopœia ..	26	
Steggall's First Lines for Chem- ists and Druggists ..	26	
Stowe's Toxicological Chart ..	27	
Taylor on Poisons ..	27	
Waring's Therapeutics ..	29	
Wittstein's Pharmacy ..	31	

MEDICINE.

Adams on Rheumatic Gout ..	3
Addison on Cell Therapeutics ..	3
Do. on Healthy and Dis- eased Structure ..	3
Aldis's Hospital Practice ..	3
Anderson (Andrew) on Fever ..	4
Do. (Thos.) on Yellow Fevcr ..	4
Austin on Paralysis ..	4
Barclay on Medical Diagnosis ..	4
Barlow's Practice of Medicine ..	4
Basham on Dropsy ..	5
Brinton on Stomach ..	7
Do. on Ulcer of do. ..	7
Budd on the Liver ..	8
Do. on Stomach ..	8
Camplin on Diabetes ..	8
Chambers on Digestion ..	8
Do. Lectures ..	8
Cockle on Cancer ..	9
Davey's Ganglionic Nervous Syst. ..	10
Eyre on Stomach ..	11
French on Cholera ..	12
Fuller on Rheumatism ..	12
Gairdner on Gout ..	12
Gibb on Throat ..	13
Granville on Sudden Death ..	13
Griffith on the Skin ..	13
Gully's Simple Treatment ..	13
Habershon on the Abdomen ..	13
Do. on Mercury ..	13
Hall (Marshall) on Apœcia ..	14
Do. Observations ..	14
Headland—Action of Medicines ..	14
Hooper's Physician's Vade- mecum ..	13
Inman's New Theory ..	16
Do. Myalgia ..	16
James on Laryngoscope ..	17
MacLachlan on Advanced Life ..	19
Macpherson on Cholera ..	19
Marcet on Chronic Alcoholism ..	19
Meryon on Paralysis ..	20
Pavy on Diabetes ..	21
Peet's Principles and Practice of Medicine ..	21
Richardson's Aesclepiad ..	23
Roberts on Palsy ..	23
Robertson on Gout ..	24
Savory's Compendium ..	24
Semple on Cough ..	24
Seymour on Dropsy ..	25
Shaw's Remembrancer ..	25
Snee on Debility ..	25
Thomas' Practice of Physic ..	27
Thudichum on Gall Stones ..	28
Todd's Clinical Lectures ..	28
Tweedie on Continued Fevers ..	29
Walker on Diphtheria ..	29
What to Observe at the Bedside ..	29
Williams' Principles ..	30
Wright on Headaches ..	31

CLASSIFIED INDEX.

MICROSCOPE.

Beale on Microscope in Medicine	5
Carpenter on Microscope	8
Schacht on do.	24

MISCELLANEOUS.

Acton on Prostitution	3
Barclay's Medical Errors	4
Barker & Edwards' Photographs	4
Bascome on Epidemics	5
Blaine's Veterinary Art	7
Bourguignon on the Cattle Plague	7
Bryce on Sebastopol	7
Buckle's Hospital Statistics	7
Cooley's Cyclopædia	9
Gordon on China	13
Graves' Physiology and Medicine	13
Guy's Hospital Reports	13
Harrison on Lead in Water	14
Hingeston's Topics of the Day	15
Howe on Epidemics	16
Lane's Hydropathy	18
Lee on Homœop. and Hydrop.	18
London Hospital Reports	19
Marcet on Food	19
Massy on Recruits	20
Mayne's Medical Vocabulary	20
Part's Case Book	21
Redwood's Supplement to Pharmacopœia	23
Ryan on Infanticide	24
Snow on Chloroform	25
Steggall's Medical Manual	26
Do. Gregory's Conspicuous	26
Do. Celsus	26
Whitehead on Transmission	30

NERVOUS DISORDERS AND INDIGESTION.

Birch on Constipation	6
Carter on Hysteria	8
Downing on Neuralgia	11
Hunt on Heartburn	16
Jones (Handfield) on Functional Nervous Disorders	17
Leared on Imperfect Digestion	18
Lobb on Nervous Affections	19
Radcliffe on Epilepsy	22
Reynolds on the Brain	23
Do. on Epilepsy	23
Rowe on Nervous Diseases	24
Sieveking on Epilepsy	25
Turnbull on Stomach	28

OBSTETRICS.

Barnes on Placenta Prævia	4
Hodges on Puerperal Convulsions	15
Lee's Clinical Midwifery	18
Do. Consultations	18
Leishman's Mechanism of Parturition	18
Mackenzie on Phlegmasia Dolens	19
Pretty's Aids during Labour	22
Priestley on Gravid Uterus	22
Ramsbotham's Obstetrics	23
Do. Midwifery	23
Sinclair & Johnston's Midwifery	25
Smellie's Obstetric Plates	25
Smith's Manual of Obstetrics	26
Swayne's Aphorisms	27
Waller's Midwifery	29

OPHTHALMOLOGY.

Cooper on Injuries of Eye	9
Do. on Near Sight	9
Dalrymple on Eye	10
Dixon on the Eye	10
Hogg on Ophthalmoscope	15
Hulke on the Ophthalmoscope	16
Jacob on Eye-ball	16

OPHTHALMOLOGY—cont^d.

Jago on Entoptics	17
Jones' Ophthalmic Medicine	17
Do. Defects of Sight	17
Do. Eye and Ear	17
Nunneley on the Organs of Vision	21
Solomon on Glaucoma	26
Walton on the Eye	29
Wells on Spectacles	30

PHYSIOLOGY.

Carpenter's Human	8
Do. Manual	8
Heale on Vital Causes	14
O'Reilly on the Nervous System	21
Richardson on Coagulation	23
Shea's Animal Physiology	25
Virchow's (ed. by Chance) Cellular Pathology	8

PSYCHOLOGY.

Arldige on the State of Lunacy	4
Bucknill and Tuke's Psychological Medicine	8
Conolly on Asylums	9
Davey on Nature of Insanity	10
Dunn's Physiological Psychology	11
Hood on Criminal Lunatics	15
Millingen on Treatment of Insane	20
Noble on Mind	21
Sankey on Mental Diseases	24
Williams (J. H.) Unsoundness of Mind	30

PULMONARY and CHEST DISEASES, &c.

Alison on Pulmonary Consumption	3
Billing on Lungs and Heart	6
Bright on the Chest	7
Cotton on Consumption	10
Do. on Stethoscope	10
Davies on Lungs and Heart	10
Dobell on the Chest	10
Do. on Tuberculosis	11
Do. on Winter Cough	11
Fenwick on Consumption	11
Fuller on Chest	12
Do. on Heart	12
Jones (Jas.) on Consumption	17
Laenneec on Auscultation	17
Markham on Heart	20
Peacock on the Heart	21
Richardson on Consumption	23
Salter on Asthma	24
Skoda on Auscultation	20
Thompson on Consumption	27
Timms on Consumption	28
Turnbull on Consumption	28
Waters on Emphysema	29
Weber on Auscultation	29

RENAL and URINARY DISEASES.

Acton on Urinary Organs	3
Beale on Urine	5
Bird's Urinary Deposits	6
Coulson on Bladder	10
Hassall on Urine	14
Parques on Urine	21
Thudichum on Urine	28
Todd on Urinary Organs	28

SCIENCE.

Baxter on Organic Polarity	5
Bentley's Manual of Botany	6
Bird's Natural Philosophy	6
Craig on Electric Tensiou	10
Hardwich's Photography	14
Hinds' Harmonies	15

SCIENCE—continued.

Howard on the Clouds	16
Jones on Vision	17
Do. on Body, Sense, and Mind	17
Mayne's Lexicon	20
Pratt's Genealogy of Creation	22
Do. Eccentric & Centric Force	22
Do. on Orbital Motion	22
Do. Astronomical Investigations	22
Do. Oracles of God	22
Price's Photographie Manipulation	22
Raine on Shells	23
Reymond's Animal Electricity	23
Taylor's Medical Jurisprudence	27
Unger's Botanical Letters	29
Vestiges of Creation	29

SURGERY.

Adams on Reparation of Tendons	3
Do. Subcutaneous Surgery	3
Anderson on the Skin	3
Ashton on Rectum	4
Brodhurst on Anchylosis	7
Bryant on Diseases of Joints	7
Callender on Rupture	8
Chapman on Ulcers	8
Do. Varicose Veins	8
Clark's Outlines of Surgery	9
Collis on Cancer	9
Cooper (Sir A.) on Testis	9
Do. (S.) Surg. Dictionary	9
Coulson on Lithotomy	10
Curling on Rectum	10
Do. on Testis	10
Druitt's Surgeon's Vade-Mecum	11
Ferguson's Surgery	11
Gamgee's Amputation at Hip-joint	12
Gant's Principles of Surgery	13
Heath's Minor Surgery and Bandaging	15
Higginbottom on Nitrate of Silver	15
Hodgson on Prostate	15
Holt on Stricture	15
James on Hernia	17
Jordan's Clinical Surgery	17
Lawrence's Surgery	18
Do. Ruptures	18
Lee on the Rectum, &c.	18
Liston's Surgery	18
Logan on Skin Diseases	19
Macleod's Surgical Diagnosis	19
Do. Surgery of the Crimea	19
Maclise on Fractures	19
Mauder's Operative Surgery	20
Nunneley on Erysipelas	21
Pirrie's Surgery	22
Price on Excision of Knee-joint	22
Salt on Rupture	24
Sansom on Chloroform	24
Smith (Hy.) on Stricture	25
Do. on Hemorrhoids	25
Do. on the Surgery of the Rectum	25
Do. (Dr. J.) Dental Anatomy and Surgery	26
Steggall's Surgical Manual	26
Teale on Amputation	27
Thompson on Stricture	27
Do. on Prostate	27
Do. Lithotomy and Lithotripsy	27
Tomes' Dental Surgery	28
Toumbee on Ear	28
Wade on Stricture	29
Webb's Surgeon's Ready Rules	29
Williamson on Military Surgery	30
Do. on Gunshot Injuries	30
Wilson on Skin Disease	31
Do. Portraits of Skin Diseases	31
Yearsley on Deafness	31
Do. on Throat	31

MR. F. A. ABEL, F.R.S., & MR. C. L. BLOXAM.
**HANDBOOK OF CHEMISTRY: THEORETICAL, PRACTICAL,
 AND TECHNICAL.** Second Edition. 8vo. cloth, 15s.

MR. ACTON, M.R.C.S.

I.
**A PRACTICAL TREATISE ON DISEASES OF THE URINARY
 AND GENERATIVE ORGANS IN BOTH SEXES.** Third Edition. 8vo. cloth,
 £1. 1s. With Plates, £1. 11s. 6d. The Plates alone, limp cloth, 10s. 6d.

II.
**THE FUNCTIONS AND DISORDERS OF THE REPRODUC-
 TIVE ORGANS IN CHILDHOOD, YOUTH, ADULT AGE, AND ADVANCED
 LIFE,** considered in their Physiological, Social, and Moral Relations. Fourth Edition.
 8vo. cloth, 10s. 6d.

III.
PROSTITUTION: Considered in its Moral, Social, and Sanitary Bearings,
 with a View to its Amelioration and Regulation. 8vo. cloth, 10s. 6d.

DR. ADAMS, A.M.

**A TREATISE ON RHEUMATIC GOUT; OR, CHRONIC
 RHEUMATIC ARTHRITIS.** 8vo. cloth, with a Quarto Atlas of Plates, 21s.

MR. WILLIAM ADAMS, F.R.C.S.

I.
**ON THE PATHOLOGY AND TREATMENT OF LATERAL
 AND OTHER FORMS OF CURVATURE OF THE SPINE.** With Plates-
 8vo. cloth, 10s. 6d.

II.
**ON THE REPARATIVE PROCESS IN HUMAN TENDONS
 AFTER SUBCUTANEOUS DIVISION FOR THE CURE OF DEFORMITIES.**
 With Plates. 8vo. cloth, 6s.

III.
**SKETCH OF THE PRINCIPLES AND PRACTICE OF
 SUBCUTANEOUS SURGERY.** 8vo. cloth, 2s. 6d.

DR. WILLIAM ADDISON, F.R.S.

I.
CELL THERAPEUTICS. 8vo. cloth, 4s.

II.
**ON HEALTHY AND DISEASED STRUCTURE, AND THE TRUE
 PRINCIPLES OF TREATMENT FOR THE CURE OF DISEASE, ESPECIALLY CONSUMPTION
 AND SCROFULA,** founded on MICROSCOPICAL ANALYSIS. 8vo. cloth, 12s.

DR. ALDIS.

**AN INTRODUCTION TO HOSPITAL PRACTICE IN VARIOUS
 COMPLAINTS;** with Remarks on their Pathology and Treatment. 8vo. cloth, 5s. 6d.

DR. SOMERVILLE SCOTT ALISON, M.D. EDIN., F.R.C.P.
**THE PHYSICAL EXAMINATION OF THE CHEST IN PUL-
 MONARY CONSUMPTION, AND ITS INTERCURRENT DISEASES.** With
 Engravings. 8vo. cloth, 12s.

**THE ANATOMICAL REMEMBRANCER; OR, COMPLETE
 POCKET ANATOMIST.** Sixth Edition, carefully Revised. 32mo. cloth, 3s. 6d.

DR. MCCALL ANDERSON, M.D.

I.
PARASITIC AFFECTIONS OF THE SKIN. With Engravings.
 8vo. cloth, 5s.

II.
ECZEMA. 8vo. cloth, 5s.

III.
PSORIASIS AND LEPROA. With Chromo-lithograph. 8vo. cloth, 5s.

DR. ANDREW ANDERSON, M.D.

TEN LECTURES INTRODUCTORY TO THE STUDY OF FEVER.
Post 8vo. cloth, 5s.

DR. THOMAS ANDERSON, M.D.

HANDBOOK FOR YELLOW FEVER: ITS PATHOLOGY AND
TREATMENT. To which is added a brief History of Cholera, and a method of Cure.
Fcap. 8vo. cloth, 3s.

DR. ARLIDGE.

ON THE STATE OF LUNACY AND THE LEGAL PROVISION
FOR THE INSANE; with Observations on the Construction and Organisation of
Asylums. 8vo. cloth, 7s.

DR. ALEXANDER ARMSTRONG, R.N.

OBSERVATIONS ON NAVAL HYGIENE AND SCURVY.
More particularly as the latter appeared during a Polar Voyage. 8vo. cloth, 5s.

MR. T. J. ASHTON.

I.
ON THE DISEASES, INJURIES, AND MALFORMATIONS
OF THE RECTUM AND ANUS. Fourth Edition. 8vo. cloth, 8s.

II.

PROLAPSUS, FISTULA IN ANO, AND HÆMORRHOIDAL
AFFECTIONS; their Pathology and Treatment. Second Edition. Post 8vo. cloth, 2s. 6d.

MR. W. B. ASPINALL.

SAN REMO AS A WINTER RESIDENCE. With Coloured Plates.
Foolscap 8vo. cloth, 4s. 6d.

MR. THOS. J. AUSTIN, M.R.C.S.ENG.

A PRACTICAL ACCOUNT OF GENERAL PARALYSIS:
Its Mental and Physical Symptoms, Statistics, Causes, Seat, and Treatment. 8vo. cloth, 6s.

DR. THOMAS BALLARD, M.D.

A NEW AND RATIONAL EXPLANATION OF THE DIS-
EASES PECULIAR TO INFANTS AND MOTHERS; with obvious Suggestions
for their Prevention and Cure. Post 8vo. cloth, 4s. 6d.

DR. BARCLAY.

I.

A MANUAL OF MEDICAL DIAGNOSIS. Second Edition.
Foolscap 8vo. cloth, 8s. 6d.

II.

MEDICAL ERRORS.—Fallacies connected with the Application of the
Inductive Method of Reasoning to the Science of Medicine. Post 8vo. cloth, 5s.

DR. T. HERBERT BARKER, M.D., F.R.S., & MR. ERNEST EDWARDS, B.A.
PHOTOGRAPHS OF EMINENT MEDICAL MEN, with brief
Analytical Notices of their Works. Nos. I. to VI., price 3s. each.

DR. BARLOW.

A MANUAL OF THE PRACTICE OF MEDICINE. Second
Edition. Fcap. 8vo. cloth, 12s. 6d.

DR. BARNES.

THE PHYSIOLOGY AND TREATMENT OF PLACENTA
PRÆVIA; being the Lettsomian Lectures on Midwifery for 1857. Post 8vo. cloth, 6s.

DR. BASCOMB.

A HISTORY OF EPIDEMIC PESTILENCES, FROM THE EARLIEST AGES. 8vo. cloth, 8s.

DR. BASHAM.

ON DROPSY, AND ITS CONNECTION WITH DISEASES OF THE KIDNEYS, HEART, LUNGS AND LIVER. With 16 Plates. Third Edition. 8vo. cloth, 12s. 6d.

MR. H. F. BAXTER, M.R.C.S.L.

ON ORGANIC POLARITY; showing a Connexion to exist between Organic Forces and Ordinary Polar Forces. Crown 8vo. cloth, 5s.

MR. BATEMAN.

MAGNACOPIA: A Practical Library of Profitable Knowledge, communicating the general Minutiæ of Chemical and Pharmaceutic Routine, together with the generality of Secret Forms of Preparations. Third Edition. 18mo. 6s.

MR. LIONEL J. BEALE, M.R.C.S.

I.
THE LAWS OF HEALTH IN THEIR RELATIONS TO MIND AND BODY. A Series of Letters from an Old Practitioner to a Patient. Post 8vo. cloth, 7s. 6d.

II.
HEALTH AND DISEASE, IN CONNECTION WITH THE GENERAL PRINCIPLES OF HYGIENE. Fcap. 8vo., 2s. 6d.

DR. BEALE, F.R.S.

I.
URINE, URINARY DEPOSITS, AND CALCULI: and on the Treatment of Urinary Diseases. Numerous Engravings. Second Edition, much Enlarged. Post 8vo. cloth, 8s. 6d.

II.
THE MICROSCOPE, IN ITS APPLICATION TO PRACTICAL MEDICINE. With a Coloured Plate, and 270 Woodcuts. Second Edition. 8vo. cloth, 14s.

III.
ILLUSTRATIONS OF THE SALTS OF URINE, URINARY DEPOSITS, and CALCULI. 37 Plates, containing upwards of 170 Figures copied from Nature, with descriptive Letterpress. 8vo. cloth, 9s. 6d.

MR. BEASLEY.

I.
THE BOOK OF PRESCRIPTIONS; containing 3000 Prescriptions. Collected from the Practice of the most eminent Physicians and Surgeons, English and Foreign. Third Edition. 18mo. cloth, 6s.

II.
THE DRUGGIST'S GENERAL RECEIPT-BOOK; comprising a copious Veterinary Formulary and Table of Veterinary Materia Medica; Patent and Proprietary Medicines, Druggists' Nostrums, &c.; Perfumery, Skin Cosmetics, Hair Cosmetics, and Teeth Cosmetics; Beverages, Dietetic Articles, and Condiments; Trade Chemicals, Miscellaneous Preparations and Compounds used in the Arts, &c.; with useful Memoranda and Tables. Sixth Edition. 18mo. cloth, 6s.

III.
THE POCKET FORMULARY AND SYNOPSIS OF THE BRITISH AND FOREIGN PHARMACOPŒIAS; comprising standard and approved Formulæ for the Preparations and Compounds employed in Medical Practice. Eighth Edition, corrected and enlarged. 18mo. cloth, 6s.

DR. HENRY BENNET.

I.
A PRACTICAL TREATISE ON INFLAMMATION AND
OTHER DISEASES OF THE UTERUS. Fourth Edition, revised, with Additions.
8vo. cloth, 16s.

II.
A REVIEW OF THE PRESENT STATE OF UTERINE
PATHOLOGY. 8vo. cloth, 4s.

III.
NUTRITION IN HEALTH AND DISEASE. Post 8vo. cloth, 5s.

IV.
WINTER IN THE SOUTH OF EUROPE; OR, MENTONE, THE
RIVIERA, CORSICA, SICILY, AND BIARRITZ, AS WINTER CLIMATES.
Third Edition, with numerous Plates, Maps, and Wood Engravings. Post 8vo. cloth,
10s. 6d.

~~~~~  
PROFESSOR BENTLEY, F.L.S.

A MANUAL OF BOTANY. With nearly 1,200 Engravings on Wood.  
Fcap. 8vo. cloth, 12s. 6d.

~~~~~  
DR. BERNAYS.

NOTES FOR STUDENTS IN CHEMISTRY; being a Syllabus com-
piled from the Manuals of Miller, Fownes, Berzelius, Gerhardt, Goup-Besanez, &c.
Fourth Edition. Fcap. 8vo. cloth, 3s.

~~~~~  
MR. HENRY HEATHER BIGG.

ORTHOPRAXY: the Mechanical Treatment of Deformities, Debilities, and  
Deficiencies of the Human Frame. With Engravings. Post 8vo. cloth, 10s.

~~~~~  
DR. BILLING, F.R.S.

ON DISEASES OF THE LUNGS AND HEART. 8vo. cloth, 6s.

~~~~~  
DR. S. B. BIRCH, M.D.

CONSTIPATED BOWELS: the Various Causes and the Rational Means  
of Cure. Second Edition. Post 8vo. cloth, 3s. 6d.

~~~~~  
DR. GOLDING BIRD, F.R.S.

I.
URINARY DEPOSITS; THEIR DIAGNOSIS, PATHOLOGY,
AND THERAPEUTICAL INDICATIONS. With Engravings. Fifth Edition.
Edited by E. LLOYD BIRKETT, M.D. Post 8vo. cloth, 10s. 6d.

II.
ELEMENTS OF NATURAL PHILOSOPHY; being an Experimental
Introduction to the Study of the Physical Sciences. With numerous Engravings. Fifth
Edition. Edited by CHARLES BROOKE, M.B. Cantab., F.R.S. Fcap. 8vo. cloth,
12s. 6d.

~~~~~  
MR. BISHOP, F.R.S.

I.  
ON DEFORMITIES OF THE HUMAN BODY, their Pathology  
and Treatment. With Engravings on Wood. 8vo. cloth, 10s.

II.  
ON ARTICULATE SOUNDS, AND ON THE CAUSES AND  
CURE OF IMPEDIMENTS OF SPEECH. 8vo. cloth, 4s.

~~~~~  
MR. P. HINCKES BIRD, F.R.C.S.

PRACTICAL TREATISE ON THE DISEASES OF CHILDREN
AND INFANTS AT THE BREAST. Translated from the French of M. BOUCHUT,
with Notes and Additions. 8vo. cloth. 20s.

MR. BLAINE.

OUTLINES OF THE VETERINARY ART; OR, A TREATISE
ON THE ANATOMY, PHYSIOLOGY, AND DISEASES OF THE HORSE,
NEAT CATTLE, AND SHEEP. Seventh Edition. By Charles Steel, M.R.C.V.S.L.
With Plates. 8vo. cloth, 18s.

DR. BOURGUIGNON.

ON THE CATTLE PLAGUE; OR, CONTAGIOUS TYPHUS IN
HORNED CATTLE: its History, Origin, Description, and Treatment. Post 8vo. 5s.

MR. JOHN E. BOWMAN, & MR. C. L. BLOXAM.

I.

PRACTICAL CHEMISTRY, including Analysis. With numerous Illus-
trations on Wood. Fifth Edition. Foolscep 8vo. cloth, 6s. 6d.

II.

MEDICAL CHEMISTRY; with Illustrations on Wood. Fourth Edition,
carefully revised. Fcap. 8vo. cloth, 6s. 6d.

DR. JAMES BRIGHT.

ON DISEASES OF THE HEART, LUNGS, & AIR PASSAGES;
with a Review of the several Climates recommended in these Affections. Third Edi-
tion. Post 8vo. cloth, 9s.

DR. BRINTON, F.R.S.

I.

THE DISEASES OF THE STOMACH, with an Introduction on its
Anatomy and Physiology; being Lectures delivered at St. Thomas's Hospital. Second
Edition. 8vo. cloth, 10s. 6d.

II.

THE SYMPTOMS, PATHOLOGY, AND TREATMENT OF
ULCER OF THE STOMACH. Post 8vo. cloth, 5s.

MR. BERNARD E. BRODHURST, F.R.C.S.

I.

CURVATURES OF THE SPINE: their Causes, Symptoms, Pathology,
and Treatment. Second Edition. Roy. 8vo. cloth, with Engravings, 7s. 6d.

II.

ON THE NATURE AND TREATMENT OF CLUBFOOT AND
ANALOGOUS DISTORTIONS involving the TIBIO-TARSAL ARTICULATION.
With Engravings on Wood. 8vo. cloth, 4s. 6d.

III.

PRACTICAL OBSERVATIONS ON THE DISEASES OF THE
JOINTS INVOLVING ANCHYLOSIS, and on the TREATMENT for the
RESTORATION of MOTION. Third Edition, much enlarged, 8vo. cloth, 4s. 6d.

MR. THOMAS BRYANT, F.R.C.S.

I.

ON THE DISEASES AND INJURIES OF THE JOINTS.
CLINICAL AND PATHOLOGICAL OBSERVATIONS. Post 8vo. cloth, 7s. 6d.

II.

THE SURGICAL DISEASES OF CHILDREN. The Lettsomian
Lectures, delivered March, 1863. Post 8vo. cloth, 5s.

DR. BRYCE.

ENGLAND AND FRANCE BEFORE SEBASTOPOL, looked at
from a Medical Point of View. 8vo. cloth, 6s.

DR. BUCKLE, M.D., L.R.C.P.LOND.

VITAL AND ECONOMICAL STATISTICS OF THE HOSPITALS,
INFIRMARIES, &c., OF ENGLAND AND WALES. Royal 8vo. 5s.

DR. BUDD, F.R.S.

I.
ON DISEASES OF THE LIVER.

Illustrated with Coloured Plates and Engravings on Wood. Third Edition. 8vo. cloth, 16s.

II.
ON THE ORGANIC DISEASES AND FUNCTIONAL DIS-
ORDERS OF THE STOMACH. 8vo. cloth, 9s.

DR. JOHN CHARLES BUCKNILL, & DR. DANIEL H. TUKE.

A MANUAL OF PSYCHOLOGICAL MEDICINE: containing
the History, Nosology, Description, Statistics, Diagnosis, Pathology, and Treatment of
Insanity. Second Edition. 8vo. cloth, 15s.

MR. CALLENDER, F.R.C.S.

FEMORAL RUPTURE: Anatomy of the Parts concerned. With Plates.
8vo. cloth, 4s.

DR. JOHN M. CAMPLIN, F.L.S.

ON DIABETES, AND ITS SUCCESSFUL TREATMENT.
Third Edition, by Dr. Glover. Fcap. 8vo. cloth, 3s. 6d.

MR. ROBERT B. CARTER, M.R.C.S.

I.
ON THE INFLUENCE OF EDUCATION AND TRAINING
IN PREVENTING DISEASES OF THE NERVOUS SYSTEM. Fcap. 8vo., 6s.II.
THE PATHOLOGY AND TREATMENT OF HYSTERIA. Post
8vo. cloth, 4s. 6d.

DR. CARPENTER, F.R.S.

I.
PRINCIPLES OF HUMAN PHYSIOLOGY. With numerous Illus-
trations on Steel and Wood. Sixth Edition. Edited by Mr. HENRY POWER. 8vo.
cloth, 26s.II.
A MANUAL OF PHYSIOLOGY. With 252 Illustrations on Steel
and Wood. Fourth Edition. Fcap. 8vo. cloth, 12s. 6d.III.
THE MICROSCOPE AND ITS REVELATIONS. With nume-
rous Engravings on Steel and Wood. Third Edition. Fcap. 8vo. cloth, 12s. 6d.

DR. CHAMBERS.

I.
LECTURES, CHIEFLY CLINICAL. Fourth Edition. 8vo. cloth, 14s.II.
DIGESTION AND ITS DERANGEMENTS. Post 8vo. cloth, 10s. 6d.III.
SOME OF THE EFFECTS OF THE CLIMATE OF ITALY.
Crown 8vo. cloth, 4s. 6d.

DR. CHANCE, M.B.

VIRCHOW'S CELLULAR PATHOLOGY, AS BASED UPON
PHYSIOLOGICAL AND PATHOLOGICAL HISTOLOGY. With 144 Engrav-
ings on Wood. 8vo. cloth, 16s.

MR. H. T. CHAPMAN, F.R.C.S.

I.
THE TREATMENT OF OBSTINATE ULCERS AND CUTA-
NEOUS ERUPTIONS OF THE LEG WITHOUT CONFINEMENT. Third
Edition. Post 8vo. cloth, 3s. 6d.II.
VARICOSE VEINS: their Nature, Consequences, and Treatment, Pallia-
tive and Curative. Second Edition. Post 8vo. cloth, 3s. 6d.

MR. PYE HENRY CHAVASSE, F.R.C.S.

I.
ADVICE TO A MOTHER ON THE MANAGEMENT OF
HER CHILDREN. Eighth Edition. Foolscap 8vo., 2s. 6d.

II.
ADVICE TO A WIFE ON THE MANAGEMENT OF HER
OWN HEALTH. With an Introductory Chapter, especially addressed to a Young
Wife. Seventh Edition. Fcap. 8vo., 2s. 6d.

MR. LE GROS CLARK, F.R.C.S.

OUTLINES OF SURGERY; being an Epitome of the Lectures on the
Principles and the Practice of Surgery, delivered at St. Thomas's Hospital. Fcap. 8vo.
cloth, 5s.

MR. JOHN CLAY, M.R.C.S.

KIWISCH ON DISEASES OF THE OVARIES: Translated, by
permission, from the last German Edition of his Clinical Lectures on the Special Patho-
logy and Treatment of the Diseases of Women. With Notes, and an Appendix on the
Operation of Ovariectomy. Royal 12mo. cloth, 16s.

DR. COCKLE, M.D.

ON INTRA-THORACIC CANCER. 8vo. 6s. 6d.

MR. COLLIS, M.B.DUB., F.R.C.S.I.

THE DIAGNOSIS AND TREATMENT OF CANCER AND
THE TUMOURS ANALOGOUS TO IT. With coloured Plates. 8vo. cloth, 14s.

DR. CONOLLY.

THE CONSTRUCTION AND GOVERNMENT OF LUNATIC
ASYLUMS AND HOSPITALS FOR THE INSANE. With Plans. Post 8vo.
cloth, 6s.

MR. COOLEY.

COMPREHENSIVE SUPPLEMENT TO THE PHARMACOPŒIAS.

THE CYCLOPŒDIA OF PRACTICAL RECEIPTS, PRO-
CESSES, AND COLLATERAL INFORMATION IN THE ARTS, MANU-
FACTURES, PROFESSIONS, AND TRADES, INCLUDING MEDICINE,
PHARMACY, AND DOMESTIC ECONOMY; designed as a General Book of
Reference for the Manufacturer, Tradesman, Amateur, and Heads of Families. Fourth
and greatly enlarged Edition, 8vo. cloth, 28s.

MR. W. WHITE COOPER.

I.
ON WOUNDS AND INJURIES OF THE EYE. Illustrated by
17 Coloured Figures and 41 Woodcuts. 8vo. cloth, 12s.

II.
ON NEAR SIGHT, AGED SIGHT, IMPAIRED VISION,
AND THE MEANS OF ASSISTING SIGHT. With 31 Illustrations on Wood.
Second Edition. Fcap. 8vo. cloth, 7s. 6d.

SIR ASTLEY COOPER, BART., F.R.S.

ON THE STRUCTURE AND DISEASES OF THE TESTIS.
With 24 Plates. Second Edition. Royal 4to., 20s.

MR. COOPER.

A DICTIONARY OF PRACTICAL SURGERY AND ENCYCLO-
PŒDIA OF SURGICAL SCIENCE. New Edition, brought down to the present
time. By SAMUEL A. LANE, F.R.C.S., assisted by various eminent Surgeons. Vol. I.,
8vo. cloth, £1. 5s.

MR. HOLMES COOTE, F.R.C.S.

A REPORT ON SOME IMPORTANT POINTS IN THE
TREATMENT OF SYPHILIS. 8vo. cloth, 5s.

DR. COTTON.

I.
ON CONSUMPTION: Its Nature, Symptoms, and Treatment. To
which Essay was awarded the Fothergillian Gold Medal of the Medical Society of
London. Second Edition. 8vo. cloth, 8s.

II.
PHTHISIS AND THE STETHOSCOPE; OR, THE PHYSICAL
SIGNS OF CONSUMPTION. Third Edition. Foolscep 8vo. cloth, 3s.

MR. COULSON.

I.
ON DISEASES OF THE BLADDER AND PROSTATE GLAND.
New Edition, revised. *In Preparation.*

II.
ON LITHOTRITY AND LITHOTOMY; with Engravings on Wood.
8vo. cloth, 8s.

MR. WILLIAM CRAIG, L.F.P.S., GLASGOW.

ON THE INFLUENCE OF VARIATIONS OF ELECTRIC
TENSION AS THE REMOTE CAUSE OF EPIDEMIC AND OTHER
DISEASES. 8vo. cloth, 10s.

MR. CURLING, F.R.S.

I.
OBSERVATIONS ON DISEASES OF THE RECTUM. Third
Edition. 8vo. cloth, 7s. 6d.

II.
A PRACTICAL TREATISE ON DISEASES OF THE TESTIS,
SPERMATIC CORD, AND SCROTUM. Third Edition, with Engravings. 8vo.
cloth, 16s.

DR. DALRYMPLE, M.R.C.P., F.R.C.S.

THE CLIMATE OF EGYPT: METEOROLOGICAL AND MEDI-
CAL OBSERVATIONS, with Practical Hints for Invalid Travellers. Post 8vo. cloth, 4s.

MR. JOHN DALRYMPLE, F.R.S., F.R.C.S.

PATHOLOGY OF THE HUMAN EYE. Complete in Nine Fasciculi:
imperial 4to., 20s. each; half-bound morocco, gilt tops, 9l. 15s.

DR. HERBERT DAVIES.

ON THE PHYSICAL DIAGNOSIS OF DISEASES OF THE
LUNGS AND HEART. Second Edition. Post 8vo. cloth, 8s.

DR. DAVEY.

I.
THE GANGLIONIC NERVOUS SYSTEM: its Structure, Functions,
and Diseases. 8vo. cloth, 9s.

II.
ON THE NATURE AND PROXIMATE CAUSE OF IN-
SANITY. Post 8vo. cloth, 3s.

MR. DIXON.

A GUIDE TO THE PRACTICAL STUDY OF DISEASES OF
THE EYE. Third Edition. Post 8vo. cloth, 9s.

DR. DOBELL.

I.
DEMONSTRATIONS OF DISEASES IN THE CHEST, AND
THEIR PHYSICAL DIAGNOSIS. With Coloured Plates. 8vo. cloth, 12s. 6d.

II.
LECTURES ON THE GERMS AND VESTIGES OF DISEASE,
and on the Prevention of the Invasion and Fatality of Disease by Periodical Examinations.
8vo. cloth, 6s. 6d.

III.
A MANUAL OF DIET AND REGIMEN FOR PHYSICIAN
AND PATIENT. Third Edition (for the year 1865). Crown 8vo. cloth, 1s. 6d.

IV.
ON TUBERCULOSIS: ITS NATURE, CAUSE, AND TREAT-
MENT; with Notes on Pancreatic Juice. Second Edition. Crown 8vo. cloth, 3s. 6d.

V.
ON WINTER COUGH (CATARRH, BRONCHITIS, EMPHY-
SEMA, ASTHMA); with an Appendix on some Principles of Diet in Disease—
Lectures delivered at the Royal Infirmary for Diseases of the Chest. Post 8vo. cloth,
5s. 6d.

DR. TOOGOOD DOWNING.

NEURALGIA: its various Forms, Pathology, and Treatment. THE
JACKSONIAN PRIZE ESSAY FOR 1850. 8vo. cloth, 10s. 6d.

DR. DRUITT, F.R.C.S.

THE SURGEON'S VADE-MECUM; with numerous Engravings on
Wood. Ninth Edition. Foolscap 8vo. cloth, 12s. 6d.

MR. DUNN, F.R.C.S.

AN ESSAY ON PHYSIOLOGICAL PSYCHOLOGY. 8vo. cloth, 4s.

SIR JAMES EYRE, M.D.

I.
THE STOMACH AND ITS DIFFICULTIES. Fifth Edition.
Fcap. 8vo. cloth, 2s. 6d.

II.
PRACTICAL REMARKS ON SOME EXHAUSTING DIS-
EASES. Second Edition. Post 8vo. cloth, 4s. 6d.

DR. FENWICK.

ON SCROFULA AND CONSUMPTION. Clergyman's Sore Throat,
Catarrh, Croup, Bronchitis, Asthma. Fcap. 8vo., 2s. 6d.

SIR WILLIAM FERGUSSON, BART., F.R.S.

A SYSTEM OF PRACTICAL SURGERY; with numerous Illus-
trations on Wood. Fourth Edition. Fcap. 8vo. cloth, 12s. 6d.

SIR JOHN FIFE, F.R.C.S. AND MR. URQUHART.

MANUAL OF THE TURKISH BATH. Heat a Mode of Cure and
a Source of Strength for Men and Animals. With Engravings. Post 8vo. cloth, 5s.

MR. FLOWER, F.R.C.S.

DIAGRAMS OF THE NERVES OF THE HUMAN BODY,
exhibiting their Origin, Divisions, and Connexions, with their Distribution to the various
Regions of the Cutaneous Surface, and to all the Muscles. Folio, containing Six
Plates, 14s.

MR. FOWNES, PH.D., F.R.S.

I.
A MANUAL OF CHEMISTRY; with 187 Illustrations on Wood.
Ninth Edition. Fcap. 8vo. cloth, 12s. 6d.

Edited by H. BENGE JONES, M.D., F.R.S., and A. W. HOFMANN, PH.D., F.R.S.

II.
CHEMISTRY, AS EXEMPLIFYING THE WISDOM AND
BENEFICENCE OF GOD. Second Edition. Fcap. 8vo. cloth, 4s. 6d.

III.
INTRODUCTION TO QUALITATIVE ANALYSIS. Post 8vo. cloth, 2s.

DR. D. J. T. FRANCIS.

CHANGE OF CLIMATE; considered as a Remedy in Dyspeptic, Pul-
monary, and other Chronic Affections; with an Account of the most Eligible Places of
Residence for Invalids, at different Seasons of the Year. Post 8vo. cloth, 8s. 6d.

DR. W. FRAZER.

ELEMENTS OF MATERIA MEDICA; containing the Chemistry
and Natural History of Drugs—their Effects, Doses, and Adulterations. Second Edition.
8vo. cloth, 10s. 6d.

MR. J. G. FRENCH, F.R.C.S.

THE NATURE OF CHOLERA INVESTIGATED. Second
Edition. 8vo. cloth, 4s.

C. REMIGIUS FRESENIUS.

A SYSTEM OF INSTRUCTION IN CHEMICAL ANALYSIS,
Edited by LLOYD BULLOCK, F.C.S.

QUALITATIVE. Sixth Edition, with Coloured Plate illustrating Spectrum Analysis. 8vo.
cloth, 10s. 6d.—QUANTITATIVE. Fourth Edition. 8vo. cloth, 18s.

DR. FULLER.

I.
ON DISEASES OF THE CHEST, including Diseases of the Heart
and Great Vessels. With Engravings. 8vo. cloth, 12s. 6d.

II.
ON DISEASES OF THE HEART AND GREAT VESSELS.
8vo. cloth, 7s. 6d.

III.
ON RHEUMATISM, RHEUMATIC GOUT, AND SCIATICA:
their Pathology, Symptoms, and Treatment. Third Edition. 8vo. cloth, 12s. 6d.

DR. GAIRDNER.

ON GOUT; its History, its Causes, and its Cure. Fourth Edition. Post
8vo. cloth, 8s. 6d.

MR. GALLOWAY.

I.
THE FIRST STEP IN CHEMISTRY. Third Edition. Fcap. 8vo.
cloth, 5s.

II.
THE SECOND STEP IN CHEMISTRY; or, the Student's Guide to
the Higher Branches of the Science. With Engravings. 8vo. cloth, 10s.

III.
A MANUAL OF QUALITATIVE ANALYSIS. Fourth Edition.
Post 8vo. cloth, 6s. 6d.

IV.
CHEMICAL TABLES. On Five Large Sheets, for School and Lecture
Rooms. Second Edition. 4s. 6d.

MR. J. SAMPSON GAMGEE.

HISTORY OF A SUCCESSFUL CASE OF AMPUTATION AT
THE HIP-JOINT (the limb 48-in. in circumference, 99 pounds weight). With 4
Photographs. 4to cloth, 10s. 6d.

MR. F. J. GANT, F.R.C.S.

I.

THE PRINCIPLES OF SURGERY: Clinical, Medical, and Operative. With Engravings. 8vo. cloth, 18s.

II.

THE IRRITABLE BLADDER: its Causes and Curative Treatment. Post 8vo. cloth, 4s. 6d.

DR. GIBB, M.R.C.P.

ON DISEASES OF THE THROAT AND WINDPIPE, as reflected by the Laryngoscope. Second Edition. With 116 Engravings. Post 8vo. cloth, 10s. 6d.

MRS. GODFREY.

ON THE NATURE, PREVENTION, TREATMENT, AND CURE OF SPINAL CURVATURES and DEFORMITIES of the CHEST and LIMBS, without ARTIFICIAL SUPPORTS or any MECHANICAL APPLIANCES. Third Edition, Revised and Enlarged. 8vo. cloth, 5s.

DR. GORDON, M.D., C.B.

CHINA, FROM A MEDICAL POINT OF VIEW, IN 1860 AND 1861; With a Chapter on Nagasaki as a Sanatorium. With Plans. 8vo. cloth, 10s. 6d.

DR. GRANVILLE, F.R.S.

I.

THE MINERAL SPRINGS OF VICHY: their Efficacy in the Treatment of Gout, Indigestion, Gravel, &c. 8vo. cloth, 3s.

II.

ON SUDDEN DEATH. Post 8vo., 2s. 6d.

DR. GRAVES, M.D., F.R.S.

STUDIES IN PHYSIOLOGY AND MEDICINE. Edited by Dr. Stokes. With Portrait and Memoir. 8vo. cloth, 14s.

DR. S. C. GRIFFITH, M.D.

ON DERMATOLOGY AND THE TREATMENT OF SKIN DISEASES BY MEANS OF HERBS, IN PLACE OF ARSENIC AND MERCURY. Fcap. 8vo. cloth, 3s.

MR. GRIFFITHS.

CHEMISTRY OF THE FOUR SEASONS—Spring, Summer, Autumn, Winter. Illustrated with Engravings on Wood. Second Edition. Foolscap 8vo. cloth, 7s. 6d.

DR. GULLY.

THE SIMPLE TREATMENT OF DISEASE; deduced from the Methods of Expectancy and Revulsion. 18mo. cloth, 4s.

DR. GUY AND DR. JOHN HARLEY.

HOOPER'S PHYSICIAN'S VADE-MECUM; OR, MANUAL OF THE PRINCIPLES AND PRACTICE OF PHYSIC. Seventh Edition, considerably enlarged, and rewritten. Foolscap 8vo. cloth, 12s. 6d.

GUY'S HOSPITAL REPORTS. Third Series. Vols. I. to XI., 8vo., 7s. 6d. each.

DR. HABERSHON, F.R.C.P.

I.

PATHOLOGICAL AND PRACTICAL OBSERVATIONS ON DISEASES OF THE ABDOMEN, comprising those of the Stomach and other Parts of the Alimentary Canal, Oesophagus, Stomach, Cæcum, Intestines, and Peritoneum. Second Edition, with Plates. 8vo. cloth, 14s.

II.

ON THE INJURIOUS EFFECTS OF MERCURY IN THE TREATMENT OF DISEASE. Post 8vo. cloth, 3s. 6d.

DR. C. RADCLYFFE HALL.

TORQUAY IN ITS MEDICAL ASPECT AS A RESORT FOR
PULMONARY INVALIDS. Post 8vo. cloth, 5s.

DR. MARSHALL HALL, F.R.S.

I.
PRONE AND POSTURAL RESPIRATION IN DROWNING
AND OTHER FORMS OF APNŒA OR SUSPENDED RESPIRATION.
Post 8vo. cloth, 5s.

II.
PRACTICAL OBSERVATIONS AND SUGGESTIONS IN MEDI-
CINE. *Second Series.* Post 8vo. cloth, 8s. 6d.

MR. HARDWICH.

A MANUAL OF PHOTOGRAPHIC CHEMISTRY. With
Engravings. Seventh Edition. Foolsap 8vo. cloth, 7s. 6d.

DR. J. BOWER HARRISON, M.D., M.R.C.P.

I.
LETTERS TO A YOUNG PRACTITIONER ON THE DIS-
EASES OF CHILDREN. Foolsap 8vo. cloth, 3s.

II.
ON THE CONTAMINATION OF WATER BY THE POISON
OF LEAD, and its Effects on the Human Body. Foolsap 8vo. cloth, 3s. 6d.

DR. HARTWIG.

I.
ON SEA BATHING AND SEA AIR. Second Edition. Fcap.
8vo., 2s. 6d.

II.
ON THE PHYSICAL EDUCATION OF CHILDREN. Fcap.
8vo., 2s. 6d.

DR. A. H. HASSALL.

I.
THE URINE, IN HEALTH AND DISEASE; being an Ex-
planation of the Composition of the Urine, and of the Pathology and Treatment of
Urinary and Renal Disorders. Second Edition. With 79 Engravings (23 Coloured).
Post 8vo. cloth, 12s. 6d.

II.
THE MICROSCOPIC ANATOMY OF THE HUMAN BODY,
IN HEALTH AND DISEASE. Illustrated with Several Hundred Drawings in
Colour. Two vols. 8vo. cloth, £1. 10s.

MR. ALFRED HAVILAND, M.R.C.S.

CLIMATE, WEATHER, AND DISEASE; being a Sketch of the
Opinions of the most celebrated Ancient and Modern Writers with regard to the Influence
of Climate and Weather in producing Disease. With Four coloured Engravings. 8vo.
cloth, 7s.

DR. HEADLAND.

ON THE ACTION OF MEDICINES IN THE SYSTEM.
Being the Prize Essay to which the Medical Society of London awarded the Fother-
gillian Gold Medal for 1852. Third Edition. 8vo. cloth, 12s. 6d.

DR. HEALE.

I.
A TREATISE ON THE PHYSIOLOGICAL ANATOMY OF
THE LUNGS. With Engravings. 8vo. cloth, 8s.

II.
A TREATISE ON VITAL CAUSES. 8vo. cloth, 9s.

MR. CHRISTOPHER HEATH, F.R.C.S.

I.

PRACTICAL ANATOMY: a Manual of Dissections. With numerous Engravings. Fcap. 8vo. cloth, 10s. 6d.

II.

A MANUAL OF MINOR SURGERY AND BANDAGING, FOR THE USE OF HOUSE-SURGEONS, DRESSERS, AND JUNIOR PRACTITIONERS. With Illustrations. Third Edition. Fcap. 8vo. cloth, 5s.

MR. HIGGINBOTTOM, F.R.S., F.R.C.S.E.

A PRACTICAL ESSAY ON THE USE OF THE NITRATE OF SILVER IN THE TREATMENT OF INFLAMMATION, WOUNDS, AND ULCERS. Third Edition, 8vo. cloth, 6s.

DR. HINDS.

THE HARMONIES OF PHYSICAL SCIENCE IN RELATION TO THE HIGHER SENTIMENTS; with Observations on Medical Studies, and on the Moral and Scientific Relations of Medical Life. Post 8vo. cloth, 4s.

MR. J. A. HINGESTON, M.R.C.S.

TOPICS OF THE DAY, MEDICAL, SOCIAL, AND SCIENTIFIC. Crown 8vo. cloth, 7s. 6d.

DR. HODGES.

THE NATURE, PATHOLOGY, AND TREATMENT OF PUERPERAL CONVULSIONS. Crown 8vo. cloth, 3s.

DR. DECIMUS HODGSON.

THE PROSTATE GLAND, AND ITS ENLARGEMENT IN OLD AGE. With 12 Plates. Royal 8vo. cloth, 6s.

MR. JABEZ HOGG.

A MANUAL OF OPHTHALMOSCOPIC SURGERY; being a Practical Treatise on the Use of the Ophthalmoscope in Diseases of the Eye. Third Edition. With Coloured Plates. 8vo. cloth, 10s. 6d.

MR. LUTHER HOLDEN, F.R.C.S.

I.

HUMAN OSTEOLOGY: with Plates, showing the Attachments of the Muscles. Third Edition. 8vo. cloth, 16s.

II.

A MANUAL OF THE DISSECTION OF THE HUMAN BODY. With Engravings on Wood. Second Edition. 8vo. cloth, 16s.

MR BARNARD HOLT, F.R.C.S.

ON THE IMMEDIATE TREATMENT OF STRICTURE OF THE URETHRA. Second Edition, Enlarged. 8vo. cloth, 3s.

DR. W. CHARLES HOOD.

SUGGESTIONS FOR THE FUTURE PROVISION OF CRIMINAL LUNATICS. 8vo. cloth, 5s. 6d.

DR. P. HOOD.

THE SUCCESSFUL TREATMENT OF SCARLET FEVER;
also, OBSERVATIONS ON THE PATHOLOGY AND TREATMENT OF
CROWING INSPIRATIONS OF INFANTS. Post 8vo. cloth, 5s.

MR. JOHN HORSLEY.

A CATECHISM OF CHEMICAL PHILOSOPHY; being a Familiar
Exposition of the Principles of Chemistry and Physics. With Engravings on Wood.
Designed for the Use of Schools and Private Teachers. Post 8vo. cloth, 6s. 6d.

MR. LUKE HOWARD, F.R.S.

ESSAY ON THE MODIFICATIONS OF CLOUDS. Third Edition,
by W. D. and E. HOWARD. With 6 Lithographic Plates, from Pictures by Kenyon.
4to. cloth, 10s. 6d.

DR. HAMILTON HOWE, M.D.

**A THEORETICAL INQUIRY INTO THE PHYSICAL CAUSE
OF EPIDEMIC DISEASES.** Accompanied with Tables. 8vo. cloth, 7s.

DR. HUFELAND.

THE ART OF PROLONGING LIFE. Second Edition. Edited
by ERASMUS WILSON, F.R.S. Foolscap 8vo., 2s. 6d.

MR. W. CURTIS HUGMAN, F.R.C.S.

ON HIP-JOINT DISEASE; with reference especially to Treatment
by Mechanical Means for the Relief of Contraction and Deformity of the Affected Limb.
With Plates. Re-issue, enlarged. 8vo. cloth, 3s. 6d.

MR. HULKE, F.R.C.S.

**A PRACTICAL TREATISE ON THE USE OF THE
OPHTHALMOSCOPE.** Being the Jacksonian Prize Essay for 1859. Royal 8vo.
cloth, 8s.

DR. HENRY HUNT.

ON HEARTBURN AND INDIGESTION. 8vo. cloth, 5s.

PROFESSOR HUXLEY, F.R.S.

**LECTURES ON THE ELEMENTS OF COMPARATIVE
ANATOMY.—ON CLASSIFICATION AND THE SKULL.** With III Illus-
trations. 8vo. cloth, 10s. 6d.

MR. JONATHAN HUTCHINSON, F.R.C.S.

**A CLINICAL MEMOIR ON CERTAIN DISEASES OF THE
EYE AND EAR, CONSEQUENT ON INHERITED SYPHILIS;** with an
appended Chapter of Commentaries on the Transmission of Syphilis from Parent to
Offspring, and its more remote Consequences. With Plates and Woodcuts, 8vo. cloth, 9s.

DR. INMAN, M.R.C.P.

I.

ON MYALGIA: ITS NATURE, CAUSES, AND TREATMENT;
being a Treatise on Painful and other Affections of the Muscular System. Second
Edition. 8vo. cloth, 9s.

II.

**FOUNDATION FOR A NEW THEORY AND PRACTICE
OF MEDICINE.** Second Edition. Crown 8vo. cloth, 10s.

DR. ARTHUR JACOB, F.R.C.S.

A TREATISE ON THE INFLAMMATIONS OF THE EYE-BALL.
Foolscap 8vo. cloth, 5s.

DR. JAGO, M.D. OXON., A.B. CANTAB.

ENTOPTICS, WITH ITS USES IN PHYSIOLOGY AND
MEDICINE. With 54 Engravings. Crown 8vo. cloth, 5s.

MR. J. H. JAMES, F.R.C.S.

PRACTICAL OBSERVATIONS ON THE OPERATIONS FOR
STRANGULATED HERNIA. 8vo. cloth, 5s.

DR. PROSSER JAMES, M.D.

SORE-THROAT: ITS NATURE, VARIETIES, AND TREAT-
MENT; including the Use of the LARYNGOSCOPE as an Aid to Diagnosis. Post
8vo. cloth, 4s. 6d.

DR. HANDFIELD JONES, M.B., F.R.C.P.

CLINICAL OBSERVATIONS ON FUNCTIONAL NERVOUS
DISORDERS. Post 8vo. cloth, 10s. 6d.

DR. HANDFIELD JONES, F.R.S., & DR. EDWARD H. SIEVEKING.

A MANUAL OF PATHOLOGICAL ANATOMY. Illustrated with
numerous Engravings on Wood. Foolscap 8vo. cloth, 12s. 6d.

DR. JAMES JONES, M.D., M.R.C.P.

ON THE USE OF PERCHLORIDE OF IRON AND OTHER
CHALYBEATE SALTS IN THE TREATMENT OF CONSUMPTION. Crown
8vo. cloth, 3s. 6d.

MR. WHARTON JONES, F.R.S.

A MANUAL OF THE PRINCIPLES AND PRACTICE OF
OPHTHALMIC MEDICINE AND SURGERY; with Nine Coloured Plates and
173 Wood Engravings. Third Edition, thoroughly revised. Foolscap 8vo. cloth, 12s. 6d.

THE WISDOM AND BENEFICENCE OF THE ALMIGHTY,
AS DISPLAYED IN THE SENSE OF VISION; being the Actonian Prize Essay
for 1851. With Illustrations on Steel and Wood. Foolscap 8vo. cloth, 4s. 6d.

DEFECTS OF SIGHT: their Nature, Causes, Prevention, and General
Management. Second Edition. Fcap. 8vo. 2s. 6d.

A CATECHISM OF THE MEDICINE AND SURGERY OF
THE EYE AND EAR. For the Clinical Use of Hospital Students. Fcap. 8vo. 2s. 6d.

A CATECHISM OF THE PHYSIOLOGY AND PHILOSOPHY
OF BODY, SENSE, AND MIND. For Use in Schools and Colleges. Fcap. 8vo.,
2s. 6d.

MR. FURNEAUX JORDAN, M.R.C.S.

AN INTRODUCTION TO CLINICAL SURGERY; WITH A
Method of Investigating and Reporting Surgical Cases. Fcap. 8vo. cloth, 5s.

MR. JUDD.

A PRACTICAL TREATISE ON URETHRITIS AND SYPHI-
LIS: including Observations on the Power of the Menstruous Fluid, and of the Dis-
charge from Leucorrhœa and Sores to produce Urethritis: with a variety of Examples,
Experiments, Remedies, and Cures. 8vo. cloth, £1. 5s.

DR. LAENNEC.

A MANUAL OF AUSCULTATION AND PERCUSSION. Trans-
lated and Edited by J. B. SHARPE, M.R.C.S. 3s.

DR. LANE, M.A.

HYDROPATHY; OR, HYGIENIC MEDICINE. An Explanatory
Essay. Second Edition. Post 8vo. cloth, 5s.

MR. LAWRENCE, F.R.S.

I.
LECTURES ON SURGERY. 8vo. cloth, 16s.

II.
A TREATISE ON RUPTURES. The Fifth Edition, considerably
enlarged. 8vo. cloth, 16s.

DR. LEARED, M.R.C.P.

IMPERFECT DIGESTION: ITS CAUSES AND TREATMENT.
Fourth Edition. Foolscap 8vo. cloth, 4s.

DR. EDWIN LEE.

I.
THE EFFECT OF CLIMATE ON TUBERCULOUS DISEASE,
with Notices of the chief Foreign Places of Winter Resort. Small 8vo. cloth, 4s. 6d.

II.
THE WATERING PLACES OF ENGLAND, CONSIDERED
with Reference to their Medical Topography. Fourth Edition. Fcap. 8vo. cloth, 7s. 6d.

III.
THE BATHS OF GERMANY. Fourth Edition. Post 8vo. cloth, 7s.

IV.
THE BATHS OF SWITZERLAND. 12mo. cloth, 3s. 6d.

V.
**HOMŒOPATHY AND HYDROPATHY IMPARTIALLY AP-
PRECIATED.** With Notes illustrative of the Influence of the Mind over the Body.
Fourth Edition. Post 8vo. cloth, 3s. 6d.

MR. HENRY LEE, F.R.C.S.

I.
ON SYPHILIS. Second Edition. With Coloured Plates. 8vo. cloth, 10s.

II.
**ON DISEASES OF THE VEINS, HÆMORRHOIDAL TUMOURS,
AND OTHER AFFECTIONS OF THE RECTUM.** Second Edition. 8vo. cloth, 8s.

DR. ROBERT LEE, F.R.S.

I.
CONSULTATIONS IN MIDWIFERY. Foolscap 8vo. cloth, 4s. 6d.

II.
A TREATISE ON THE SPECULUM; with Three Hundred Cases.
8vo. cloth, 4s. 6d.

III.
**CLINICAL REPORTS OF OVARIAN AND UTERINE DIS-
EASES,** with Commentaries. Foolscap 8vo. cloth, 6s. 6d.

IV.
CLINICAL MIDWIFERY: comprising the Histories of 545 Cases of
Difficult, Preternatural, and Complicated Labour, with Commentaries. Second Edition.
Foolscap 8vo. cloth, 5s.

DR. LEISHMAN, M.D., F.F.P.S.

THE MECHANISM OF PARTURITION: An Essay, Historical and
Critical. With Engravings. 8vo. cloth, 5s.

MR. LISTON, F.R.S.

PRACTICAL SURGERY. Fourth Edition. 8vo. cloth, 22s.

MR. H. W. LOBB, L.S.A., M.R.C.S.E.

ON SOME OF THE MORE OBSCURE FORMS OF NERVOUS AFFECTIONS, THEIR PATHOLOGY AND TREATMENT. Re-issue, with the Chapter on Galvanism entirely Re-written. With Engravings. 8vo. cloth, 8s.

DR. LOGAN, M.D., M.R.C.P.LOND.

ON OBSTINATE DISEASES OF THE SKIN. Foolscap 8vo. cloth, 2s. 6d.

LONDON HOSPITAL.

CLINICAL LECTURES AND REPORTS BY THE MEDICAL AND SURGICAL STAFF. With Illustrations. Vols. I. and II. 8vo. cloth, 7s. 6d.

LONDON MEDICAL SOCIETY OF OBSERVATION.

WHAT TO OBSERVE AT THE BED-SIDE, AND AFTER DEATH. Published by Authority. Second Edition. Foolscap 8vo. cloth, 4s. 6d.

DR. MACKENZIE, M.D., M.R.C.P.

THE PATHOLOGY AND TREATMENT OF PHLEGMASIA DOLENS, as deduced from Clinical and Physiological Researches. Lettsomian Lectures on Midwifery. 8vo. cloth, 6s.

MR. M'CLELLAND, F.L.S., F.G.S.

THE MEDICAL TOPOGRAPHY, OR CLIMATE AND SOILS, OF BENGAL AND THE N. W. PROVINCES. Post 8vo. cloth, 4s. 6d.

DR. MACLACHLAN, M.D., F.R.C.P.L.

THE DISEASES AND INFIRMITIES OF ADVANCED LIFE. 8vo. cloth, 16s.

DR. GEORGE H. B. MACLEOD, F.R.C.S.E.

I.

OUTLINES OF SURGICAL DIAGNOSIS. 8vo. cloth, 12s. 6d.

II.

NOTES ON THE SURGERY OF THE CRIMEAN WAR; with REMARKS on GUN-SHOT WOUNDS. 8vo. cloth, 10s. 6d.

MR. JOSEPH MACLISE, F.R.C.S.

I.

SURGICAL ANATOMY. A Series of Dissections, illustrating the Principal Regions of the Human Body. The Second Edition, imperial folio, cloth, £3. 12s.; half-morocco, £4. 4s.

II.

ON DISLOCATIONS AND FRACTURES. This Work is Uniform with the Author's "Surgical Anatomy;" each Fasciculus contains Four beautifully executed Lithographic Drawings. Imperial folio, cloth, £2. 10s.; half-morocco, £2. 17s.

DR. MONICOLL, M.R.C.P.

A HAND-BOOK FOR SOUTHPORT, MEDICAL & GENERAL; with Copious Notices of the Natural History of the District. Second Edition. Post 8vo. cloth, 3s. 6d.

DR. J. MACPHERSON, M.D.

CHOLERA IN ITS HOME; with a Sketch of the Pathology and Treatment of the Disease. Crown 8vo. cloth, 5s.

DR. MARCET, F.R.S.

I.

ON THE COMPOSITION OF FOOD, AND HOW IT IS ADULTERATED; with Practical Directions for its Analysis. 8vo. cloth, 6s. 6d.

II.

ON CHRONIC ALCOHOLIC INTOXICATION; with an INQUIRY INTO THE INFLUENCE OF THE ABUSE OF ALCOHOL AS A PREDISPOSING CAUSE OF DISEASE. Second Edition, much enlarged. Foolscap 8vo. cloth, 4s. 6d.

DR. MARKHAM.

I.
DISEASES OF THE HEART: THEIR PATHOLOGY, DIAGNOSIS, AND TREATMENT. Second Edition. Post 8vo. cloth, 6s.

II.

SKODA ON AUSCULTATION AND PERCUSSION. Post 8vo. cloth, 6s.

SIR RANALD MARTIN, K.C.B., F.R.S.

INFLUENCE OF TROPICAL CLIMATES IN PRODUCING THE ACUTE ENDEMIC DISEASES OF EUROPEANS; including Practical Observations on their Chronic Sequelæ under the Influences of the Climate of Europe. Second Edition, much enlarged. 8vo. cloth, 20s.

DR. MASSY.

ON THE EXAMINATION OF RECRUITS; intended for the Use of Young Medical Officers on Entering the Army. 8vo. cloth, 5s.

MR. O. F. MAUNDER, F.R.C.S.

OPERATIVE SURGERY. With 158 Engravings. Post 8vo. 6s.

DR. MAYNE.

I.
AN EXPOSITORY LEXICON OF THE TERMS, ANCIENT AND MODERN, IN MEDICAL AND GENERAL SCIENCE, including a complete MEDICAL AND MEDICO-LEGAL VOCABULARY. Complete in 10 Parts, price 5s. each. The entire work, cloth, £2. 10s.

II.

A MEDICAL VOCABULARY; or, an Explanation of all Names, Synonymes, Terms, and Phrases used in Medicine and the relative branches of Medical Science, intended specially as a Book of Reference for the Young Student. Second Edition. Fcap. 8vo. cloth, 8s. 6d.

DR. MERYON, M.D., F.R.C.P.

PATHOLOGICAL AND PRACTICAL RESEARCHES ON THE VARIOUS FORMS OF PARALYSIS. 8vo. cloth, 6s.

DR. MILLINGEN.

ON THE TREATMENT AND MANAGEMENT OF THE INSANE; with Considerations on Public and Private Lunatic Asylums. 18mo. cloth, 4s. 6d.

DR. W. J. MOORE, M.D.

I.
HEALTH IN THE TROPICS; or, Sanitary Art applied to Europeans in India. 8vo. cloth, 9s.

II.

A MANUAL OF THE DISEASES OF INDIA. Fcap. 8vo. cloth, 5s.

PROFESSOR MULDER, UTRECHT.

THE CHEMISTRY OF WINE. Edited by H. BENCE JONES, M.D., F.R.S. Fcap. 8vo. cloth, 6s.

DR. BIRKBECK NEVINS.

THE PRESCRIBER'S ANALYSIS OF THE BRITISH PHARMACOPEIA. Third Edition, enlarged to 295 pp. 32mo. cloth, 3s. 6d.

DR. NOBLE.
**THE HUMAN MIND IN ITS RELATIONS WITH THE
 BRAIN AND NERVOUS SYSTEM.** Post 8vo. cloth, 4s. 6d.

MR. NUNNELEY, F.R.C.S.E.

I.
**ON THE ORGANS OF VISION; THEIR ANATOMY AND PHY-
 SIOLOGY.** With Plates, 8vo. cloth, 15s.

II.
**A TREATISE ON THE NATURE, CAUSES, AND TREATMENT
 OF ERYSIPELAS.** 8vo. cloth, 10s. 6d.

DR. O'REILLY.
**THE PLACENTA, THE ORGANIC NERVOUS SYSTEM,
 THE BLOOD, THE OXYGEN, AND THE ANIMAL NERVOUS SYSTEM,
 PHYSIOLOGICALLY EXAMINED.** With Engravings. 8vo. cloth, 5s.

MR. LANGSTON PARKER.

THE MODERN TREATMENT OF SYPHILITIC DISEASES,
 both Primary and Secondary; comprising the Treatment of Constitutional and Confirmed
 Syphilis, by a safe and successful Method. Fourth Edition, 8vo. cloth, 10s.

DR. PARKES, F.R.S., F.R.C.P.

I.
A MANUAL OF PRACTICAL HYGIENE; intended especially for
 the Medical Officers of the Army. With Plates and Woodcuts. 2nd Edition, 8vo. cloth, 16s.

II.
**THE URINE: ITS COMPOSITION IN HEALTH AND DISEASE,
 AND UNDER THE ACTION OF REMEDIES.** 8vo. cloth, 12s.

DR. PARKIN, M.D., F.R.C.S.

THE CAUSATION AND PREVENTION OF DISEASE; with
 the Laws regulating the Extrication of Malaria from the Surface, and its Diffusion in the
 surrounding Air. 8vo. cloth, 5s.

MR. JAMES PART, F.R.C.S.

THE MEDICAL AND SURGICAL POCKET CASE BOOK,
 for the Registration of important Cases in Private Practice, and to assist the Student of
 Hospital Practice. Second Edition. 2s. 6d.

DR. PAVY, M.D., F.R.S., F.R.C.P.

**DIABETES: RESEARCHES ON ITS NATURE AND TREAT-
 MENT.** 8vo. cloth, 8s. 6d.

DR. PEACOCK, M.D., F.R.C.P.

**ON SOME OF THE CAUSES AND EFFECTS OF VALVULAR
 DISEASE OF THE HEART.** With Engravings. 8vo. cloth, 5s.

DR. PEET, M.D., F.R.C.P.

THE PRINCIPLES AND PRACTICE OF MEDICINE;
 Designed chiefly for Students of Indian Medical Colleges. 8vo. cloth, 16s.

DR. PEREIRA, F.R.S.

SELECTA E PRÆSCRIPTIS. Fourteenth Edition. 24mo. cloth, 5s.

DR. PICKFORD.

HYGIENE; or, Health as Depending upon the Conditions of the Atmo-
 sphere, Food and Drinks, Motion and Rest, Sleep and Wakefulness, Secretions, Excre-
 tions, and Retentions, Mental Emotions, Clothing, Bathing, &c. Vol. I. 8vo. cloth, 9s.

MR. PIRRIE, F.R.S.E.
THE PRINCIPLES AND PRACTICE OF SURGERY. With
 numerous Engravings on Wood. Second Edition. 8vo. cloth, 24s.

**PHARMACOPŒIA COLLEGII REGALIS MEDICORUM LON-
 DINENSIS.** 8vo. cloth, 9s.; or 24mo. 5s.

IMPRIMATUR.

Hic liber, cui titulus, PHARMACOPŒIA COLLEGII REGALIS MEDICORUM LONDINENSIS.
 Datum ex Ædibus Collegii in comitiis censoriis, Novembris Mensis 14^{to} 1850.

JOHANNES AYRTON PARIS. *Præses.*

PROFESSORS PLATTNER & MUSPRATT.
**THE USE OF THE BLOWPIPE IN THE EXAMINATION OF
 MINERALS, ORES, AND OTHER METALLIC COMBINATIONS.** Illustrated
 by numerous Engravings on Wood. Third Edition. 8vo. cloth, 10s. 6d.

DR. HENRY F. A. PRATT, M.D., M.R.C.P.

I.
THE GENEALOGY OF CREATION, newly Translated from the
 Unpointed Hebrew Text of the Book of Genesis, showing the General Scientific Accuracy
 of the Cosmogony of Moses and the Philosophy of Creation. 8vo. cloth, 14s.

II.
**ON ECCENTRIC AND CENTRIC FORCE: A New Theory of
 Projection.** With Engravings. 8vo. cloth, 10s.

III.
**ON ORBITAL MOTION: The Outlines of a System of Physical
 Astronomy.** With Diagrams. 8vo. cloth, 7s. 6d.

IV.
ASTRONOMICAL INVESTIGATIONS. The Cosmical Relations of
 the Revolution of the Lunar Apesides. Oceanic Tides. With Engravings. 8vo. cloth, 5s.

V.
THE ORACLES OF GOD: An Attempt at a Re-interpretation. Part I.
 The Revealed Cosmos. 8vo. cloth, 10s.

THE PRESCRIBER'S PHARMACOPŒIA; containing all the Medi-
 cines in the British Pharmacopœia, arranged in Classes according to their Action, with
 their Composition and Doses. By a Practising Physician. Fifth Edition. 32mo.
 cloth, 2s. 6d.; roan tuck (for the pocket), 3s. 6d.

DR. JOHN ROWLISON PRETTY.
AIDS DURING LABOUR, including the Administration of Chloroform,
 the Management of Placenta and Post-partum Hæmorrhage. Fcap. 8vo. cloth, 4s. 6d.

MR. LAKE PRICE.
**PHOTOGRAPHIC MANIPULATION: Treating of the Practice of
 the Art, and its various appliances to Nature.** With Fifty Engravings on Wood. Post
 8vo. cloth, 6s. 6d.

MR. P. C. PRICE, F.R.C.S.
AN ESSAY ON EXCISION OF THE KNEE-JOINT. With
 Coloured Plates. With Memoir of the Author and Notes by Henry Smith, F.R.C.S.
 Royal 8vo. cloth, 14s.

DR. PRIESTLEY.
**LECTURES ON THE DEVELOPMENT OF THE GRAVID
 UTERUS.** 8vo. cloth, 5s. 6d.

DR. RADCLIFFE, F.R.C.P.L.
**LECTURES ON EPILEPSY, PAIN, PARALYSIS, AND
 CERTAIN OTHER DISORDERS OF THE NERVOUS SYSTEM,** delivered at
 the Royal College of Physicians in London. Post 8vo. cloth, 7s. 6d.

MR. RAINEY.

ON THE MODE OF FORMATION OF SHELLS OF ANIMALS, OF BONE, AND OF SEVERAL OTHER STRUCTURES, by a Process of Molecular Coalescence, Demonstrable in certain Artificially-formed Products. Fcap. 8vo. cloth, 4s. 6d.

DR. F. H. RAMSBOTHAM.

THE PRINCIPLES AND PRACTICE OF OBSTETRIC MEDICINE AND SURGERY. Illustrated with One Hundred and Twenty Plates on Steel and Wood; forming one thick handsome volume. Fourth Edition. 8vo. cloth, 22s.

DR. RAMSBOTHAM.

PRACTICAL OBSERVATIONS ON MIDWIFERY, with a Selection of Cases. Second Edition. 8vo. cloth, 12s.

PROFESSOR REDWOOD, PH. D.

A SUPPLEMENT TO THE PHARMACOPŒIA: A concise but comprehensive Dispensatory, and Manual of Facts and Formulæ, for the use of Practitioners in Medicine and Pharmacy. Third Edition. 8vo. cloth, 22s.

DR. DU BOIS REYMOND.

ANIMAL ELECTRICITY; Edited by H. BENGE JONES, M.D., F.R.S. With Fifty Engravings on Wood. Foolscap 8vo. cloth, 6s.

DR. REYNOLDS, M.D. LOND.

I.

EPILEPSY: ITS SYMPTOMS, TREATMENT, AND RELATION TO OTHER CHRONIC CONVULSIVE DISEASES. 8vo. cloth, 10s.

II.

THE DIAGNOSIS OF DISEASES OF THE BRAIN, SPINAL CORD, AND THEIR APPENDAGES. 8vo. cloth, 8s.

DR. B. W. RICHARDSON.

I.

ON THE CAUSE OF THE COAGULATION OF THE BLOOD. Being the ASTLEY COOPER PRIZE ESSAY for 1856. With a Practical Appendix. 8vo. cloth, 16s.

II.

THE HYGIENIC TREATMENT OF PULMONARY CONSUMPTION. 8vo. cloth, 5s. 6d.

III.

THE ASCLEPIAD. Vol. I., Clinical Essays. 8vo. cloth, 6s. 6d.

DR. RITCHIE, M.D.

ON OVARIAN PHYSIOLOGY AND PATHOLOGY. With Engravings. 8vo. cloth, 6s.

DR. WILLIAM ROBERTS, M.D., F.R.C.P.

AN ESSAY ON WASTING PALSY; being a Systematic Treatise on the Disease hitherto described as ATROPHIE MUSCULAIRE PROGRESSIVE. With Four Plates. 8vo. cloth, 5s.

DR. ROUTH.

INFANT FEEDING, AND ITS INFLUENCE ON LIFE; Or, the Causes and Prevention of Infant Mortality. Second Edition. Fcap. 8vo. cloth, 6s.

DR. W. H. ROBERTSON.

I.
THE NATURE AND TREATMENT OF GOUT. 8vo. cloth, 10s. 6d.II.
A TREATISE ON DIET AND REGIMEN. Fourth Edition. 2 vols.
12s. post 8vo. cloth.

DR. ROWE.

NERVOUS DISEASES, LIVER AND STOMACH COMPLAINTS, LOW SPIRITS, INDIGESTION, GOUT, ASTHMA, AND DISORDERS PRODUCED BY TROPICAL CLIMATES. With Cases. Sixteenth Edition. Fcap. 8vo. 2s. 6d.

DR. ROYLE, F.R.S., AND DR. HEADLAND, M.D.

A MANUAL OF MATERIA MEDICA AND THERAPEUTICS.
With numerous Engravings on Wood. Fourth Edition. Fcap. 8vo. cloth, 12s. 6d.

DR. RYAN, M.D.

INFANTICIDE: ITS LAW, PREVALENCE, PREVENTION, AND HISTORY. 8vo. cloth, 5s.

ST. BARTHOLOMEW'S HOSPITAL

A DESCRIPTIVE CATALOGUE OF THE ANATOMICAL MUSEUM. Vol. I. (1846), Vol. II. (1851), Vol. III. (1862), 8vo. cloth, 5s. each.

MR. T. P. SALT, BIRMINGHAM.

A PRACTICAL TREATISE ON RUPTURE: ITS CAUSES, MANAGEMENT, AND CURE. And the various Mechanical Contrivances employed for its Relief. With Engravings. Post 8vo. cloth, 3s.

DR. SALTER, F.R.S.

ON ASTHMA: its Pathology, Causes, Consequences, and Treatment. 8vo. cloth, 10s.

DR. SANKEY, M.D. LOND.

LECTURES ON MENTAL DISEASES. 8vo. cloth, 8s.

DR. SANSOM, M.B. LOND.

CHLOROFORM: ITS ACTION AND ADMINISTRATION. A Handbook. With Engravings. Crown 8vo. cloth, 5s.

MR. SAVORY.

A COMPENDIUM OF DOMESTIC MEDICINE, AND COMPANION TO THE MEDICINE CHEST; intended as a Source of Easy Reference for Clergymen, and for Families residing at a Distance from Professional Assistance. Seventh Edition. 12mo. cloth, 5s.

DR. SCHACHT.

THE MICROSCOPE, AND ITS APPLICATION TO VEGETABLE ANATOMY AND PHYSIOLOGY. Edited by FREDERICK CURREY, M.A. Fcap. 8vo. cloth, 6s.

DR. SCORESBY-JACKSON, M.D., F.R.S.E.

MEDICAL CLIMATOLOGY; or, a Topographical and Meteorological Description of the Localities resorted to in Winter and Summer by Invalids of various classes both at Home and Abroad. With an Isothermal Chart. Post 8vo. cloth, 12s.

DR. SEMPLE.

ON COUGH: its Causes, Varieties, and Treatment. With some practical Remarks on the Use of the Stethoscope as an aid to Diagnosis. Post 8vo. cloth, 4s. 6d.

DR. SEYMOUR.

I.

ILLUSTRATIONS OF SOME OF THE PRINCIPAL DISEASES OF THE OVARIA: their Symptoms and Treatment; to which are prefixed Observations on the Structure and Functions of those parts in the Human Being and in Animals. With 14 folio plates, 12s.

II.

THE NATURE AND TREATMENT OF DROPSY; considered especially in reference to the Diseases of the Internal Organs of the Body, which most commonly produce it. 8vo. 5s.

DR. SHAPTER, M.D., F.R.C.P.

THE CLIMATE OF THE SOUTH OF DEVON, AND ITS INFLUENCE UPON HEALTH. Second Edition, with Maps. 8vo. cloth, 10s. 6d.

MR. SHAW, M.R.C.S.

THE MEDICAL REMEMBRANCER; OR, BOOK OF EMERGENCIES: in which are concisely pointed out the Immediate Remedies to be adopted in the First Moments of Danger from Drowning, Poisoning, Apoplexy, Burns, and other Accidents; with the Tests for the Principal Poisons, and other useful Information. Fourth Edition. Edited, with Additions, by JONATHAN HUTCHINSON, F.R.C.S. 32mo. cloth, 2s. 6d.

DR. SHEA, M.D., B.A.

A MANUAL OF ANIMAL PHYSIOLOGY. With an Appendix of Questions for the B.A. London and other Examinations. With Engravings. Foolschap 8vo. cloth, 5s. 6d.

DR. SIBSON, F.R.S.

MEDICAL ANATOMY. With coloured Plates. Imperial folio. Fasciculi I. to VI. 5s. each.

DR. E. H. SIEVEKING.

ON EPILEPSY AND EPILEPTIFORM SEIZURES: their Causes, Pathology, and Treatment. Second Edition. Post 8vo. cloth, 10s. 6d.

MR. SINCLAIR AND DR. JOHNSTON.

PRACTICAL MIDWIFERY: Comprising an Account of 13,748 Deliveries, which occurred in the Dublin Lying-in Hospital, during a period of Seven Years. 8vo. cloth, 15s.

DR. SIORDET, M.B.LOND., M.R.C.P.

MENTONE IN ITS MEDICAL ASPECT. Foolschap 8vo. cloth, 2s. 6d.

MR. ALFRED SMEE, F.R.S.

GENERAL DEBILITY AND DEFECTIVE NUTRITION; their Causes, Consequences, and Treatment. Second Edition. Fcap. 8vo. cloth, 3s. 6d.

DR. SMELLIE.

OBSTETRIC PLATES: being a Selection from the more Important and Practical Illustrations contained in the Original Work. With Anatomical and Practical Directions. 8vo. cloth, 5s.

MR. HENRY SMITH, F.R.C.S.

I.

ON STRICTURE OF THE URETHRA. 8vo. cloth, 7s. 6d.

II.

HÆMORRHOIDS AND PROLAPSUS OF THE RECTUM: Their Pathology and Treatment, with especial reference to the use of Nitric Acid. Third Edition. Fcap. 8vo. cloth, 3s.

III.

THE SURGERY OF THE RECTUM. Lettsomian Lectures. Fcap. 8vo. 2s. 6d.

DR. J. SMITH, M.D., F.R.C.S. EDIN.

HANDBOOK OF DENTAL ANATOMY AND SURGERY, FOR
THE USE OF STUDENTS AND PRACTITIONERS. Fcap. 3vo. cloth, 3s. 6d.

DR. W. TYLER SMITH.

I.
A MANUAL OF OBSTETRICS, THEORETICAL AND PRACTICAL. Illustrated with 186 Engravings. Fcap. 8vo. cloth, 12s. 6d.

II.
THE PATHOLOGY AND TREATMENT OF LEUCORRŒA.
With Engravings on Wood. 8vo. cloth, 7s.

DR. SNOW.

ON CHLOROFORM AND OTHER ANÆSTHETICS: THEIR
ACTION AND ADMINISTRATION. Edited, with a Memoir of the Author, by
Benjamin W. Richardson, M.D. 8vo. cloth, 10s. 6d.

MR. J. VOSE SOLOMON, F.R.C.S.

TENSION OF THE EYEBALL; GLAUCOMA: some Account of
the Operations practised in the 19th Century. 8vo. cloth, 4s.

DR. STANHOPE TEMPLEMAN SPEER.

PATHOLOGICAL CHEMISTRY, IN ITS APPLICATION TO
THE PRACTICE OF MEDICINE. Translated from the French of MM. BECQUEREL
and RODIER. 8vo. cloth, reduced to 8s.

MR. PETER SQUIRE.

I.
A COMPANION TO THE BRITISH PHARMACOPŒIA.
Third Edition. 8vo. cloth, 8s. 6d.

II.
THE PHARMACOPŒIAS OF THIRTEEN OF THE LONDON
HOSPITALS, arranged in Groups for easy Reference and Comparison. 18mo. cloth,
3s. 6d.

DR. STEGGALL.

STUDENTS' BOOKS FOR EXAMINATION.

I.
A MEDICAL MANUAL FOR APOTHECARIES' HALL AND OTHER MEDICAL
BOARDS. Twelfth Edition. 12mo. cloth, 10s.

II.
A MANUAL FOR THE COLLEGE OF SURGEONS; intended for the Use
of Candidates for Examination and Practitioners. Second Edition. 12mo. cloth, 10s.

III.
GREGORY'S CONSPECTUS MEDICINÆ THEORETICÆ. The First Part, con-
taining the Original Text, with an Ordo Verborum, and Literal Translation. 12mo.
cloth, 10s.

IV.
THE FIRST FOUR BOOKS OF CELSUS; containing the Text, Ordo Verb-
orum, and Translation. Second Edition. 12mo. cloth, 8s.

V.
FIRST LINES FOR CHEMISTS AND DRUGGISTS PREPARING FOR EX-
AMINATION AT THE PHARMACEUTICAL SOCIETY. Second Edition.
18mo. cloth, 3s. 6d.

MR. STOWE, M.R.C.S.

A TOXICOLOGICAL CHART, exhibiting at one view the Symptoms, Treatment, and Mode of Detecting the various Poisons, Mineral, Vegetable, and Animal. To which are added, concise Directions for the Treatment of Suspended Animation. Twelfth Edition, revised. On Sheet, 2s.; mounted on Roller, 5s.

MR. FRANCIS SUTTON, F.C.S.

A SYSTEMATIC HANDBOOK OF VOLUMETRIC ANALYSIS; or, the Quantitative Estimation of Chemical Substances by Measure. With Engravings. Post 8vo. cloth, 7s. 6d.

DR. SWAYNE.

OBSTETRIC APHORISMS FOR THE USE OF STUDENTS COMMENCING MIDWIFERY PRACTICE. With Engravings on Wood. Third Edition. Fcap. 8vo. cloth, 3s. 6d.

MR. TAMPLIN, F.R.C.S.E.

LATERAL CURVATURE OF THE SPINE: its Causes, Nature, and Treatment. 8vo. cloth, 4s.

DR. ALEXANDER TAYLOR, F.R.S.E.

THE CLIMATE OF PAU; with a Description of the Watering Places of the Pyrenees, and of the Virtues of their respective Mineral Sources in Disease. Third Edition. Post 8vo. cloth, 7s.

DR. ALFRED S. TAYLOR, F.R.S.

I.
THE PRINCIPLES AND PRACTICE OF MEDICAL JURISPRUDENCE. With 176 Wood Engravings. 8vo. cloth, 28s.

II.

A MANUAL OF MEDICAL JURISPRUDENCE. Eighth Edition. With Engravings. Fcap. 8vo. cloth, 12s. 6d.

III.

ON POISONS, in relation to MEDICAL JURISPRUDENCE AND MEDICINE. Second Edition. Fcap. 8vo. cloth, 12s. 6d.

MR. TEALE.

ON AMPUTATION BY A LONG AND A SHORT RECTANGULAR FLAP. With Engravings on Wood. 8vo. cloth, 5s.

DR. THEOPHILUS THOMPSON, F.R.S.

CLINICAL LECTURES ON PULMONARY CONSUMPTION; with additional Chapters by E. SYMES THOMPSON, M.D. With Plates. 8vo. cloth, 7s. 6d.

DR. THOMAS.

THE MODERN PRACTICE OF PHYSIC; exhibiting the Symptoms, Causes, Morbid Appearances, and Treatment of the Diseases of all Climates. Eleventh Edition. Revised by ALGERNON FRAMPTON, M.D. 2 vols. 8vo. cloth, 28s.

MR. HENRY THOMPSON, F.R.C.S.

I.

STRICTURE OF THE URETHRA; its Pathology and Treatment. The Jacksonian Prize Essay for 1852. With Plates. Second Edition. 8vo. cloth, 10s.

II.

THE DISEASES OF THE PROSTATE; their Pathology and Treatment. Comprising a Dissertation "On the Healthy and Morbid Anatomy of the Prostate Gland;" being the Jacksonian Prize Essay for 1860. With Plates. Second Edition. 8vo. cloth, 10s.

III.

PRACTICAL LITHOTOMY AND LITHOTRITY; or, An Inquiry into the best Modes of removing Stone from the Bladder. With numerous Engravings, 8vo. cloth, 9s.

DR. THUDICHUM.

I.
A TREATISE ON THE PATHOLOGY OF THE URINE,
Including a complete Guide to its Analysis. With Plates, 8vo. cloth, 14s.

II.
A TREATISE ON GALL STONES: their Chemistry, Pathology,
and Treatment. With Coloured Plates. 8vo. cloth, 10s.

DR. TILT.

I.
ON UTERINE AND OVARIAN INFLAMMATION, AND ON
THE PHYSIOLOGY AND DISEASES OF MENSTRUATION. Third Edition.
8vo. cloth, 12s.

II.
A HANDBOOK OF UTERINE THERAPEUTICS, AND OF
MODERN PATHOLOGY OF DISEASES OF WOMEN. Second Edition.
Post 8vo. cloth, 6s.

III.
THE CHANGE OF LIFE IN HEALTH AND DISEASE: a
Practical Treatise on the Nervous and other Affections incidental to Women at the Decline
of Life. Second Edition. 8vo. cloth, 6s.

DR. GODWIN TIMMS.

CONSUMPTION: its True Nature and Successful Treatment. Crown
8vo. cloth, 10s.

DR. ROBERT B. TODD, F.R.S.

I.
CLINICAL LECTURES ON THE PRACTICE OF MEDICINE.
New Edition, in one Volume, Edited by DR. BEALE, 8vo. cloth, 18s.

II.
ON CERTAIN DISEASES OF THE URINARY ORGANS, AND
ON DROPSIES. Fcap. 8vo. cloth, 6s.

MR. TOMES, F.R.S.

A MANUAL OF DENTAL SURGERY. With 208 Engravings on
Wood. Fcap. 8vo. cloth, 12s. 6d.

MR. JOSEPH TOYNBEE, F.R.S., F.R.C.S.

THE DISEASES OF THE EAR: THEIR NATURE, DIAG-
NOSIS, AND TREATMENT. Illustrated with numerous Engravings on Wood.
8vo. cloth, 15s.

DR. TUNSTALL, M.D., M.R.C.P.

THE BATH WATERS: their Uses and Effects in the Cure and Relief
of various Chronic Diseases. Third Edition. 8vo. cloth, 2s. 6d.

DR. TURNBULL.

I.
AN INQUIRY INTO THE CURABILITY OF CONSUMPTION,
ITS PREVENTION, AND THE PROGRESS OF IMPROVEMENT IN THE
TREATMENT. Third Edition. 8vo. cloth, 6s.

II.
A PRACTICAL TREATISE ON DISORDERS OF THE STOMACH
with FERMENTATION; and on the Causes and Treatment of Indigestion, &c. 8vo.
cloth, 6s.

DR. TWEEDIE, F.R.S.

CONTINUED FEVERS: THEIR DISTINCTIVE CHARACTERS,
PATHOLOGY, AND TREATMENT. With Coloured Plates. 8vo. cloth, 12s.

VESTIGES OF THE NATURAL HISTORY OF CREATION.

Eleventh Edition. Illustrated with 106 Engravings on Wood. 8vo. cloth, 7s. 6d.

DR. UNDERWOOD.

TREATISE ON THE DISEASES OF CHILDREN. Tenth Edition,
with Additions and Corrections by HENRY DAVIES, M.D. 8vo. cloth, 15s.

DR. UNGER.

BOTANICAL LETTERS. Translated by Dr. B. PAUL. Numerous
Woodcuts. Post 8vo., 2s. 6d.

MR. WADE, F.R.C.S.

STRICTURE OF THE URETHRA, ITS COMPLICATIONS
AND EFFECTS; a Practical Treatise on the Nature and Treatment of those
Affections. Fourth Edition. 8vo. cloth, 7s. 6d.

DR. WALKER, M.B.LOND.

ON DIPHTHERIA AND DIPHTHERITIC DISEASES. Fcap.
8vo. cloth, 3s.

DR. WALLER.

ELEMENTS OF PRACTICAL MIDWIFERY; or, Companion to
the Lying-in Room. Fourth Edition, with Plates. Fcap. cloth, 4s. 6d.

MR. HAYNES WALTON, F.R.C.S.

SURGICAL DISEASES OF THE EYE. With Engravings on
Wood. Second Edition. 8vo. cloth, 14s.

DR. WARING, M.D., F.L.S.

A MANUAL OF PRACTICAL THERAPEUTICS. Second Edition,
Revised and Enlarged. Fcap. 8vo. cloth, 12s. 6d.

DR. WATERS, M.R.C.P.

I.
THE ANATOMY OF THE HUMAN LUNG. The Prize Essay
to which the Fothergillian Gold Medal was awarded by the Medical Society of London.
Post 8vo. cloth, 6s. 6d.II.
RESEARCHES ON THE NATURE, PATHOLOGY, AND
TREATMENT OF EMPHYSEMA OF THE LUNGS, AND ITS RELATIONS
WITH OTHER DISEASES OF THE CHEST. With Engravings. 8vo.
cloth, 5s.

DR. ALLAN WEBB, F.R.C.S.L.

THE SURGEON'S READY RULES FOR OPERATIONS IN
SURGERY. Royal 8vo. cloth, 10s. 6d.

DR. WEBER.

A CLINICAL HAND-BOOK OF AUSCULTATION AND PER-
CUSSION. Translated by JOHN COCKLE, M.D. 5s.

MR. SOELBERG WELLS, M.D., M.R.C.S.

ON LONG, SHORT, AND WEAK SIGHT, and their Treatment by the Scientific Use of Spectacles. Second Edition. With Plates. 8vo. cloth, 6s.

MR. T. SPENCER WELLS, F.R.C.S.

I.
DISEASES OF THE OVARIES: THEIR DIAGNOSIS AND TREATMENT. Vol. I. 8vo. cloth, 9s.

II.
SCALE OF MEDICINES WITH WHICH MERCHANT VESSELS ARE TO BE FURNISHED, by command of the Privy Council for Trade; With Observations on the Means of Preserving the Health of Seamen, &c. &c. Seventh Thousand. Fcap. 8vo. cloth, 3s. 6d.

DR. WEST.

LECTURES ON THE DISEASES OF WOMEN. Third Edition. 8vo. cloth, 16s.

DR. UVEDALE WEST.

ILLUSTRATIONS OF PUERPERAL DISEASES. Second Edition, enlarged. Post 8vo. cloth, 5s.

MR. WHEELER.

HAND-BOOK OF ANATOMY FOR STUDENTS OF THE FINE ARTS. With Engravings on Wood. Fcap. 8vo., 2s. 6d.

DR. WHITEHEAD, F.R.C.S.

ON THE TRANSMISSION FROM PARENT TO OFFSPRING OF SOME FORMS OF DISEASE, AND OF MORBID TAINTS AND TENDENCIES. Second Edition. 8vo. cloth, 10s. 6d.

DR. WILLIAMS, F.R.S.

PRINCIPLES OF MEDICINE: An Elementary View of the Causes, Nature, Treatment, Diagnosis, and Prognosis, of Disease. With brief Remarks on Hygienics, or the Preservation of Health. The Third Edition. 8vo. cloth, 15s.

THE WIFE'S DOMAIN: the YOUNG COUPLE—the MOTHER—the NURSE—the NURSING. Post 8vo. cloth, 3s. 6d.

DR. J. HUME WILLIAMS.

UN SOUNDNESS OF MIND, IN ITS MEDICAL AND LEGAL CONSIDERATIONS. 8vo. cloth, 7s. 6d.

DR. WILLIAMSON, SURGEON-MAJOR, 64TH REGIMENT.

I.
MILITARY SURGERY. With Plates. 8vo. cloth, 12s.

II.
NOTES ON THE WOUNDED FROM THE MUTINY IN INDIA: with a Description of the Preparations of Gunshot Injuries contained in the Museum at Fort Pitt. With Lithographic Plates. 8vo. cloth, 12s.

MR. ERASMUS WILSON, F.R.S.

I.
THE ANATOMIST'S VADE-MECUM: A SYSTEM OF HUMAN ANATOMY. With numerous Illustrations on Wood. Eighth Edition. Foolscep 8vo. cloth, 12s. 6d.

II.
DISEASES OF THE SKIN: A Practical and Theoretical Treatise on the DIAGNOSIS, PATHOLOGY, and TREATMENT OF CUTANEOUS DISEASES. Fifth Edition. 8vo. cloth, 16s.

THE SAME WORK; illustrated with finely executed Engravings on Steel, accurately coloured. 8vo. cloth, 34s.

III.
HEALTHY SKIN: A Treatise on the Management of the Skin and Hair in relation to Health. Seventh Edition. Foolscep 8vo. 2s. 6d.

IV.
PORTRAITS OF DISEASES OF THE SKIN. Folio. Fasciculi I. to XII., completing the Work. 20s. each. The Entire Work, half morocco, £13.

V.
THE STUDENT'S BOOK OF CUTANEOUS MEDICINE AND DISEASES OF THE SKIN. Post 8vo. cloth, 8s. 6d.

VI.
ON SYPHILIS, CONSTITUTIONAL AND HEREDITARY; AND ON SYPHILITIC ERUPTIONS. With Four Coloured Plates. 8vo. cloth, 16s.

VII.
A THREE WEEKS' SCAMPER THROUGH THE SPAS OF GERMANY AND BELGIUM, with an Appendix on the Nature and Uses of Mineral Waters. Post 8vo. cloth, 6s. 6d.

VIII.
THE EASTERN OR TURKISH BATH: its History, Revival in Britain, and Application to the Purposes of Health. Foolscep 8vo., 2s.

DR. G. C. WITTSTEIN.

PRACTICAL PHARMACEUTICAL CHEMISTRY: An Explanation of Chemical and Pharmaceutical Processes, with the Methods of Testing the Purity of the Preparations, deduced from Original Experiments. Translated from the Second German Edition, by STEPHEN DARBY. 18mo. cloth, 6s.

DR. HENRY G. WRIGHT.

HEADACHES; their Causes and their Cure. Fourth Edition. Fcap. 8vo. 2s. 6d.

DR. YEARSLEY, M.D., M.R.C.S.

I.
DEAFNESS PRACTICALLY ILLUSTRATED; being an Exposition as to the Causes and Treatment of Diseases of the Ear. Sixth Edition. 8vo. cloth, 6s.

II.
ON THE ENLARGED TONSIL AND ELONGATED UVULA, and other Morbid Conditions of the Throat. Seventh Edition. 8vo. cloth, 5s.

CHURCHILL'S SERIES OF MANUALS.

Fcap. 8vo. cloth, 12s. 6d. each.

"We here give Mr. Churchill public thanks for the positive benefit conferred on the Medical Profession, by the series of beautiful and cheap Manuals which bear his imprint."—*British and Foreign Medical Review.*

AGGREGATE SALE, 141,000 COPIES.

- ANATOMY.** With numerous Engravings. Eighth Edition. By ERASMUS WILSON, F.R.C.S., F.R.S.
- BOTANY.** With numerous Engravings. By ROBERT BENTLEY, F.L.S., Professor of Botany, King's College, and to the Pharmaceutical Society.
- CHEMISTRY.** With numerous Engravings. Ninth Edition. By GEORGE FOWNES, F.R.S., H. BENICE JONES, M.D., F.R.S., and A. W. HOFMANN, F.R.S.
- DENTAL SURGERY.** With numerous Engravings. By JOHN TOMES, F.R.S.
- MATERIA MEDICA.** With numerous Engravings. Fourth Edition. By J. FORBES ROYLE, M.D., F.R.S., and FREDERICK W. HEADLAND, M.D., F.L.S.
- MEDICAL JURISPRUDENCE.** With numerous Engravings. Eighth Edition. By ALFRED SWAINE TAYLOR, M.D., F.R.S.
- PRACTICE OF MEDICINE.** Second Edition. By G. HILARO BARLOW, M.D., M.A.
- The MICROSCOPE and its REVELATIONS.** With numerous Plates and Engravings. Third Edition. By W. B. CARPENTER, M.D., F.R.S.
- NATURAL PHILOSOPHY.** With numerous Engravings. Fifth Edition. By GOLDING BIRD, M.D., M.A., F.R.S., and CHARLES BROOKE, M.B., M.A., F.R.S.
- OBSTETRICS.** With numerous Engravings. By W. TYLER SMITH, M.D., F.R.C.P.
- OPHTHALMIC MEDICINE and SURGERY.** With coloured Plates and Engravings on Wood. Third Edition. By T. WHARTON JONES, F.R.C.S., F.R.S.
- PATHOLOGICAL ANATOMY.** With numerous Engravings. By C. HANDFIELD JONES, M.B., F.R.C.P., and E. H. SIEVEKING, M.D., F.R.C.P.
- PHYSIOLOGY.** With numerous Engravings. Fourth Edition. By WILLIAM B. CARPENTER, M.D., F.R.S.
- POISONS.** Second Edition. By ALFRED SWAINE TAYLOR, M.D., F.R.S.
- PRACTICAL ANATOMY.** With numerous Engravings. (10s. 6d.) By CHRISTOPHER HEATH, F.R.C.S.
- PRACTICAL SURGERY.** With numerous Engravings. Fourth Edition. By Sir WILLIAM FERGUSSON, Bart., F.R.C.S.
- THERAPEUTICS.** Second Edition. By E. J. Waring, M.D., F.L.S.

